



Camille Q. Tolentino, MD  
Emmanuel Tadeus S. Cruz, MD

Department of Otolaryngology  
Head and Neck Surgery  
Manila Central University – Filemon D. Tanchoco  
Medical Foundation Hospital

## Bilateral Facial Nerve (Bell's) Palsy in a 24-Year-Old Woman: A Case Report

### ABSTRACT

**Objective:** To report a case of acute bilateral facial nerve palsy in a 24-year-old woman and to present the differential diagnoses, pathophysiology, management and prognosis.

**Methods:**

**Design:** Case study  
**Setting:** Tertiary Private Hospital  
**Patient:** One (1)

**Result:** A 24-year-old woman with fever, joint pains, cough, chest pain, difficulty ambulating and progressive facial muscle weakness was diagnosed with rheumatic fever. Bilateral facial nerve paralysis was noted, and Electromyography-Nerve Conduction Velocity (EMG-NCV) testing with special facial nerve study revealed abnormal facial nerve and blink reflex studies while EMG-NCV of the upper and lower limbs were normal. Audiometry and MRI of the brain and facial nerve were normal while Schirmer's Test showed decreased tearing in both eyes. The rheumatic fever resolved within 5 days of antibiotics, while Prednisone and physiotherapy resulted in improvement of facial paralysis from House Brackmann V to House Brackmann II-III over a period of 6 months.

**Conclusion:** Idiopathic facial paralysis or Bell's Palsy is the most common cause of acute unilateral facial paralysis while bilateral facial nerve paralysis is a rare condition. Patients with facial palsy should undergo appropriate diagnostics to determine the underlying condition and to facilitate prompt management.

**Keywords:** *facial paralysis, idiopathic, Bell's palsy*

**Facial paralysis** is not often encountered in our outpatient clinic. Individuals who develop facial palsy consult because of the unusual facial asymmetry and inability to move facial muscles. Often regarded as an ominous sign in clinical practice, paralysis of the lower half of the face may indicate central problem (such as a brain tumor, cerebrovascular accident or stroke).<sup>1</sup> Unilateral hemifacial paralysis may be due to peripheral compression of the tympanic segment of the facial nerve in cases of chronic mastoiditis and presence of cholesteatoma.<sup>2</sup> In addition, unilateral facial palsy may be iatrogenic (after mastoidectomy or parotidectomy) or in the absence of an etiology, termed Bell's palsy.<sup>3</sup>

Correspondence: Dr. Emmanuel Tadeus S. Cruz  
Department of Otolaryngology – Head and Neck Surgery  
MCU FDTMF Hospital  
EDSA, Caloocan City 1400  
Phone: (632) 8367 2031 local 1212 OPD 1144  
Fax: (632) 8367 2249  
Email: orlhns\_mcu@yahoo.com

The authors declared that this represents original material that is not being considered for publication or has not been published or accepted for publication elsewhere, in full or in part, in print or electronic media; that the manuscript has been read and approved by the authors, that the requirements for authorship have been met by the authors, and that the authors believe that the manuscript represent honest work.

Disclosures: The authors signed a disclosure that there are no financial or other (including personal) relationships, intellectual passion, political views or beliefs, and institutional affiliations that might lead to conflict of interest.

Presented at the Philippine Society of Otolaryngology Head and Neck Surgery Interesting Case Contest (3rd Place). April 8, 2017. Plaza del Norte Hotel & Convention Center, Ilocos Norte.



Creative Commons (CC BY-NC-ND 4.0)  
Attribution - NonCommercial - NoDerivatives 4.0 International

Philipp J Otolaryngol Head Neck Surg 2020; 35 (1): 60-62

© Philippine Society of Otolaryngology – Head and Neck Surgery, Inc.

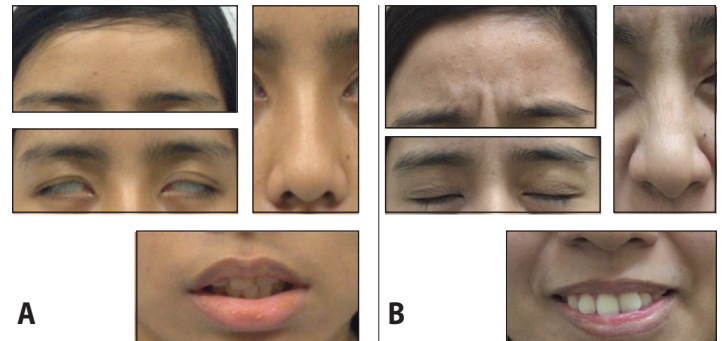
Idiopathic facial paralysis or Bell's palsy often involves only one side of the face and very seldom manifests bilaterally.<sup>1</sup> This report aims to present a case of acute bilateral facial nerve palsy, its differential diagnoses, pathophysiology, management and prognosis.

### CASE REPORT

A 24-year-old woman consulted due to high grade fever, progressive joint pains, nonproductive cough, sore throat and rashes for 2 weeks. She had taken oral antibiotics and antiseptic gargles but developed chest pain, stiff neck and shoulders, difficulty ambulating and facial muscle weakness after 4 days. She would drool and had to manually support her lower lip to avoid spilling liquids whenever she drank. The patient was admitted and elevated ASO titers and acute phase reactants satisfied the Jones criteria for diagnosis of rheumatic fever. Her past medical and social and personal history were non-contributory. The progression of facial muscle weakness prompted referral to ENT and Neurology.

The general physical examination was unremarkable, as was examination of the ears, nose, oral cavity and oropharynx. She had bilateral facial nerve paralysis, House-Brackmann V (incomplete eye closure, could not raise eyebrows, wrinkle nose, puff cheeks, or smile and frown). Electromyography-nerve conduction velocity (EMG-NCV) with facial nerve study revealed abnormal facial nerve and blink reflex consistent with acute bilateral facial mononeuropathy (Bell's Palsy) while EMG-NCV of the upper and lower limbs was normal with no evidence of focal or diffuse distal neuropathy. Pure tone audiometry, tympanometry and magnetic resonance imaging (MRI) of the brain and facial nerve were normal while Schirmer's Test showed decreased tearing bilaterally.

The patient was started on Prednisone 60mg/day for 6 days to taper down over a month, Ceftriaxone 2g/IV once daily for 3 days, shifted to Cefuroxime 500mg tab twice daily for 1 week and Aspirin 80 mg tab 1 tab every 8 hours. The fever, cough, rashes and joint and body pains resolved on the 5<sup>th</sup> hospital day. There was no further progression of facial paralysis, but she had no forehead motion, incomplete eye closure and only slight movement of the mouth. Physical therapy and management of dry eyes were started, and she was discharged on the 9<sup>th</sup> hospital day with a final diagnosis of bilateral Bell's palsy and Rheumatic fever, resolved. The patient continued home physiotherapy exercises once daily for the face and Prednisone was tapered down to complete one month. She was seen at the outpatient department (OPD) every month with marked improvement of facial paralysis from House Brackmann V to House Brackmann II-III observed over a span of 6 months. (Figure 1 A, B)



**Figure 1A & B.** Photos of forehead, eyelids, nose and mouth showing **A.** House-Brackmann V (no forehead motion, incomplete eye closure, slight mouth motion) before; and **B.** House-Brackmann II (moderate to good forehead motion, complete eye closure with minimum effort, slightly asymmetric mouth motion) 6 months after treatment. (Photos published without eye bars, with permission)

### DISCUSSION

Bell's palsy is a condition where the facial muscles are weakened or paralyzed, possibly due to trauma to the 7<sup>th</sup> cranial nerve, and is usually not permanent. The condition is named after Sir Charles Bell, a Scottish surgeon who studied the nerve and innervation of the facial muscles two centuries ago.<sup>2</sup>

Also known as idiopathic facial paralysis, Bell's palsy is the most common cause of acute unilateral facial paralysis accounting for 70% of cases.<sup>3</sup> Annual estimated incidence ranges from 15 to 40 per 100,000.<sup>3</sup> Bilateral facial nerve paralysis, on the other hand, is a rare condition with less than 0.3% - 2% of facial palsy cases, with an incidence of 1 per 5,000,000 population.<sup>4</sup>

The clinical history and manifestations may include waking up with sudden facial palsy, or symptoms such as dry eyes, or a tingling sensation around the lips prior to paralysis.<sup>5</sup> The degree of paralysis usually peaks within several days but not longer than 2-3 weeks, and a prodrome may be apparent such as neck pain, or pain behind the ear prior to palsy.<sup>5</sup>

Our patient developed flu like symptoms such as fever and joint pain before developing weakness and subsequent immobility of the facial muscles (although these symptoms are attributable to rheumatic fever). The bilateral facial palsy was so incapacitating that she could not move her lips and there was a need to support her lower lip to avoid spillage of liquids when drinking.

Since the facial nerve is lodged within a bony hard and unyielding cavity, it may be at risk for inflammation, infection, vascular or mechanical compromise.<sup>6</sup> Such a first-degree block of the facial nerve trunk is a temporary conductive block but axonal continuity is preserved, and the facial muscles cannot be moved voluntarily but a facial twitch can be elicited by transcutaneous electrical stimulation of the nerve distal to the lesion.<sup>7</sup>

Bell's palsy is a clinical manifestation of a wide array of systemic medical conditions from infectious, neurologic, traumatic and neoplastic disorders. Teller and Murphy list the differential diagnosis of acquired bilateral peripheral facial palsy which includes: trauma (e.g. skull fractures, parotid and mastoid surgery), infection (e.g. infectious mononucleosis, HIV infection, Lyme disease, Guillain-Barre syndrome, syphilis), metabolic disorders (e.g. diabetes), neoplastic (e.g. leukemia), autoimmune (e.g. sarcoidosis), neurological (e.g. multiple sclerosis, Parkinson's disease) and idiopathic (Bell's palsy).<sup>4</sup> Lyme disease was responsible for 36% of the cases for facial diplegia. Guillain-Barre syndrome (5%), trauma (4%), sarcoidosis (0.9%) and AIDS (0.9%).<sup>8</sup> Differential diagnosis in this particular case of bilateral Bell's palsy may include Guillain Barre syndrome, Rheumatic Fever and Influenza.

To evaluate the integrity of the facial nerve, ancillary procedures may include the Schirmer's test. Fisch pointed out that tearing often is reduced bilaterally in Bell's palsy, perhaps because of subclinical involvement of other cranial nerves. Thus, both the symmetry of the response and its absolute magnitude are important; a total response (sum of the lengths of wetted filter paper for both eyes) of less than 25m is considered abnormal.<sup>9</sup>

The role of electromyography (EMG-in the early phase of Bell's palsy is limited, because it does not permit a quantitative estimate of the extent of nerve degeneration.<sup>10</sup> However, EMG may be helpful as a confirmatory test for nerve decompression for Bell's palsy. If EMG shows voluntarily active facial motor units despite loss of excitability of the nerve trunk, the prognosis for a good spontaneous recovery is excellent.<sup>10</sup> Blink reflex allows the integrity of the facial nerve to be monitored by stimulation of the supraorbital branch of the trigeminal nerve which elicits a reflex contraction (blink) of the orbicularis oculi muscle.<sup>7</sup>

EMG-NCV with Special Facial Nerve Study done on the patient revealed abnormal facial nerve and blink reflex studies that showed evidence for an acute bilateral facial mononeuropathy (Bell's palsy) while EMG-NCV study of the upper and lower limbs was normal with no evidence of focal nor diffuse distal neuropathy. Acute bilateral facial neuropathy on EMG-NCV showed that the patient's facial nerve was affected and not fully functional. This is crucial because without this supporting evidence, the patient's apathetic facie might be misconstrued as a form of malingering. An unremarkable MRI study ruled out the possibility of tumor in the cerebellopontine angle and temporal bone that usually presents with unilateral hearing loss which when large enough may compress the facial nerve within the internal auditory meatus.

The management of facial palsy includes physical therapy, corticosteroids and antiviral drugs. Other modalities include biofeedback, laser, electrotherapy, massage and thermotherapy which are used to hasten recovery.<sup>11</sup> The rationale for the use of corticosteroids

in the acute phase of Bell's palsy is to reduce inflammation and edema of the facial nerve.<sup>10</sup> The use of antiviral agents alongside prednisone remains controversial. A study by Sullivan concluded that there was a significant improvement in trials that contained prednisolone, but no additional benefit was found from antiviral treatment.<sup>12</sup> This is one reason why anti-viral agents are not routinely used in Bell's palsy in our ENT service.

About 71% of patients with Bell's palsy have recovery of motor function within 6 months without treatment. Poor prognostic factors include: old age, hypertension, diabetes mellitus, impairment of taste and complete facial weakness. About one-third of patients may have incomplete recovery and residual effect including post-paralytic hemifacial spasm, co-contracting muscles, synkinesis, sweating while eating or during physical exertion.<sup>13</sup> In our case, the facial palsy improved from HB VI to II after 6 months of therapy. Perhaps her young age and prompt intervention augured well for a relatively fair to good prognosis with continued therapy.

In conclusion, idiopathic facial paralysis or Bell's palsy is the most common cause of acute unilateral facial paralysis while bilateral facial nerve paralysis is a rare condition. Patients with facial palsy should undergo appropriate diagnostics to determine the underlying condition and to facilitate prompt management.

REFERENCES

- Rowlands S, Hooper R, Hughes R, Burney P. The epidemiology and treatment of Bell's palsy in the UK. *Eur J Neurol*. 2002 Jan; 9(1): 63-7. DOI: 10.1046/j.1468-1331.2002.00343.x PubMed PMID: 11784378.
- Adel B, Kawthar S, Amine D, Souha BY, Abdellatif B. Idiopathic Facial Paralysis (Bell's palsy). *Int J Dent. Sci Res*. 2014; 2(5A):1-4. DOI:10.12691/ijdsr-2-5A-1.
- Green JD Jr, Shelton C, Brackman DE. Iatrogenic facial nerve injury during otologic surgery. *Laryngoscope*. 1994 Aug; 104 (8 pt 1): 922-926. DOI: 10.1288/00005537-199408000-00002. PubMed PMID: 8052074.
- Teller DC, Murphy TP. Bilateral facial paralysis: a case presentation and literature review. *J Otolaryngol*. 1992 Feb; 21(1):44-7. PubMed PMID: 1564749.
- Pothiawala S, Lateef F. Bilateral facial nerve palsy: a diagnostic dilemma. *Case Rep Emerg Med*. 2012; 2012:458371. DOI: 10.1155/2012/458371. PubMed PMID: 23326715 PubMed Central PMCID: PMC3542940.
- Sutherland S. The anatomy and physiology of nerve injury. *Muscle Nerve*. 1990 Sep; 13(9): 771-84. DOI: 10.1002/mus.880130903. PubMed PMID: 2233864.
- Sunderland S. Some anatomical and pathophysiological data relevant to facial nerve injury and repair. In Fisch U, editor. *Facial Nerve Surgery*. Birmingham, AL: Aesculapius Publishing. 1977, pp. 47-61.
- Adour KK, Byl FM, Hilsinger RL Jr, Kahn ZM, Sheldon MI. The true nature of Bell's palsy: analysis of 1000 consecutive patients. *Laryngoscope* 1978 May;88(5):787-801. DOI:10.1002/lary.1978.88.5.787 PubMed PMID: 642672.
- Fisch U. Prognostic value of electrical tests in acute facial paralysis. *Am J Otol* 1984 Oct;5(6):494-8. PubMed PMID: 6393772.
- Grogan PM, Gronseth GS. Practice parameter: Steroids, acyclovir, and surgery for Bell's palsy (an evidence-based review): Report of the Quality Standards Subcommittee of the American Academy of Neurology. *Neurology*. 2001 Apr 10;56(7):830-6. DOI: 10.1212/wnl.56.7.830. PubMed PMID: 11294918.
- Greenberg MR, Urquhart MC, Eynor JK, Worriolow CC, Gesell NC, Porter BG, Miller AC. I can't Move My Face! A Case of Bilateral Facial Palsy. *J Am Osteopath Assoc*. 2013 Oct; 113(10):788-790. DOI: https://doi.org/10.7556/jaoa.2013.048.
- Sullivan FM, Swan IR, Donnan PT, Morrison JM, Smith BH, McKinstry B, et al. Early treatment with prednisolone or acyclovir in Bell's palsy. *N Engl J Med*. 2007 Oct 18;357(16):1598-607. DOI:10.1056/NEJMoa072006 PubMed PMID: 17942873.
- Carapetis JR, McDonald M, Wilson NJ. Acute rheumatic fever. *Lancet* 2005 Jul 9; 15;366(9480):155-68. DOI: 10.1016/S0140-6736(05)66874-2 PubMed PMID: 16005340.