



Maria Katerina A. Palacios, MD<sup>1</sup>  
Jay Pee M. Amable, MD<sup>1</sup>  
Kea T. Capio, MD<sup>2</sup>

<sup>1</sup>Department of Otorhinolaryngology  
Head and Neck Surgery  
University of the East - Ramon Magsaysay Memorial  
Medical Center

<sup>2</sup>Department of Radiology  
University of the East - Ramon Magsaysay Memorial  
Medical Center

Correspondence: Dr. Jay Pee M. Amable  
Department of Otorhinolaryngology  
Head and Neck Surgery  
5th floor, ENT Office, Hospital Service Bldg.,  
UERMMMC, Inc., 64 Aurora Blvd., Quezon City 1113  
Philippines  
Phone: (632) 8715 0861 local 257  
Fax: (632) 8716 1789  
Email: jpamablemd@gmail.com

The authors declared that this represents original material that is not being considered for publication or has not been published or accepted for publication elsewhere, in full or in part, in print or electronic media; that the manuscript has been read and approved by both authors, that the requirements for authorship have been met by each author, and that the authors believe that the manuscript represents honest work.

Disclosures: The authors signed disclosures that there are no financial or other (including personal) relationships, intellectual passion, political or religious beliefs, and institutional affiliations that might lead to a conflict of interest

Presented at the Philippine Society of Otolaryngology Head and Neck Surgery Descriptive Research Contest. November 8, 2021.



Creative Commons (CC BY-NC-ND 4.0)  
Attribution - NonCommercial - NoDerivatives 4.0 International

## Radiologic Evaluation of the Anterior and Posterior Ethmoidal Foramen and Optic Canal by Paranasal Sinus Computed Tomography Scan among Adult Filipinos

### ABSTRACT

**Objective:** To measure the average distances from anterior lacrimal crest (ALC) to anterior ethmoidal foramen (AEF), anterior ethmoidal foramen to posterior ethmoidal foramen (PEF) and posterior ethmoidal foramen to optic canal (OC) using plain paranasal sinus (PNS) computed tomography (CT) scans of adults in a tertiary private hospital in the Philippines.

### Methods:

**Design:** Retrospective review of plain PNS CT scans

**Setting:** Tertiary Private Teaching Hospital

**Participants:** One hundred four (104) plain PNS CT scans from January 2018 to December 2020 were considered for inclusion.

**Results:** Of the 104 PNS CT scans, 35 were excluded - seven for age less than eighteen, six for undistinguishable PEF and twenty-two for chronic rhinosinusitis. The remaining 69 PNS CT scans demonstrated identifiable structures, with overall average distances from ALC to AEF of  $23.71 \pm 2.43$  mm, AEF to PEF of  $10.87 \pm 2.39$  mm and PEF to OC of  $7.39 \pm 2.28$  mm.

**Conclusion:** Our study suggests average distances for localization of vital structures such as the anterior ethmoidal artery, posterior ethmoidal artery and optic nerve among Filipinos. Because of considerable variation between and within sexes, individual measurements should still be obtained for each patient in performing endonasal, skull base and orbital surgery.

**Keywords:** *Skull base; orbital surgery; paranasal sinus; optic nerve; anterior ethmoidal artery; posterior ethmoidal artery; anterior lacrimal crest*

**The anterior ethmoid artery (AEA)** and the posterior ethmoid artery (PEA) are major vessels supplying the ethmoid sinus, nasal septum and anterior skull base. Control of these vessels is a key step in performing extended sinus, skull base and orbital procedures. Iatrogenic damage to these vessels due to their critical location which traverse the orbit and roof of ethmoid sinus, is potentially dangerous during endoscopic sinus, anterior skull base and orbital surgery. Retraction of the AEA into the orbit can lead to permanent vision loss if not managed appropriately.<sup>1</sup> There is also an increased risk of optic nerve injury during coagulation of the posterior ethmoidal artery.<sup>2</sup>

Thus, the approximate localization of these vital structures should be known pre-operatively to anticipate and prevent complications in performing endonasal, skull base and orbital surgeries. After an exhaustive search in MEDLINE (PubMed), HERDIN Plus and Google Scholar, we found no studies on the location, course and relationship of these structures among adult Filipinos.

This study aims to determine the average distances of the anterior ethmoidal foramen (AEF) from the anterior lacrimal crest (ALC), AEF to posterior ethmoidal foramen (PEF) and PEF to optic canal (OC) on plain paranasal sinus computed tomography (PNS CT) scans of adults in a tertiary private hospital in the Philippines.

### METHODS

With approval of the University of the East - Ramon Magsaysay Memorial Medical Center (UERMMMCI) Research Institute for Health Sciences Ethics Review Committee (RIHS ERC Code: 1121/H/2021/201), this retrospective review analyzed PNS CT scans obtained at our tertiary private hospital from January 2018 to December 2020.

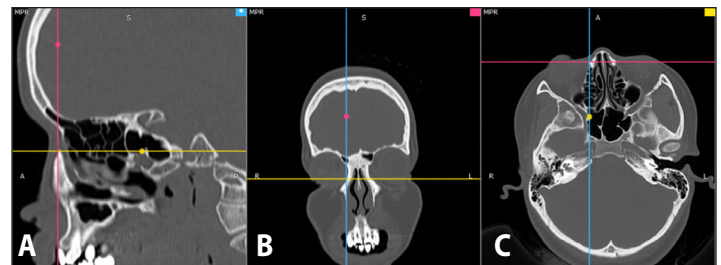
All plain PNS CT scans performed in UERMMMCI for various indications during the study period were retrieved chronologically and reviewed by the authors, two otolaryngologists and one radiologist. The inclusion criteria for all plain PNS CT scans to be reviewed were those of male and female patients aged 18 years or older. Excluded were scans of patients who underwent previous endonasal surgery prior to performing the imaging study, those with extensive sinonasal tumors which had invaded the orbital apex, dura, brain, middle cranial fossa, nasopharynx and clivus, those of patients with craniofacial injuries and anomalies or with chronic rhinosinusitis, and CT scans with no demonstrable PEF.

All PNS CT scans were obtained using a Hitachi Multi-slice Supria 64 CT scanner (HTSI Healthcare Solutions, FL, USA) and evaluated using Radiant DICOM software for Windows 11/10/8.1/8/7 (<https://www.radiantviewer.com>). The software showed the three planes simultaneously (axial, coronal, and sagittal) in bone window and allowed taking measurements in the actual scale. The thickness of the cuts where the actual measurements were obtained was 0.625 mm. Localization of the structures were consensually arrived at by the authors using the 24-12-6mm landmark mentioned by Naidoo and Wormald.<sup>1</sup> The location of the ALC, AEF, PEF and OC were obtained in multiplanar cuts. Using the sagittal cuts of the plain PNS CT scan, the measurements of the distances of the following: ALC to AEF, AEF to PEF and PEF to OC and the averages were obtained.

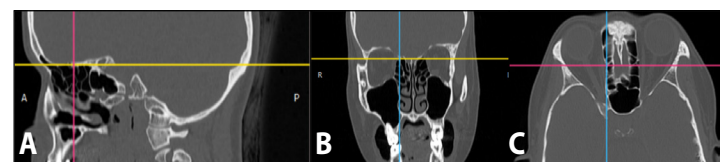
All data was recorded and tabulated using Microsoft Excel for Mac v. 16.52 (21080801) (Microsoft Corp., Redmond, WA, USA). The average means and standard deviations were computed by sex, and overall, using Microsoft Excel.

### RESULTS

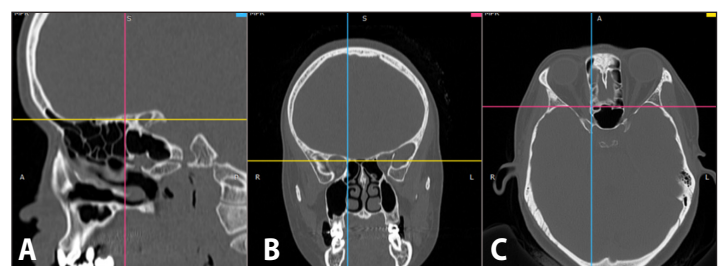
The sample for this study was obtained using the largest available number of plain PNS CT Scans done in UERMMMCI during the study period. A total of 104 plain PNS CT scans were reviewed with seven excluded for age less than 18, six excluded for undistinguishable posterior ethmoidal foramen and 22 excluded for chronic rhinosinusitis. None had previous endonasal surgery, extensive sinonasal tumors, craniofacial anomalies or facial fractures. Of the 69 finally included (66.34%) out of 104 PNS CT scans, 39 were of male patients and 30 were of females, and all demonstrated identifiable and complete structures. *Figures 1 to 4* show representative PNS CT scan localizations of the ALC, AEF, PEF and OC respectively, and *Figure 5* shows a representative scan of how the distances were measured. We obtained the following average distances for ALC to AEF:  $23.87 \pm 2.56$  mm (Males),  $23.67 \pm 2.27$  mm (Females); AEF to PEF:  $11.08 \pm 2.44$  mm (Males),  $10.54 \pm 2.28$  mm (Females); PEF to OC:  $7.79 \pm 2.40$  mm (Males),  $7.03 \pm 2.20$  mm (Females); with overall averages of:  $23.71 \pm 2.43$  mm for ALC to AEF,  $10.87 \pm 2.39$  mm for AEF to PEF and  $7.39 \pm 2.28$  mm for PEF to OC.



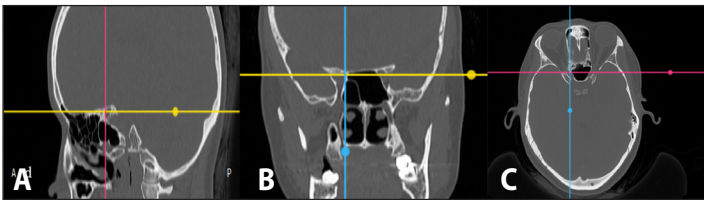
**Figure 1.** Representative PNS CT scan images (bone windows) demonstrating localization of the anterior lacrimal crest (ALC) at intersections of lines in multiplanar views: **A.** sagittal view; **B.** coronal view; and **C.** axial view.



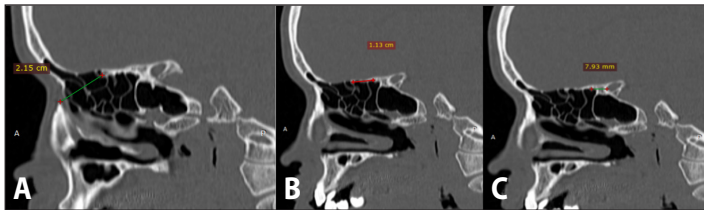
**Figure 2.** Representative PNS CT scan images (bone windows) demonstrating localization of the anterior ethmoidal foramen (AEF) at intersections of lines in multiplanar views: **A.** sagittal view; **B.** coronal view; and **C.** axial view.



**Figure 3.** Representative PNS CT scan images (bone windows) demonstrating localization of the posterior ethmoidal foramen (PEF) at intersections of lines in multiplanar views: **A.** sagittal view; **B.** coronal view; and **C.** axial view.



**Figure 4.** Representative PNS CT scan images (bone windows) demonstrating localization of the optic canal (OC) at intersections of lines in multiplanar views: **A.** sagittal view; **B.** coronal view; and **C.** axial view.



**Figure 5.** Representative PNS CT scan sagittal sections (bone windows) demonstrating measurement of the distances (lines between dots) from: **A.** ALC to AEF; **B.** AEF to PEF; and **C.** PEF to OC.

### DISCUSSION

Computed tomography has been used in few studies on the distances of ethmoidal foramen and the optic canal.<sup>3</sup> Traditionally, surgeons have used the “24-12-6mm rule” measuring from the ALC-AEF, AEF – PEF and PEF-OC to navigate critical medial orbital wall structures.<sup>4</sup> In contrast our study suggests overall average distances from ALC to AEF of  $23.71 \pm 2.43$  mm, AEF to PEF of  $10.87 \pm 2.39$  mm and PEF to OC of  $7.39 \pm 2.28$  mm.

We compared our findings with previous studies on radiologic evaluation of anterior and posterior ethmoidal foramen and optic canal using plain PNS CT scans. The study of Nitek *et al.* on morphometry of the orbit in an east European population based on three-dimensional CT reconstruction measured the minimal safe distances of 50 Caucasian patients from ALC-AEF, AEF-PEF, and PEF-OC at  $27.7 \pm 2.8$  mm,  $10.6 \pm 3.3$  mm, and  $5.4 \pm 1$  mm, respectively which as compared to our study has a 4 mm difference for ALC-AEF, 0.27 mm difference for AEF-PEF and 1.99 mm difference for PEF-OC.<sup>5</sup> Cankal *et al.* obtained average distances of 13.7 mm and 8.5 mm for the AEC-PEC and PEC-OC respectively in their study of 150 PNS CT scans in Turkey which also differs from our study from which there is a 2.83 mm difference for AEF-PEF and 1.11 mm difference for PEF-OC.<sup>6</sup> Cánovas *et al.* measured  $11.24 \pm 2.14$  mm for the AEF-PEF and  $7.26 \pm 1.33$  mm for the PEF-OC in their study of 20 CT scans of cadaver heads in Spain which also did not match our study with a 0.37 mm difference for AEF-PEF and 0.13 mm difference for PEF-OC.<sup>7</sup>

Preoperative computed tomography imaging has become a mainstay in surgical planning prior to endonasal, skull base and orbital surgery and affords the opportunity to identify anatomic variants that predispose patients to surgical complications.<sup>8</sup> Inadequate pre-operative analysis of PNS CT scans by the surgeon may lead to accidental damage to crucial structures such as the AEA, PEA and

optic nerve, hence our goal was to measure the average distances from anterior lacrimal crest (ALC) to anterior ethmoidal foramen (AEF), anterior ethmoidal foramen to posterior ethmoidal foramen (PEF) and posterior ethmoidal foramen to optic canal (OC) using plain paranasal sinus (PNS) computed tomography (CT) scans that are consistent with adult Filipino patients.

However, simple this study may seem, it is not without limitations. There were no associations made with pathologic findings. Selection bias was present, because all of our plain PNS CT scans were obtained from patients with non-excluded indications for the scans and may not represent the larger normal population to which our results can be applied. Further radiologic studies may be done to increase the sample size and facilitate the data collection process. Correlations with pathologic findings on PNS CT scans may also be explored. Our study also focused only on adults and further studies can be performed in pediatric age groups. Despite these limitations, our study may help provide data for further analysis by future investigators.

In conclusion, our study suggests average distances for localization of vital structures such as the anterior ethmoidal artery, posterior ethmoidal artery and optic nerve among Filipinos. Because of considerable variation between and within sexes, individual measurements should still be obtained for each patient in performing endonasal, skull base and orbital surgery.

### ACKNOWLEDGEMENTS

We would like to acknowledge the invaluable insights of Dr. Ardie Frencher V. Dizon, Dr. Jan Paul D. Formalejo and Dr. Cathrine P. Miura in the technical writing of this paper.

### REFERENCES

- Naidoo Y, Wormwald PJ. Chapter 4. Endoscopic and open anterior/posterior artery ligation. In: Chiu AG, Palmer JN, Adappa ND (editors). Atlas of endoscopic sinus and skull base surgery. 2<sup>nd</sup> ed. Elsevier. 2018, pp. 25–32.
- Yamamoto H, Nomura K, Hidaka H, Katori Y, Yoshida N. Anatomy of the posterior and middle ethmoidal arteries via computed tomography. *SAGE Open Med.* 2018 Apr 27; 6: 2050312118772473. DOI: 10.1177/2050312118772473; PubMed PMID: 29760919; PubMed Central PMCID: PMC5946601.
- Felding UA, Karnov K, Clemmensen A, Thomsen C, Darvann TA, Buchwald C, et al. An applied anatomical study of the Ethmoidal Arteries: Computed Tomographic and direct measurements in human cadavers. *J Craniofac Surg.* 2018 Jan;29(1):212–216. DOI: 10.1097/scs.00000000000004157; PubMed PMID: 29287000.
- Piagkou M, Skotsimara G, Dalaka A, Kanioura E, Korentzelou V, Skotsimara A, et al. Bony landmarks of the medial orbital wall: An anatomical study of ethmoidal foramina. *Clinical Anatomy.* 2014 May; 27(4): 570–577. DOI: 10.1002/ca.22303.
- Nitek S, Bakoń L, Sharifi M, Rysz M, Chmielik LP, Sadowska-Krawcenko I. Morphometry of the orbit in east-European population based on three-dimensional CT reconstruction. *Advances in Anatomy.* 2015 Oct; 101438:1–10. DOI: 10.1155/2015/101438.
- Cankal F, Apaydin N, Acar H, Elhan A, Tekdemir I, Yurdakul M. et al. Evaluation of the anterior and posterior ethmoidal canal by computed tomography. *Clin Radiol.* 2004 Nov;59(11):1034-1040. DOI: 10.1016/j.crad.2004.04.016; PubMed PMID: 15488853.
- Monjas-Cánovas I, García-Garrigós E, Arenas-Jiménez JJ, Abarca-Olivas J, Sánchez-Del Campo F, Gras-Albert JR. Anatomía radiológica de las arterias etmoidales: Estudio Por TC en cadáver. *Acta Otorrinolaringol Esp.* 2011 Sep - Oct; 62(5):367–374. DOI: 10.1016/j.otorri.2011.04.006 PubMed PMID: 21683934.
- O'Brien WT, Hamelin S, Weitzel EK. The preoperative sinus CT: Avoiding a “CLOSE” call with surgical complications. *Radiology.* 2016 Oct; 281(1): 10–21. DOI: 10.1148/radiol.2016152230 PubMed PMID: 27643765.