



EDITORIAL

- 4 Truth and Transparency, Compromise and Climate Change
Lapeña JFF

GUEST EDITORIAL

- 6 COP27 Climate Change Conference: Urgent Action Needed for Africa and the World
Atwoli L, Erhabor GE, Gbakima AA, Haileamlak, A, Kayembe Ntumba JM, Kigera J, Laybourn-Langton L, Mash R, Muhia J, Mulaudzi FM, Ofori-Adjei D, Okonofua F, Rashidian A, El-Adawy M, Sidibé S, Snouber A, Tumwine J, Yassien MS, Yonga P, Zakhama L, Zielinski C

ORIGINAL ARTICLES

- 8 Hearing and Clinical Otologic Profile of Filipinos Living in Southern Tagalog Region IV-A (CALABARZON), Philippines: The Southern Tagalog ENT Hearing Specialists (STENTS) Survey 2012-2017
Pardo PJM, Niñal-Vilog A, Acuin JM, Calaquian CME, Onofre-Telan RDC
- 16 The Complete and Two-Turn Cochlear Duct Length Among Filipinos
Kasilag RMA, Aquino-Diaz K
- 20 Quality of Life Among SARS-CoV-2 (COVID-19) Positive Patients with Anosmia Using the Short Version Questionnaire of Olfactory Disorders - Negative Statements Translated in Filipino (sQOD-NS Ph)
Mallari-Bernarte A, Cruz ETS
- 26 Quality of Sleep Among Shift Work Nurses at the Baguio General Hospital: A Pilot Cross-Sectional Study
Andaya KES
- 30 Initial Outcomes of Endoscopic CO2 Laser Posterior Cordectomy and Partial Arytenoidectomy Among Patients with Bilateral Vocal Cord Paralysis: A Case Series
Velasco KJS, de la Cruz APC, Carrillo RJD, Madrid DAD
- 34 A New Extraoral Closed Reduction Technique for Temporomandibular Joint Dislocation: A Preliminary Case Series
Sangalang MB, Gansatao FM, Dizon APJE, Onofre-Telan RDC

CASE REPORTS

- 38 Airway Obstruction from Intralaryngeal Extension of Thyroglossal Duct Cyst in an Elderly Man: A Case Report
Contreras GS, Lingan MB
- 42 Multifocal Tuberculosis Presenting as Mandibular Swelling in a 3-Year-Old Boy: A Case Report
Yambot KKK, Peñaflor NAI

SURGICAL INNOVATIONS AND INSTRUMENTATION

- 46 A Makeshift Blue Light Filter for Endoscopic Identification of Traumatic Cerebrospinal Fluid Leak Using Fluorescein
Edora BDE, Chua RU, Estolano PJL

FEATURED GRAND ROUNDS

- 50 Hearing Loss from *S. Suis* Meningitis in a Middle-Aged Couple
Martinez NV, Hosujima MS

FROM THE VIEWBOX

- 53 Can I Diagnose a Vestibular Schwannoma Using Non-Contrast Imaging?
Yang NW

UNDER THE MICROSCOPE

- 55 Intercalated Duct Adenoma of the Parotid Gland
Aquino JB, Carnate JM

LETTERS TO THE EDITOR

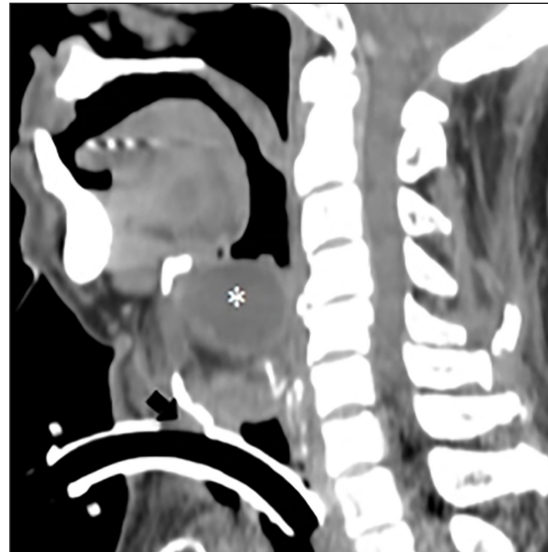
- 57 Otitic Hydrocephalus or Obstructive Hydrocephalus?
Yang NW

Response from the Authors

- Plumo CGT, Cruz ETS

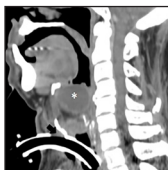
CAPTOONS

- 60 Doknet's World
Billones WU

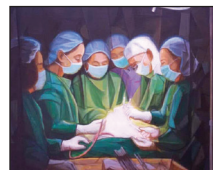

- Truth and Transparency, Compromise and Climate Change
- COP27 Climate Change Conference: Urgent Action Needed for Africa and the World
- Hearing and Clinical Otologic Profile of Filipinos Living in Southern Tagalog Region IV-A (CALABARZON), Philippines: The Southern Tagalog ENT Hearing Specialists (STENTS) Survey 2012-2017
- The Complete and Two-Turn Cochlear Duct Length Among Filipinos
- Quality of Life Among SARS-CoV-2 (COVID-19) Positive Patients with Anosmia Using the Short Version Questionnaire of Olfactory Disorders - Negative Statements Translated in Filipino (sQOD-NS Ph)
- Quality of Sleep Among Shift Work Nurses at the Baguio General Hospital: A Pilot Cross-Sectional Study
- Initial Outcomes of Endoscopic CO2 Laser Posterior Cordectomy and Partial Arytenoidectomy Among Patients with Bilateral Vocal Cord Paralysis: A Case Series
- A New Extraoral Closed Reduction Technique for Temporomandibular Joint Dislocation: A Preliminary Case Series
- Airway Obstruction from Intralaryngeal Extension of Thyroglossal Duct Cyst in an Elderly Man: A Case Report
- Multifocal Tuberculosis Presenting as Mandibular Swelling in a 3-Year-Old Boy: A Case Report
- A Makeshift Blue Light Filter for Endoscopic Identification of Traumatic Cerebrospinal Fluid Leak Using Fluorescein
- Hearing Loss from *S. Suis* Meningitis in a Middle-Aged Couple
- Can I Diagnose a Vestibular Schwannoma Using Non-Contrast Imaging?
- Intercalated Duct Adenoma of the Parotid Gland
- Otitic Hydrocephalus or Obstructive Hydrocephalus?
- Response from the Authors
- DokNet's World

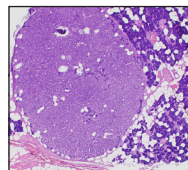
COVER IMAGES



Contrast CT scan (sagittal view) showing mass (asterisk), with peripheral rim enhancement and fenestra of tracheostomy tube outside the tracheal lumen (arrow).
By Gerson S. Contreras, MD




"Surhano in Cubism"
Acrylic on canvas
18"x24"
By Joseph Joel Cristobal



Histopathologic slide showing well-circumscribed, encapsulated proliferation of closely packed tubular ducts adjacent to non-neoplastic lobules of parotid serous acini and fat cells (H&E, 40X).
By Jose M. Carnate, Jr., MD



"Bountiful Catch"
5D Mark 3 17-40mm L
ISO 100
By Rene Louie Gutierrez, MD



"Girl with Flowers in Her Hair"
10" x 14" Oil on Canvas
By Camille Espina, MD