



**EDITORIAL**

- 4 The Updated World Association of Medical Editors (WAME) Recommendations on Chatbots and Generative AI in Relation to Scholarly Publications and International Committee of Medical Journal Editors (ICMJE) Recommendations for the Conduct, Reporting, Editing, and Publication of Scholarly Work in Medical Journals (May 2023)  
Lapeña JFF

**SPECIAL ANNOUNCEMENT**

- 7 Chatbots, Generative AI, and Scholarly Manuscripts WAME Recommendations on Chatbots and Generative Artificial Intelligence in Relation to Scholarly Publications  
Zielinski C, Winker MA, Aggarwal R, Ferris LE, Heinemann M, Lapeña JF, Pai SA, Ing E, Citrome L, Alam M, Voight M, Habibzadeh F. on behalf of the WAME Board

**REVIEW ARTICLE**

- 10 Association of Glycemic Index Using HbA1c and Sensorineural Hearing Loss in Diabetes Mellitus Type 2 Patients: A Systematic Review and Meta-Analysis  
Quines MRR, Gloria CEC

**ORIGINAL ARTICLES**

- 17 Evaluation of the Newborn Hearing Screening Program in the University of Santo Tomas Hospital Based on the Joint Committee on Infant Hearing 2019 Position Statement on Quality Indicators for Screening and Confirmation of Hearing Loss  
Crizaldo LPR, Ramos ABC
- 22 Sinonasal Anatomy Variations on CT Scans of a Sample of Filipino Adults With Chronic Rhinosinusitis  
Policina CP, Ambrocio GMC, Roldan RA, Grullo PER
- 28 High Risk Human Papilloma Virus (HPV) Oropharyngeal Squamous Cell Carcinoma in a Private Tertiary Care Setting in the Philippines: Prevalence, Clinical Characteristics and Testing  
Chang AMV, Santos MKD, Lim WL
- 35 Profile of Patients with Oral Cavity Cancer Seen at the Department of Ear Nose Throat – Head and Neck Surgery of the Bicol Medical Center  
Alvarez AD, Reyes MU
- 39 Outcomes of COVID-19 Positive and COVID-19 Negative Adult Patients Who Underwent Tracheostomy for Prolonged Intubation in a COVID-19 Referral Center During the Pandemic  
Yee EC, Dela Cruz APC, Cruz TLG, Villanueva CAG, Cruz EJM
- 45 Delay and Completion of Treatment in Head and Neck Cancer Patients Employing a Multidisciplinary Team Approach: A Single Institution Experience  
Manaig JMN, Fernando AF, Yu KKL

**CASE REPORTS**

- 50 Delayed-Onset Unilateral Facial Paralysis After Mastoidectomy: A Case Report  
Baloco EDQ, Orosa JB III
- 54 Combined Cartilage Graft Reconstruction of the Nasal Tip Complex after Resection of Nasal Tip Schwannoma: A Case Report  
Bacalla FJP, Laxamana JQ

**PRACTICE PEARLS**

- 58 Intradermal Hyaluronidase: The Answer to Treatment in Softening a Fibrous Thick Supratip Skin in Rhinoplasty?  
Yap EC, Porquez JM

**FEATURED GRAND ROUNDS**

- 61 Sinonasal Mucosal Melanoma: A Rare Intranasal Tumor in an 89-Year-Old Woman  
Esguerra JM, Ambrocio GMC, Castañeda SS

**FROM THE VIEWBOX**

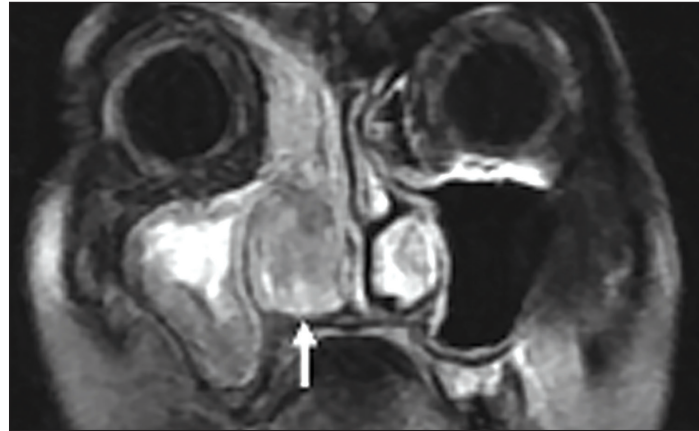
- 65 Fracture of the Petrous Carotid Canal  
Yang NW

**UNDER THE MICROSCOPE**

- 66 Follicular Thyroid Adenoma with Papillary Architecture  
Carnate JM

**CAPTIONS**

- 68 DokNet's World  
Billones WU



The Updated World Association of Medical Editors (WAME) Recommendations on Chatbots and Generative AI in Relation to Scholarly Publications and International Committee of Medical Journal Editors (ICMJE) Recommendations for the Conduct, Reporting, Editing, and Publication of Scholarly Work in Medical Journals (May 2023)

Chatbots, Generative AI, and Scholarly Manuscripts: WAME Recommendations on Chatbots and Generative Artificial Intelligence in Relation to Scholarly Publications Association of Glycemic Index Using HbA1c and Sensorineural Hearing Loss in Diabetes Mellitus Type 2 Patients: A Systematic Review and Meta-Analysis

Evaluation of the Newborn Hearing Screening Program in the University of Santo Tomas Hospital Based on the Joint Committee on Infant Hearing 2019 Position Statement on Quality Indicators for Screening and Confirmation of Hearing Loss

Sinonasal Anatomy Variations on CT Scans of a Sample of Filipino Adults With Chronic Rhinosinusitis

High Risk Human Papilloma Virus (HPV) Oropharyngeal Squamous Cell Carcinoma in a Private Tertiary Care Setting in the Philippines: Prevalence, Clinical Characteristics and Testing

Profile of Patients with Oral Cavity Cancer Seen at the Department of Ear Nose Throat – Head and Neck Surgery of the Bicol Medical Center

Outcomes of COVID-19 Positive and COVID-19 Negative Adult Patients Who Underwent Tracheostomy for Prolonged Intubation in a COVID-19 Referral Center During the Pandemic

Delay and Completion of Treatment in Head and Neck Cancer Patients Employing a Multidisciplinary Team Approach: A Single Institution Experience

Delayed-Onset Unilateral Facial Paralysis After Mastoidectomy: A Case Report

Combined Cartilage Graft Reconstruction of the Nasal Tip Complex after Resection of Nasal Tip Schwannoma: A Case Report

Intradermal Hyaluronidase: The Answer to Treatment in Softening a Fibrous Thick Supratip Skin in Rhinoplasty?

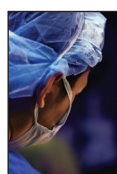Sinonasal Mucosal Melanoma: A Rare Intranasal Tumor in an 89-Year-Old Woman

Fracture of the Petrous Carotid Canal

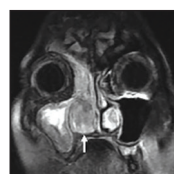Follicular Thyroid Adenoma with Papillary Architecture

DokNet's World

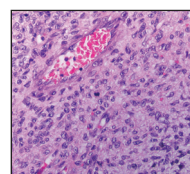
**COVER IMAGES**



"Covered"  
Canon EOS 5D Mark II  
By Rene Louie Gutierrez,  
MD, MHA



"Heterogeneously enhancing hyperintense nasal mass"  
Contrast MRI, coronal view  
By Jeremiah M. Esguerra, MD



"Mesenchymal component of ameloblastic fibrosarcoma"  
H&E slide, 400X  
By Jose M. Carnate, Jr., MD



"Screw 'Em Up"  
Canon EOS 5D Mark II  
By Rene Louie Gutierrez,  
MD, MHA



"MicroLaryngeal Surgery"  
Oil on Canvas - 20" x 25"  
By Mariano B. Caparas, MD