



**EDITORIAL**

- 4 On the Brink: The Climate and Nature Crisis and Risks of Nuclear War  
Lapeña JFF

**GUEST EDITORIALS**

- 6 Time to Treat the Climate and Nature Crisis as One Indivisible Global Health Emergency  
Abbasi K, Ali P, Barbour V, Benfield T, Bibbins-Domingo K, Hancock S, Horton R, Laybourn-Langton L, Mash R, Sahni P, Mohammad Sharief W, Shehab A, Yonga P, Zielinski C
- 9 Reducing the Risks of Nuclear War – The Role of Health Professionals  
Abbasi K, Ali P, Barbour V, Bibbins-Domingo K, Olde Rikkert MGM, Haines A, Helfand I, Horton R, Mash R, Mitra A, Monteiro C, Naumova EN, Rubin EJ, Ruff T, Sahni P, Tumwine J, Yonga P, Zielinski C

**ORIGINAL ARTICLES**

- 11 Diagnosis and Management of Otosclerosis in a Filipino Population: A Case Series  
Yang NW
- 17 Radiographic Measurement of Nasopharyngeal Depth from the Anterior Nasal Spine (ND-ANS) Among Filipino Adults  
Lopa RAB, Ilustre GMS, Hernandez JG
- 22 Factors Predisposing to Post Thyroidectomy Vocal Cord Paralysis at Ospital ng Maynila Medical Center  
Carlos EJC, Agullo EJA
- 26 Association of Clinicodemographic Factors and Tissue Biopsy Results Among Patients with Thyroid Nodules at the Southern Philippines Medical Center  
Aujero ML, Tagasa JMP, Llamera GLQ
- 31 Relationship of Post-Thyroidectomy Hypocalcemia to Surgeon's Experience in a Private Tertiary Hospital  
Ramos NP
- 35 Surgical Management of Goiter with Intrathoracic Extension at the Philippine General Hospital Department of Otolaryngology – Head and Neck Surgery  
Mendoza KML, Madrid DAD
- 42 Stratifying Indeterminate Cytology Thyroid Nodules by Combining Thyroid Imaging Reporting and Data Systems (TI-RADS) and The Bethesda System for Reporting Thyroid Cytopathology (TBSRTC)  
Cambe SMM, Arañas JAM, Manzana JLP, Manlapaz KTG

**SURGICAL INNOVATIONS AND INSTRUMENTATION**

- 48 An Alternative Surgical Approach to Cemento-Ossifying Fibroma of the Maxilla  
Santos JE, Gelera JE

**PRACTICE PEARLS**

- 52 Use of Sail Excision in Alar Morphology Modification of Asian Noses  
Regalado-Go JAF, Yap EC

**FEATURED GRAND ROUNDS**

- 59 Hemangioma of the Mandible in a 12-Year-Old Boy  
Marasigan DAR, Carabeo PJF, Castañeda SS

**FROM THE VIEWBOX**

- 64 Sudden Sensorineural Hearing Loss from a Jugular Bulb Diverticulum  
Yang NW

**UNDER THE MICROSCOPE**

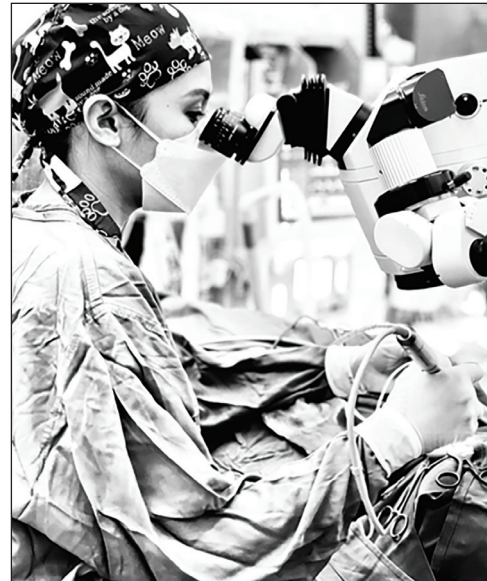- 67 Nasal Gouty Tophus  
Delmendo MPEM, Chang AMV

**PASSAGES**

- 69 Nixon S. See, MD  
Alcira RCV

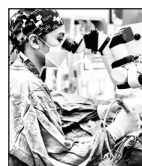**CAPTOONS**

- 70 DokNet's World  
Billones WU

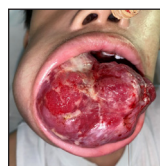

- On the Brink: The Climate and Nature Crisis and Risks of Nuclear War
- Time to Treat the Climate and Nature Crisis as One Indivisible Global Health Emergency
- Reducing the Risks of Nuclear War – The Role of Health Professionals
- Diagnosis and Management of Otosclerosis in a Filipino Population: A Case Series
- Radiographic Measurement of Nasopharyngeal Depth from the Anterior Nasal Spine (ND-ANS) Among Filipino Adults
- Factors Predisposing to Post Thyroidectomy Vocal Cord Paralysis at Ospital ng Maynila Medical Center
- Association of Clinicodemographic Factors and Tissue Biopsy Results Among Patients with Thyroid Nodules at the Southern Philippines Medical Center
- Relationship of Post-Thyroidectomy Hypocalcemia to Surgeon's Experience in a Private Tertiary Hospital
- Surgical Management of Goiter with Intrathoracic Extension at the Philippine General Hospital Department of Otolaryngology – Head and Neck Surgery
- Stratifying Indeterminate Cytology Thyroid Nodules by Combining Thyroid Imaging Reporting and Data Systems (TI-RADS) and The Bethesda System for Reporting Thyroid Cytopathology (TBSRTC)
- An Alternative Surgical Approach to Cemento-Ossifying Fibroma of the Maxilla
- Use of Sail Excision in Alar Morphology Modification of Asian Noses
- Hemangioma of the Mandible in a 12-Year-Old Boy
- Sudden Sensorineural Hearing Loss from a Jugular Bulb Diverticulum
- Nasal Gouty Tophus
- Nixon S. See, MD
- DokNet's World

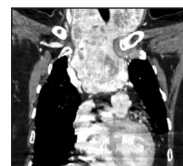**COVER IMAGES**



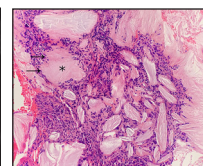
"Embrace your role and seize the day"  
iPhone 15 ProMax  
By Frederick Mars B. Untalan, MD



"Vascular tumor of the mandible"  
Oneplus 7 Pro  
By Dennis Angelo R. Marasigan, MD



"Grade 3 intrathoracic goiter" taken from a patient CT scan  
By Kevin Michael L. Mendoza, MD, MPM



"Cotton candy-like swirls of tophaceous gout" under light microscopy  
By Ann Margaret V. Chang, MD



"Sunset" 9"x16"; Oil on Canvas  
By Karen June P. Dumiao, MD