



EDITORIAL

- 4 Original Research: Descriptive or Analytical, Either-Or or Both-And?
Lapeña JFF

SPECIAL ANNOUNCEMENT

- 6 Sydney Declaration on Predatory or Pseudo Journals and Publishers
APAME WPRIM IMSEAR

ORIGINAL ARTICLES

- 7 Association of Treatment Delays with Survival for Patients with Head and Neck Cancer Undergoing Surgery and Radiotherapy at the Philippine General Hospital
Sacayan-Quitay ND, De Guzman SPC, Cañal JPA, Villafuerte CV III L
- 12 Diagnostic Accuracy and Safety of Endoscopic – Guided Office-Based Biopsies for Laryngeal and Pharyngeal Lesions at St. Luke’s Medical Center
Fernandez DR, Soriano RG
- 17 Determining the Severity of Symptoms Among Patients with Eosinophilic Chronic Rhinosinusitis with Nasal Polyposis Versus Non-Eosinophilic Chronic Rhinosinusitis with Nasal Polyposis at the Veterans Memorial Medical Center
Hizon GJS, Espanto JP, Rodriguez-Labrador KM
- 21 Regression Analysis of Preoperative Chest Radiographs to Predict Intraoperative Location of Esophageal Foreign Body (Coin) in Pediatric Patients
Balite ADM, Roldan FCA
- 26 Olfactory Dysfunction, Dysgeusia, and Clinical Outcomes in COVID-19 Patients: An Observational Study in a Tertiary COVID Referral Center in the Philippines
Tirol CJR, Fullante PB
- 32 Otorhinolaryngologic Manifestations of Long COVID-19 Infection Among Patients at the Quezon City General Hospital
Sison MNK, Cruz ETS
- 37 Telemedicine for ENT: Quality of Care During the COVID-19 Pandemic at the Jose R. Reyes Memorial Medical Center in 2022
Castro JMC, Chua RU

CASE REPORTS

- 41 Adenoid Cystic Carcinoma of the External Ear Canal: A Case Report
Caluma SEC, De Ramos JSM
- 45 Primary Melanoma of the Palatine Tonsil in an Adult Filipino Patient: A Case Report
Cabataña KLD, Salud DL

SURGICAL INNOVATIONS AND INSTRUMENTATION

- 49 A Novel Technique: Scored Conchal Cartilage to Simulate Natural Dome of Lower Lateral Cartilage in the Asian Nose
King-Chao NLY, Yap EC

FEATURED GRAND ROUNDS

- 54 A Case Report on Maxillary Ameloblastic Fibroma in a 55-Year-Old Man
Mendoza MEF, Altura IC.

FROM THE VIEWBOX

- 57 Congenital Internal Auditory Canal Stenosis
Yang NW

UNDER THE MICROSCOPE

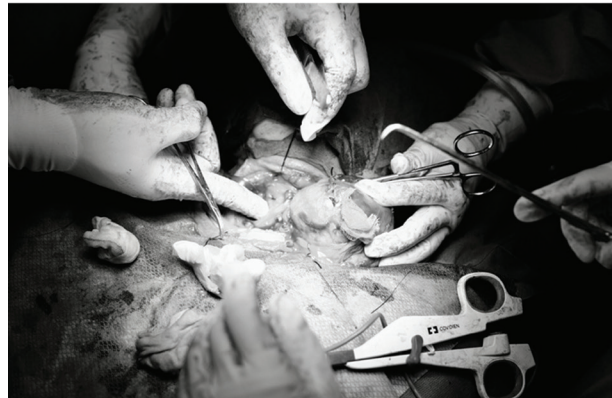- 59 Non-Invasive Follicular Thyroid Neoplasm With Papillary-Like Nuclear Features – An Illustrative Case
Mirhan CVL, Rivera JP, Carnate JM.

PASSAGES

- 61 Nikolo Ariel M. Ansaldo, MD (1983-2024)
Laganao CRD
- 62 Paul Christian P. Pacquing, MD (1986 - 2024)
Abuan MRA

CAPTOONS

- 63 DokNet’s World
Billones WU

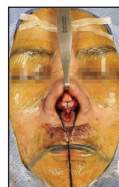

Original Research: Descriptive or Analytical, Either-Or or Both-And?
 Sydney Declaration on Predatory or Pseudo Journals and Publishers
 Association of Treatment Delays with Survival for Patients with Head and Neck Cancer Undergoing Surgery and Radiotherapy at the Philippine General Hospital
 Diagnostic Accuracy and Safety of Endoscopic – Guided Office-Based Biopsies for Laryngeal and Pharyngeal Lesions at St. Luke’s Medical Center
 Determining the Severity of Symptoms Among Patients with Eosinophilic Chronic Rhinosinusitis with Nasal Polyposis Versus Non-Eosinophilic Chronic Rhinosinusitis with Nasal Polyposis at the Veterans Memorial Medical Center
 Regression Analysis of Preoperative Chest Radiographs to Predict Intraoperative Location of Esophageal Foreign Body (Coin) in Pediatric Patients
 Olfactory Dysfunction, Dysgeusia, and Clinical Outcomes in COVID-19 Patients: An Observational Study in a Tertiary COVID Referral Center in the Philippines
 Otorhinolaryngologic Manifestations of Long COVID-19 Infection Among Patients at the Quezon City General Hospital
 Telemedicine for ENT: Quality of Care During the COVID-19 Pandemic at the Jose R. Reyes Memorial Medical Center in 2022

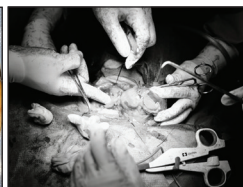Adenoid Cystic Carcinoma of the External Ear Canal: A Case Report
 Primary Melanoma of the Palatine Tonsil in an Adult Filipino Patient: A Case Report
 A Novel Technique: Scored Conchal Cartilage to Simulate Natural Dome of Lower Lateral Cartilage in the Asian Nose
 A Case Report on Maxillary Ameloblastic Fibroma in a 55-Year-Old Man
 Congenital Internal Auditory Canal Stenosis
 Non-Invasive Follicular Thyroid Neoplasm With Papillary-Like Nuclear Features – An Illustrative Case

Nikolo Ariel M. Ansaldo, MD (1983-2024)
 Paul Christian P. Pacquing, MD (1986 - 2024)
 DokNet’s World

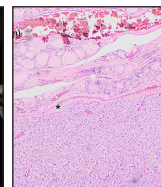
COVER IMAGES



“Novel Technique for Tip Grafting: Scored Conchal Cartilage”
 Samsung S23 Ultra
 By Eduardo C. Yap, MD




“Helping Hands”
 Fujifilm X-T5
 By Neil Louis L. Apale, MD



“A thyroid nodule composed of microfollicles separated from the adjacent normal thyroid tissue by a thin yet intact capsule (H&E 40x magnification)”
 Olympus BX53; Olympus CellSens standard
 By Jose M. Carnate, Jr., MD



“PJOHNS hopping through the creamier shoreline of the south”
 “Tanduh Beach Parang, Sulu”
 iPhone 14 pro max
 By Mohammad Ariff A. Baguidali, MD



“Enlightened Drink”
 Watercolor on paper, 15”x21”
 By Ruzanne M. Caro, MD