

Ivy V. Tangco, MD
Felixberto D. Ayahao, MD

Department of Ear Nose Throat – Head and Neck Surgery
Baguio General Hospital and Medical Center

Naso-Glabello-Frontal Advancement Reconstruction for Chondroid Syringoma of the Nasal Tip

ABSTRACT

Objective: To present a naso-glabello-frontal advancement modification of the dorsal advancement (Rintala) flap for reconstruction of an unusual case of chondroid syringoma occurring at the nasal tip.

Methods:

Design: Case Report
Setting: Tertiary Government Training hospital
Patient: One

Results: A 23-year-old man who presented with a nasal tip mass initially diagnosed as a benign adnexal tumor underwent excision and reconstruction with a naso-glabello-frontal advancement flap modification of the dorsal advancement flap with median brow lift. The procedure resulted in nasal tip reconstruction with minimal scars, including a horizontal upper medial brow margin scar that eventually became less apparent. Final histopathology revealed a rare benign mixed tumor, chondroid syringoma.

Conclusion: The naso-glabello-frontal advancement flap is a one-stage procedure that can be used to reconstruct such a cutaneous nasal defect after tumor excision. The modification observes nasal aesthetic subunits and may have a better aesthetic outcome than traditional rotational or advancement flaps.

Keywords: *rhinoplasty, surgical flaps, sweat gland neoplasm*

A chondroid syringoma or mixed tumor of skin is a rare, benign skin adnexal tumor of sweat gland origin, which is most commonly seen in the head and neck region of patients who are in the sixth and seventh decades.¹ It is usually seen as a single, small, painless, firm, non-ulcerated dermal or subcutaneous nodule in the head and neck area. The lesion commonly measures 0.5–3 cm in diameter and is usually flesh colored but may be translucent or yellowish. The sites of predilection are the cheek, nose, or skin above the lip with the lower eyelids being the most common site.^{2,3} They do not tend to involute, and may present a cosmetic problem when located on the face.³

With a 2.5 x 2.5 cm defect on the nasal tip after excision of such a tumor in a young man, what reconstruction could we perform to lessen tension of closure, ensure flap survival and minimize extensive scars? Cutaneous defects of the nasal dorsum to the tip are usually managed by rotation flaps from the forehead and nasolabium or rotation advancement flaps from the nasal dorsum-glabella-forehead complex. The former technique involves two operative procedures (to sever the flap pedicle from the recipient site and perform final reconstruction after the flap has healed), while the latter involves a long incision from forehead to glabella and one side of the naso-maxillary groove.⁴ Although scars could become inconspicuous in time, there are patients who are scar formers. The dorsal advancement (Rintala) flap is an example of the latter. While it

Correspondence: Dr. Felixberto D. Ayahao
Department of ENT-HNS
Baguio General Hospital and Medical Center
Governor Pack Road, Baguio City, Benguet 2600
Philippines
Telefax: (074) 444 4176
Email: entbaguio@yahoo.com

The authors declared that this represents original material that is not being considered for publication or has not been published or accepted for publication elsewhere, in full or in part, in print or electronic media; that the manuscript has been read and approved by the authors, that the requirements for authorship have been met by each author, and that each author believes that the manuscript represents honest work.

Disclosures: The authors signed disclosures that there are no financial or other (including personal) relationships, intellectual passion, political or religious beliefs, and institutional affiliations that might lead to a conflict of interest.

Presented at: 2015 ORL-HNS Annual Convention



Creative Commons (CC BY-NC-ND 4.0)
Attribution - NonCommercial - NoDerivatives 4.0 International

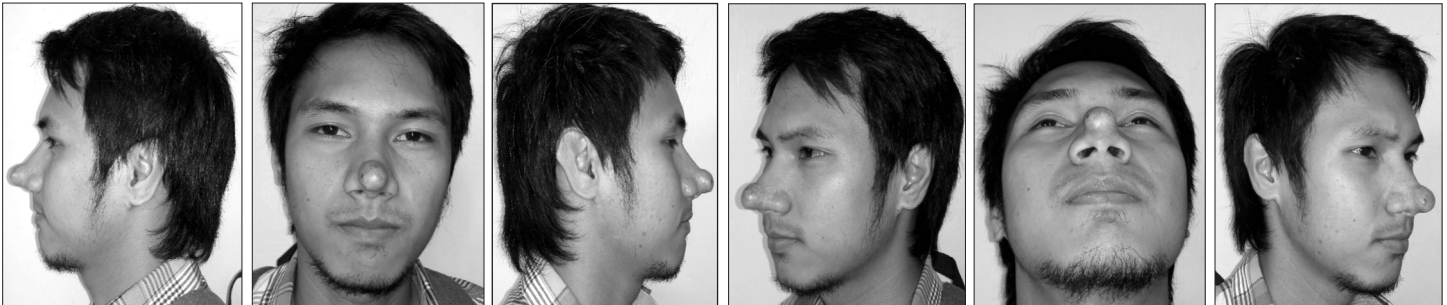

Figure 1. Pre-operative photos (reproduced in full, with permission). Note the nasal tip deformity caused by the tumor.

can reconstruct tip defects with good perfusion, it has the disadvantage of long bilateral scars from the eyebrow to the defect.⁵

We introduce a naso-glabello-frontal advancement modification of the dorsal advancement flap that aimed to reconstruct the cutaneous nasal defect with minimal scars. It is a one-stage procedure and allows reconstruction according to nasal aesthetic subunits while maximally preserving the blood supply for flap survival.

CASE REPORT

A 23-year-old man was admitted for a nasal tip mass that began as a papular lesion on the nasal tip two years before, with no associated erythema or tenderness. With no improvement despite unrecalled medications prescribed by a dermatologist, the patient was lost to follow up. The mass gradually enlarged, prompting consult at our institution. There were no associated signs and symptoms. The patient had no other known diseases, was a non-smoker and an occasional alcoholic beverage drinker, with no exposure to radiation or chemicals. There was no family history of cancer, or other heredo-familial diseases.

Physical examination revealed a 2.5 x 2.5 cm firm, nontender, slightly mobile, protruding nodule located at the nasal tip with no skin changes. (Figure 1) A soft tissue lateral radiograph revealed a well-defined soft tissue shadow measuring 2 x 2 cm with no blastic/ lytic changes. The rest of the visualized osseous structures were unremarkable. (Figure 2)

Surgical Technique

Under general anesthesia, 1:100,000 epinephrine and 1% lidocaine was infiltrated in skin markings around the nasal tip mass, naso-maxillary area, glabellar and supraorbital vascular pedicles. (Figure 3A) Using a No.15 blade, the tumor was excised 3 mm around the mass. (Figure 3B) A horizontal incision at the superior edge of the defect was extended to pass thru the oblique line of the alar groove. Through the defect, the skin of the dorsum was undermined in the subcutaneous plane extending to the naso-maxillary region, glabella and medial forehead to decrease flap tension by advancing skin. (Figure 3C) Meticulous hemostasis was achieved using selective cautery, taking care not to injure major blood vessels.

The brow that was displaced caudally was repositioned to its horizontal plane by excising a triangular island with the base parallel to the uppermost hair follicles of the brow, preserving the supra-orbital

neurovascular bundle. Closure was facilitated by a vertical lateral glabellar incision medial to the median edge of the brow. (Figure 3D) Incisions were closed in two layers with 4-0 monocryl subcuticular and 6-0 nylon skin sutures.

Outcomes

A plaster of Paris nasal cast was maintained for 5 days to prevent hematoma formation and to maintain flap projection caudally until soft tissue healing was stable. On follow up after 2 weeks, there was good wound apposition and minimal swelling of the nasal dorsum and superior brow areas. The patient was advised to begin application of cyclopentasiloxane + Vitamin C silicone gel (Dermatix[®] Ultra, Hanson Medical, Inc., Kingston, WA, USA). There was no facial swelling and progressively less visible scars at 2 and 10 months follow up. (Figure 4, 5) Final histopathologic diagnosis was chondroid syringoma. (Figure 6)

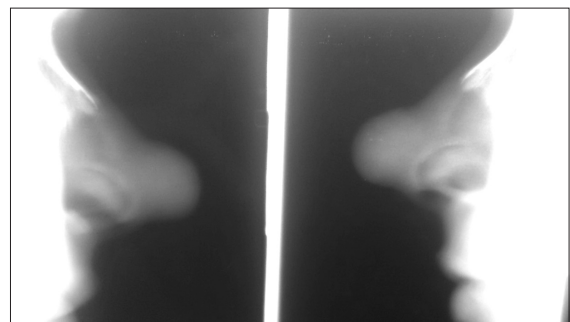


Figure 2. Soft Tissue Lateral Radiographs. A well-defined soft tissue density is seen on the inferior aspect of the nasal area approximately measuring 2 x 2 cm, and negative for blastic/lytic changes. The rest of the visualized osseous structures are unremarkable.

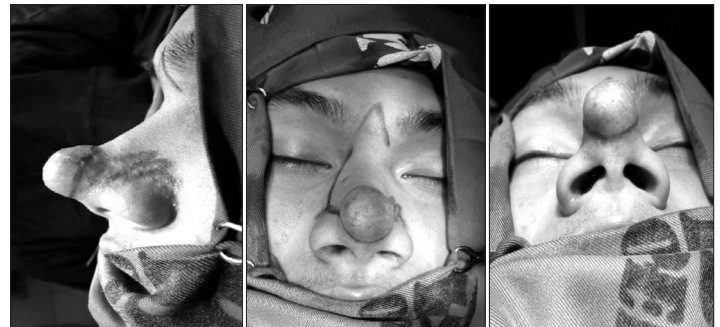

Figure 3. Surgical Procedure (photos reproduced in full, with permission).
A. Skin markings

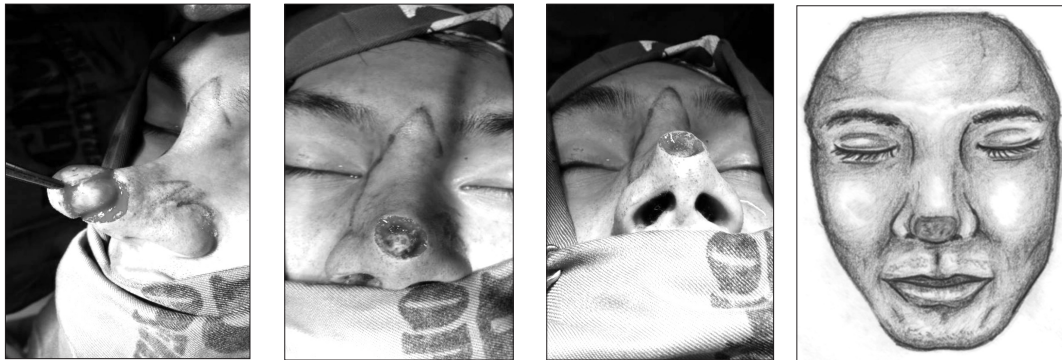


Figure 3. Surgical Procedure (photos reproduced in full, with permission).
B. Excision approximately 3 mm from the mass, extended to pass thru the oblique line of the alar groove.

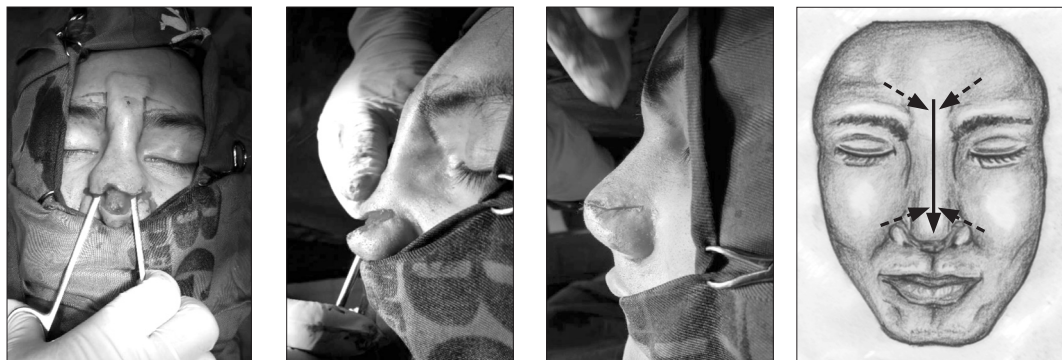

Figure 3. Surgical Procedure (photos reproduced in full, with permission).
C. Approximation of the flap to the recipient bed after extensive undermining of the nasal dorsum, naso-maxillary area and forehead.

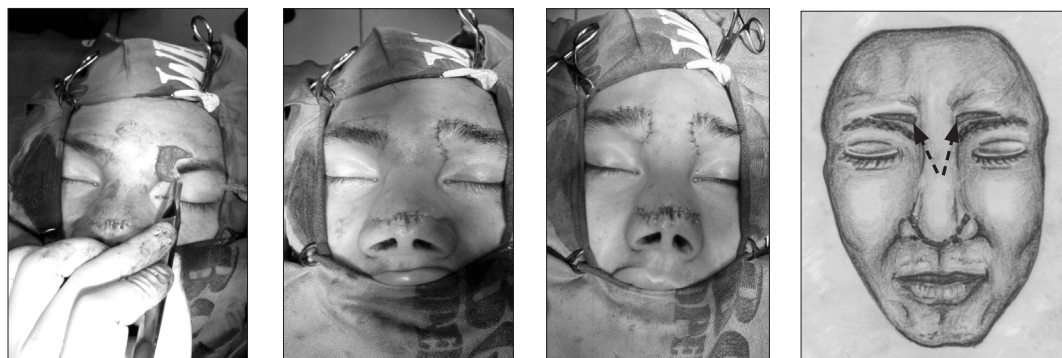

Figure 3. Surgical Procedure (photos reproduced in full, with permission).
D. Median brow lift

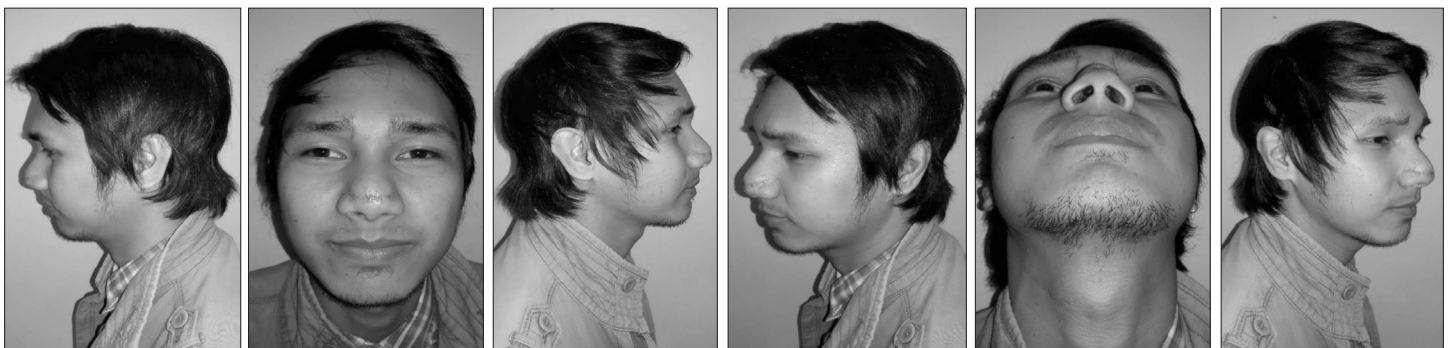

Figure 4. Two months post-operative photos (reproduced in full, with permission).



Figure 5. Ten-months post-operative photos (reproduced in full, with permission).

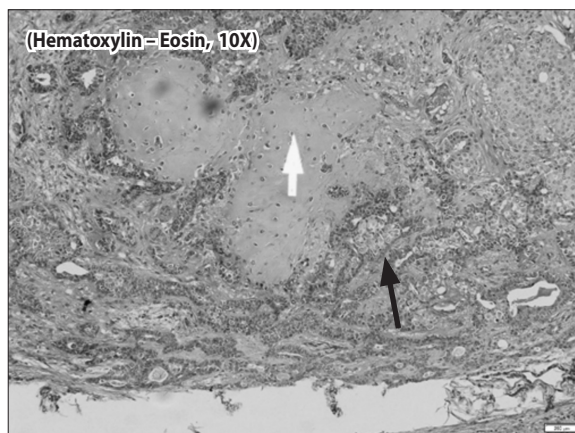


Figure 6. Histopathologic slides (Hematoxylin-Eosin stain, 10x) showing Chondroid Syringoma. Light arrow shows chondromyxoid stroma; dark arrow shows intercommunicating tubulo-alveolar structures lined with two or more rows of cuboidal cells and ductal structures composed of one or two rows of cuboidal cells.

DISCUSSION

One-step traditional skin flaps for nasal tip defects include the dorsal nasal advancement (Rintala) flap, double L shaped skin flap, nasalis musculocutaneous sliding skin flap and the lateral nasal (Miter) skin flap.^{4,5} Two-step reconstructions include the nasolabial and forehead flaps.⁴ The one-step techniques mentioned result in long scars and dog ears, but save effort and time.⁴ The nasolabial and forehead techniques result in less scars, but involve two operations to sever the flap pedicle from the recipient site.⁴

Our naso-glabello-frontal advancement technique is a one-stage procedure that reconstructs a cutaneous nasal tip defect with the least scars possible. Aesthetic defects are managed with addition of the median brow lift. The flap is designed to fully mobilize the subcutaneous space of the dorsum of the nose to the naso-maxillary groove on both sides then up to the glabella and the medial forehead. When the flap is pulled caudally depending on the size of the defect to be covered, the medial brow is also displaced caudally. A triangular piece of skin with a longer horizontal plane is then excised above the brow margin, preserving the supraorbital neurovascular bundle and the brow is fixed

with a periosteal suspension flap. A lateral glabellar extension of the vertical side of the triangle facilitates brow closure. This additional step, the median brow lift, is used to restore the brow position.

Our innovation allows reconstruction according to specific nasal aesthetic units, and there is good flap survival owing to random and specific blood supply. The flap is applicable for smaller defects of 2-3cm and has good skin color match and texture, without the skin tension and dog ears of traditional techniques. One limitation is that entire defects of the nasal dorsum and tip defects cannot be repaired by our technique, and still are better reconstructed by forehead flaps. Another limitation is lack of reach to the extreme caudal tip of the nose particularly the columella and the vestibular surface of the ala.

It is recommended that extensive undermining of the nasal dorsum to the forehead and naso-maxillary areas be done. At the end of the procedure and during the healing process, close postoperative follow-up is mandatory along with liberal use of postoperative adjuncts including dermabrasion, steroid scar injection, and topical silicone sheeting. The naso-glabello-frontal advancement flap technique is a reproducible and simpler advancement flap technique than other one step traditional techniques. However, long-term aesthetic outcomes with more patients remain to be seen.

ACKNOWLEDGEMENTS

We thank Dr. Jefferson Peckley, Dr. Wingleaf Yu and Dr. Elmer Fabito, residents of the department of ORL-HNS Baguio who assisted in performing the surgical technique.

REFERENCES

1. Kallam AR, Krishna R, Thumma RR, Setty VK. Mixed tumour of ala nasi: a rare case report and review. *J Clin Diagn Res.* 2013 Sep; 7(9): 2019-2020.
2. Kalsoom R, Roohi M, Aziz F. Chondroid syringoma – A case report. *Biomedica.* 2014 Jan-Mar; 30 (1):53-54.
3. Viswanatha B, Puttamadaiah GM, Shruthi GS, Shinde S, Krishna N, Priyadarshini V. Chondroid syringoma: An unusual cause of growing nasal tip. *FCM.* 2015;2(2):34-37.
4. Strausch B, Vasconez L, Hall-Findlay E, Lee B. *Grabb's Encyclopedia of Flaps*, 3rd ed. Philadelphia PA USA: Lippincott Williams and Wilkins; 2009;1: p.112-116,122-129,137-147.
5. Ebrahimi A, NejadSarvari N, Koushki ES. Application of modified Rintala flap in nasal tip reconstruction. *Am J Otolaryngol.* 2012 Nov-Dec;33(6):685-8. Epub 2012 Jul 2.