

Calcifying Cystic Odontogenic Tumor Associated with a Complex Odontoma

Jenny Maureen L. Atun, MD¹
Jose M. Carnate, Jr., MD²

¹Department of Laboratories,
University of the Philippines
Philippine General Hospital

²Department of Pathology,
University of the Philippines College of Medicine
Philippine General Hospital

We present a case of a 16-year-old lad with a one year history of gingival mass of the left maxillary alveolar ridge. Excision revealed a cystic mass with brown fluid and irregular calcified material within the cavity.

Histopathologic examination of the cyst lining shows a stratified cuboidal epithelium with palisading of the basal layer. The cells of the latter show reverse nuclear polarization reminiscent of ameloblastic epithelium. The superficial layers have a stellate reticulum-like appearance and contain large eosinophilic polygonal ghost cells. (Figure 1, 2) Some of the ghost cells show calcifications. (Figure 3) Sections from the hard, bony fragments show haphazard deposition of dentin and enamel-like material. (Figure 4) With these features, this case was called a calcifying cystic odontogenic tumour in association with a complex odontoma.

Calcifying cystic odontogenic tumor (CCOT) is a benign neoplasm characterized by an ameloblastoma-like epithelium with ghost cells that often show calcification.¹ It comprises only 2% of all benign odontogenic neoplasms.² There is equal distribution of involvement for the maxilla and mandible, no sex predilection with most cases diagnosed at the second to third decade of life.^{1,2} The classic histologic findings are the presence of a stratified epithelium consisting of cuboidal to columnar cells with reverse polarization of the basal layer and the presence of ghost cells. A stellate reticulum-like appearance of epithelial cells is also seen. Ghost cells are the most characteristic feature of CCOT and this may represent an abnormal type of keratinization or the coagulative necrosis of the odontogenic epithelium.³

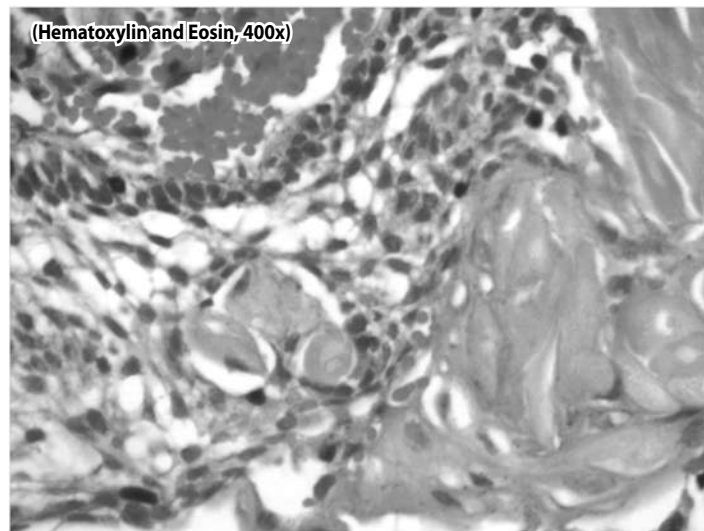


Figure 1. Hematoxylin and Eosin (400x) Cyst lining with basal palisading, stellate reticulum and ghost cells

Correspondence: Dr. Jose M. Carnate, Jr.
Department of Pathology
College of Medicine, University of the Philippines Manila
547 Pedro Gil St., Ermita, Manila 1000
Philippines
Phone (632) 526 4450
Fax (632) 400 3638
Email: jmcjpath@yahoo.com
Reprints will not be available from the authors.

The authors declared that this represents original material that is not being considered for publication or has not been published or accepted for publication elsewhere, in full or in part, in print or electronic media; that the manuscript has been read and approved by the authors, that the requirements for authorship have been met by the authors, and that the authors believe that the manuscript represents honest work.

Disclosures: The authors signed disclosures that there are no financial or other (including personal) relationships, intellectual passion, political or religious beliefs, and institutional affiliations that might lead to a conflict of interest.

CCOT may present alone or in association with other odontogenic tumours.^{2,4} Association with an odontoma has been reported in 20% to 24% of cases of CCOT.⁵ Complex odontoma is a hamartomatous lesion characterized by haphazard arrangement of matrix-producing epithelium, enamel, dentin and cementum-like tissue, in contrast to the more regular structure of a compound odontoma.¹

CCOT associated with odontoma (CCOTaO), in contrast to CCOT alone, has a slight female predominance (2:1), a younger age of presentation (mean 16 years) and a predilection to the maxilla (61.5 %).⁵ Sidana *et al.* postulated several possible pathogenesis of CCOTaO including the possibility that CCOT develops secondarily from the epithelium

involved in the formation of odontoma or that the odontoma develops secondarily from the epithelium in CCOT.⁵ Enucleation is the treatment of choice and is curative.

A close histologic differential diagnosis is an acanthomatous ameloblastoma. Acanthomatous ameloblastoma contains distinct squamous epithelium within nests of ameloblastic epithelium, and ghost cells are absent.

Very rarely, transformation into its malignant counterpart, ghost cell odontogenic carcinoma (GCOC), has been reported in recurrent cases.^{6,7} Infiltrative borders, nuclear atypia and increased mitotic activity indicate this change.^{6,7}

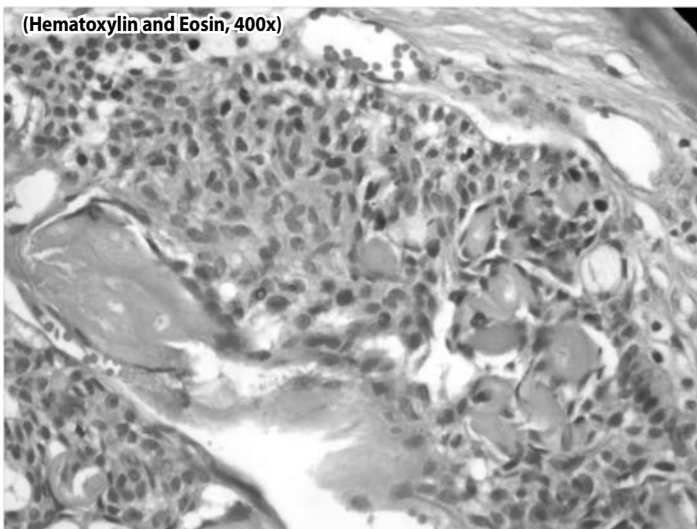


Figure 2. Hematoxylin and Eosin (400x) Ghost cells, stellate reticulum and basal palisaded cell

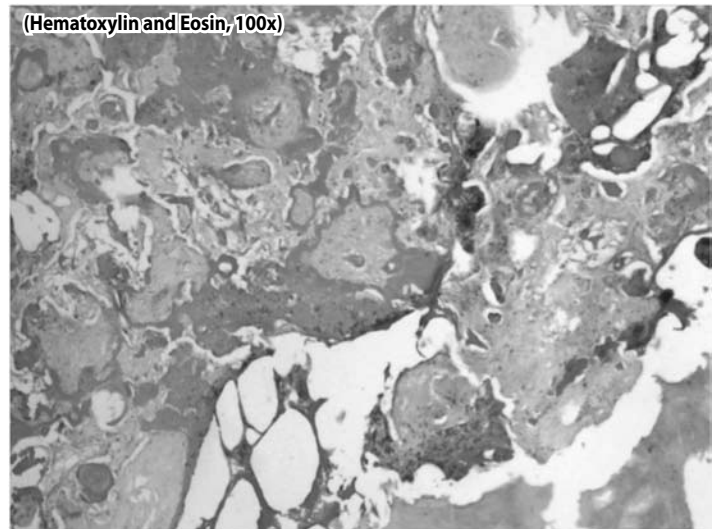


Figure 4. Hematoxylin and Eosin (100x) Haphazard deposits of dentine and enamel-like matrix of the complex odontoma.

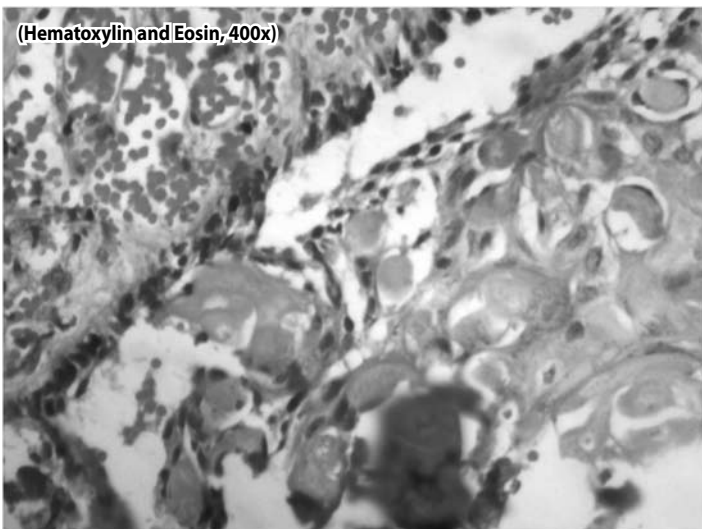


Figure 3. Hematoxylin and Eosin (400x) Calcifications within the ghost cells.

REFERENCES

1. Praetorius F, Ledesma-Montes C. Calcifying cystic odontogenic tumour. In: Barnes L, Eveson JW, Reichart P, Sidransky D. Eds. World Health Organization Classification of Tumours. Pathology and Genetics of Head and Neck Tumours. 2005; Lyon: IARC Press. p. 313.
2. Chindasombatjaroen J, Poomsawat S, Klongnoi B. Calcifying cystic odontogenic tumor associated with other lesions: case report with cone-beam computed tomography findings. *Oral Surg Oral Med Oral Pathol Oral Radiol.* 2012 Mar; 113(3):414-420.
3. Sharma B, Singh S, Bhardwaj P. Calcifying cystic odontogenic tumour: A case report and review on nomenclature. *International Journal of Oral and Maxillofacial Pathology.* 2012; 3(1):79-85.
4. Cury SE, Cury SN, Cury M, Calderoni A, Fajardo VD, Carvalho MR, et al. Calcifying cystic odontogenic tumor: Case report. *WebmedCentral Oral Medicine* 2011;2(12):WMC002583. [cited 24 October 2013] Available from http://www.webmedcentral.com/wmcpdf/Article_WMC002583.pdf.
5. Sidana S, Poonja K, Galinde J, Poonja LS. Calcifying cystic odontogenic tumor with compound odontoma. *Journal of Contemporary Dentistry.* 2013 Jan-Apr; 3(1): 36-39. DOI: 10.5005/jp-journals-10031-1032.
6. Zhu ZY, Chu ZG, Chen Y, Zhang WP, Ly D, Genb N, Yang MZ. Ghost cell odontogenic carcinoma arising from calcifying cystic odontogenic tumour: A case report. *Korean J Pathol.* 2012 Oct; 46(5): 478-482.
7. Habibi A, Saghravanian N, Salehinejad J, Jafarzadeh H. Thirty years clinicopathological study of 60 calcifying cystic odontogenic tumours in Iranian population. *The Journal of Contemporary Dental Practice* 2011 May-Jun; 12(3): 171-173. DOI: 10.5005/jp-journals-10024-1029.