

Charlotte M. Chiong, MD^{1,2,3}

¹Department of Otorhinolaryngology
College of Medicine-Philippine General Hospital
University of the Philippines Manila

²Philippine National Ear Institute
National Institutes of Health
University of the Philippines Manila

³Department of Otorhinolaryngology
Manila Doctors Hospital
Manila, Philippines

Correspondence: Charlotte M. Chiong, MD
Department of Otorhinolaryngology
Ward 10, Philippine General Hospital
Taft Ave., Ermita, Manila 1000
Philippines
Fax: (632) 526 4360
Email: charlotte_chiong@yahoo.com
Reprints will not be available from the author.

The author declared that this represents original material that is not being considered for publication or has not been published or accepted for publication elsewhere, in full or in part, in print or electronic media; that the manuscript has been read and approved by the author, that the requirements for authorship have been met by the author, and that the author believes that the manuscript represents honest work.

Disclosures:
Professor Joachim Müller was funded by Medical Electronics to travel to Manila from Germany to perform the first EAS cochlear implant surgery with the author. The author is occasionally invited as a speaker for Med-EI for which she receives honoraria and travel allowances. Other than this, she does not have any proprietary or financial interests with Med-EI or with any organization that may have a direct interest in the subject matter of the manuscript, or in any product used or cited in this article. She has no other relevant conflicts of interest to declare.


Combined Electric and Acoustic Stimulation: Successful Treatment Option for Partial Deafness

Cochlear implants are now the treatment of choice for patients with severe to profound hearing loss. Inclusion criteria for cochlear implantation have expanded and a whole array of implantable hearing devices have been introduced over the years. To date, more than 250 cochlear implantations have now been performed in the Philippines (*Figure 1*). In 2006, the first auditory brainstem implantation, and first vibroplasty or middle ear implantation in the country were done at the Philippine General Hospital (PGH). In 2008, the first electroacoustic stimulation or partial deafness cochlear implantation surgery in the country was performed at the Capitol Medical Center by Professor Joachim Müller of the University of Würzburg and the author. This concept that cochlear implantation can be performed for patients with residual hearing or only partial deafness is quite novel. There are patients whose low frequency hearing below 1.5 kHz is still be quite good while high frequency hearing loss above 1.5 kHz is in the severe to profound range (*Figure 2*). For such patients speech discrimination scores will typically fall below 60% at 65 dB sound pressure level (SPL) in the best aided condition.

This technological advancement, often called electroacoustic stimulation (EAS), was developed in 1999 after Christoph Von Ilberg demonstrated preserved residual low frequency hearing in a patient who underwent cochlear implantation such that the patient wore a hearing aid in the implanted ear.¹

Currently, EAS devices are available from two manufacturers. Contraindications to the use of EAS are shown in *Table 1*. Candidates for EAS devices should have stable low frequency hearing. There should be no progressive or autoimmune sensorineural hearing loss. Also there should be no history of meningitis, otosclerosis, or any other malformation that might cause an obstruction. The patient's air-bone gap should be ≤ 15 dB. Finally, there should not be any external auditory canal problems that can impede placement of the ear mould for the acoustic component.

There are two main components of the EAS system (*Figure 3*). The external component is made up of a microphone that picks up sounds and a processor that separately encodes low and high frequency energy. After processing, low frequency energy is converted into an acoustic signal via the loudspeaker located in the ear hook and delivered into the external auditory canal. This acoustic signal will vibrate the tympanic membrane and ossicles so that cochlear fluids as well as the relatively intact structures of the cochlea in the apical region are stimulated. In contrast, high frequency energy is coded into radio-wave-like signals which are transmitted transcutaneously to the internal receiver. There, electric signals are delivered to the electrode array that has been surgically implanted into the cochlea. Thus the auditory nerve receives information using two different pathways from low and high frequency sounds and the auditory nerve signals are then transmitted to the brain.



Our Experience

Of the more than 100 implantations done under the Philippine National Ear Institute “CHIP” or Cochlear and Hearing Implants Programme only one was a case of EAS implantation. This particular case demonstrates key principles and concepts that every otolaryngologist should consider. Among these are audiological evaluation, temporal bone imaging, surgical technique for hearing preservation and some quality of life issues.

Audiological Evaluation

A 33-year-old man had been seen at the clinic for over seven years, with serial audiograms (Figure 4-6) illustrating the presence of good and stable low frequency hearing while high frequency hearing loss increased somewhat. The patient had been continually advised to get the best hearing aids available. However, a series of high-end hearing aids did not solve his problem of poor hearing in noisy places nor his difficulty understanding words when watching television and movies. Figure 7A shows the speech perception scores of this patient obtained with a Word Intelligibility by Picture Identification (WIPI) test, a “closed-set test” using isolated words while Figure 7B represents speech scores when “open-set” Bamford-Kowal-Bench (BKB) Sentence Lists were presented to the listener in both quiet and noise prior to the implantation.

Temporal bone imaging

A combination of high resolution computerized tomography (HRCT) of the temporal bone with both coronal and axial cochlear views and T2-weighted normal anatomic Fast Spin Echo (T2 FSE) or 3D Constructive Interference in Steady State (3D CISS) MRI sequences of the inner ear should be done. Results from both studies should ascertain whether the cochlear duct is patent, ruling out any cochlear fibrosis or obstructive pathology. This patient’s HRCT and 3-D CISS MRI studies showed no such cochlear obliteration that would have posed intraoperative difficulties and constituted contraindications to EAS surgery (Figure 8).

Surgical Technique for Hearing Preservation

A variety of techniques have evolved over the years into what is now commonly called minimally invasive cochlear implantation. Using minimally invasive techniques, residual hearing can indeed be preserved in over 80%-90% of patients^{3,4} Initially, a “Soft Cochleostomy” technique was introduced. This entailed careful low-speed drilling of the promontory with a Skeeter® drill (Medtronic Xomed, Jacksonville FL, USA) followed by the use of a mini-lancet to make an opening in the membranous labyrinth. This method avoids direct suctioning

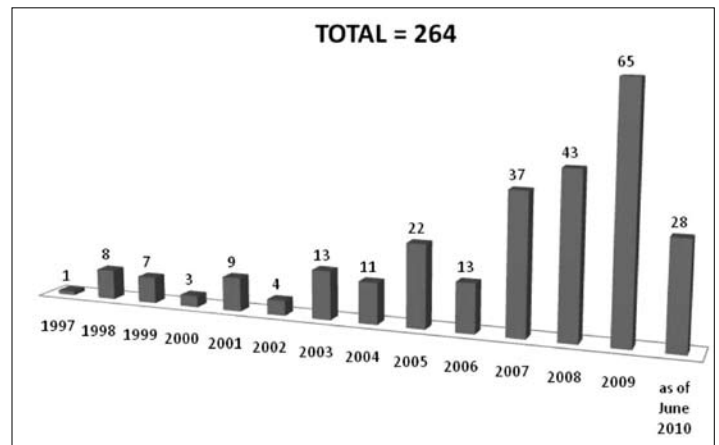


Figure 1. Cochlear Implantation in the Philippines

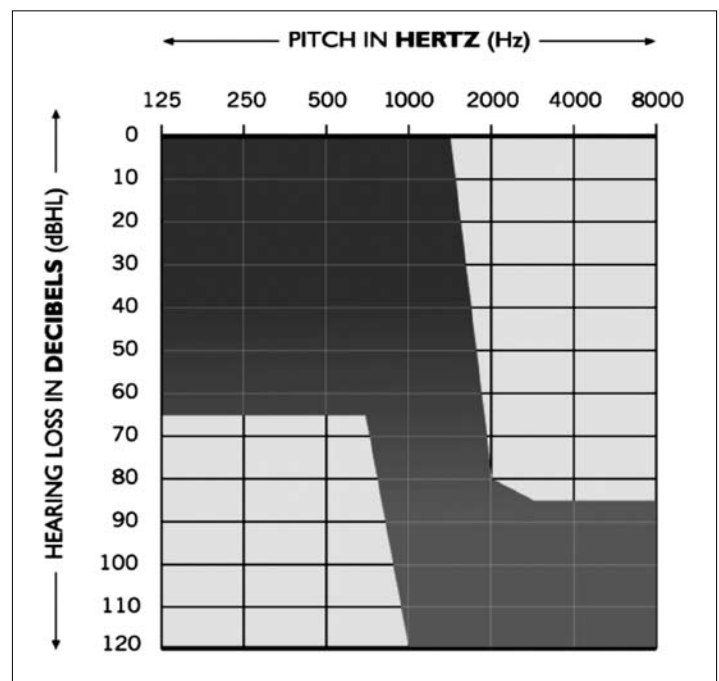


Figure 2. Candidates for EAS should have thresholds within the shaded areas. Reproduced with permission from Med El “EAS™ Hearing Implant System- the ideal solution for partial deafness” [monograph], Innsbruck, Austria: Med El ©2010 [cited 2010 November 10] Available from <http://www.medel.com/data/downloads/EAS/21707.pdf>

Table 1 . List of contraindications to EAS

Contraindications to EAS
Progressive hearing loss
Autoimmune disease
Hearing loss as a result of meningitis, otosclerosis or ossification
Malformation or obstruction of the cochlea
Air-bone gap > 15dB
External ear contra-indications to using amplification devices

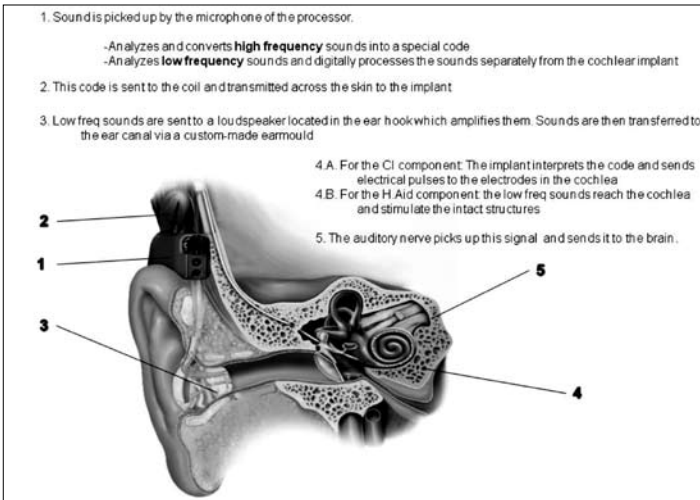


Figure 3. The combination of acoustic stimulation from the hearing aid and the electric stimulation from the electrode array within the cochlea. Reproduced with permission from Med El "EAS™ Hearing Implant System- the ideal solution for partial deafness" [monograph], Innsbruck, Austria: Med El ©2010 [cited 2010 November 10] Available from <http://www.medel.com/data/downloads/EAS/21707.pdf>

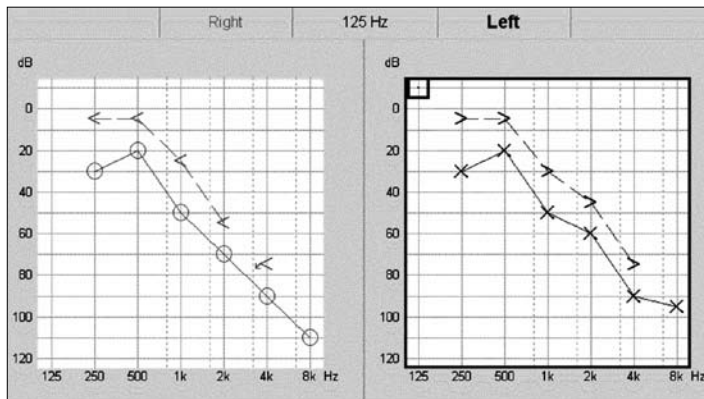


Figure 4. Audiogram in 2001

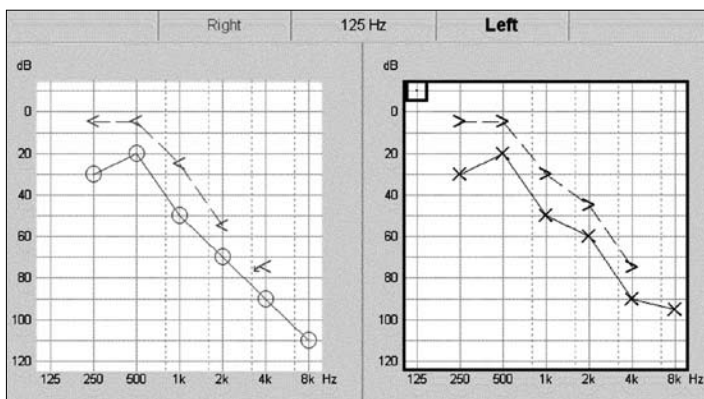


Figure 5. Audiogram in 2003

and prevents ingress of blood and bone dust into the intracochlear compartment. Also for this method, the endosteum is left intact after drilling a cochleostomy antero-inferior to the round window. This allows proper placement of the electrode into the scala tympani with less chance of injury to the basilar membrane. Later, a round window approach was introduced, and it also proved to be a reliable way to preserve residual hearing during cochlear implantation. For this method, a more direct round window approach is performed after careful drilling of the round window niche. A limited incision is made just large enough to allow the electrode to be inserted. For both methods, after the endosteal or round window membrane incision is made with a micro lancet, a very flexible electrode of 20 mm length is slowly inserted. During the insertion process, the cochleostomy or round window is kept under direct vision so that insertion forces are minimized. Topical antibiotics and steroids are applied at this time to reduce any inflammatory or apoptotic reactions related to the trauma of opening the cochlea and introducing an electrode. Finally, a soft tissue plug is placed tightly around the electrode entry point into the membranous labyrinth to prevent perilymph leakage. New electrode designs that are thinner and more flexible are important contributors to the preservation of hearing.

Postoperative Outcomes and Quality of Life

After about 4-6 weeks from the time of surgery the EAS implant is switched on. Based on our experience and that of others,³ speech perception performance improves with prolonged experience with the implant. Roughly 1 ½ years post-surgery this patient has achieved dramatic improvement in hearing both in quiet and in noise using the EAS compared to using only the hearing aid component or the CI component alone. *Figure 9* shows this dramatic improvement in free-field pure tone thresholds. *Figure 10* demonstrates the speech perception following EAS implantation compared to pre-EAS implantation. Audiologic evaluation done at the PGH Ear Unit using 20 phonetically balanced Filipino words familiar to the patient in quiet and with 55 dB masking noise in the side of the implanted ear clearly showed an advantage with the EAS configuration compared to either hearing aid or CI component alone. Even with noise, this patient actually performed better presumably because he may have concentrated more with the introduction of masking noise. Another factor of course is that the words have now become familiar to the patient with the previous testing done in quiet.

Notably, he reported great subjective improvement after only 10 months post-surgery.⁵ Interestingly the patient's only complaint during his last follow-up was that he had not been offered bilateral EAS

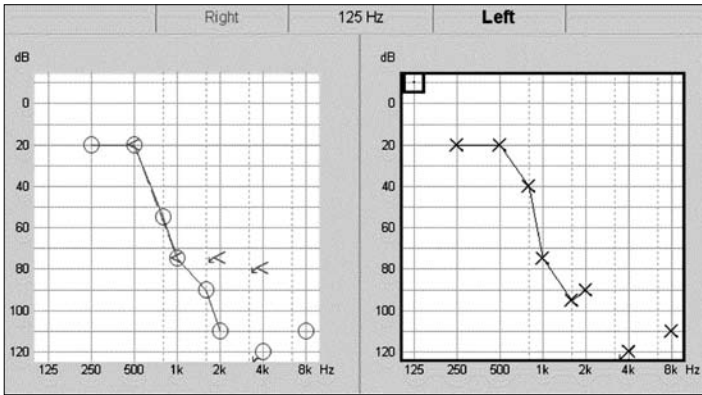


Figure 6. Audiogram in 2008 prior to EAS surgery

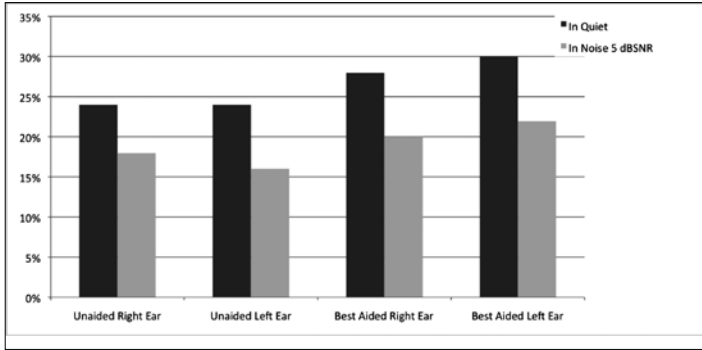


Figure 7A. Closed-set Test Pre- EAS surgery*

* Materials used: Word Intelligibility by Picture Identification (WIPI)
 Unaided test at 100 dBHL
 In Noise at 5 dB SNR
 Best - Aided Condition at 65 dB SPL
 (Test Dated June 8, 2008)
 Four lists were used
 No device was worn in the left (non-implanted) ear during all the tests in quiet or noise, pre- EAS implantation

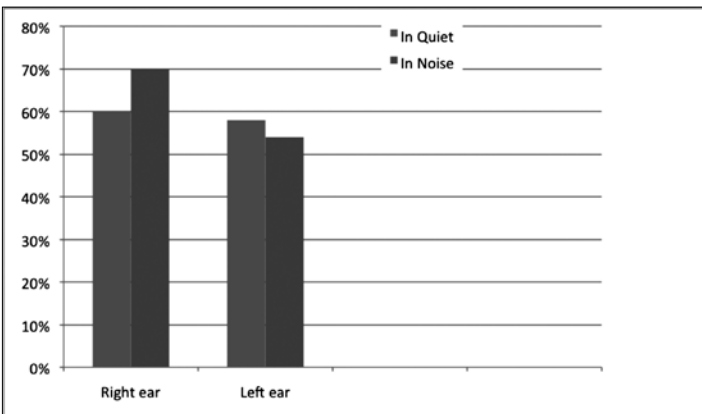


Figure 7B. Open set words in sentences Test Pre- EAS Surgery*

* Best Aided Condition at 65 dB SPL
 In Noise at 5 dB SNR
 Materials used: Bamford-Kowal-Bench (BKB) Sentence Lists
 Test dated June 8, 2008
 Four lists were used
 No device was worn in the left (non-implanted) ear during all the tests in quiet or noise, post-EAS implantation

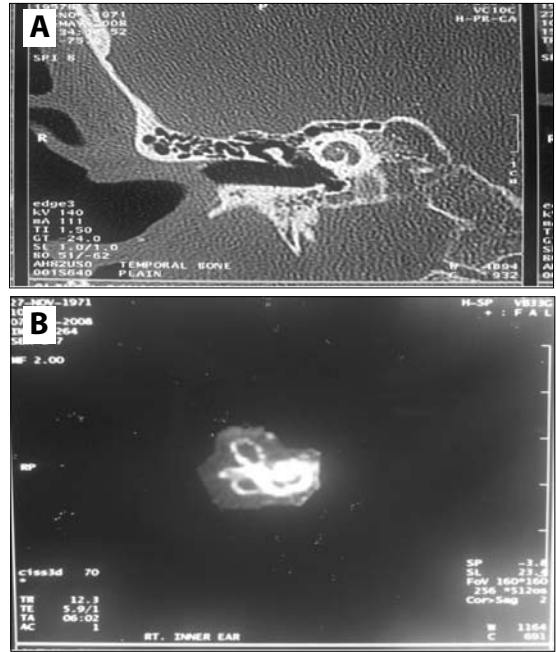


Figure 8. Coronal HRCT of the right cochlea (A) and 3-D CISS MRI study of the right cochlea (B)

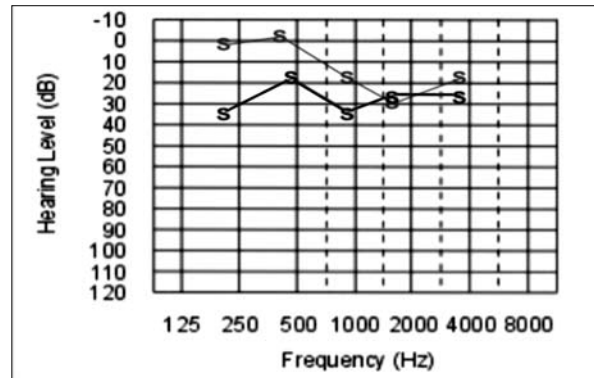


Figure 9. Free Field Pure Tone Thresholds following EAS in quiet (light upper line) and in noise (heavy lower line)

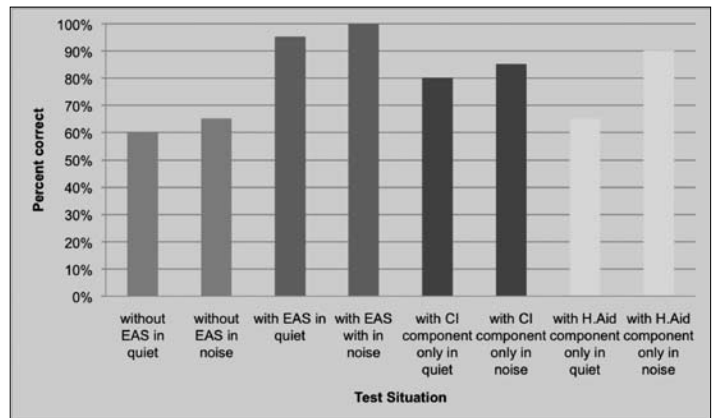



Figure 10. Speech perception scores after EAS surgery (July 25, 2010)*

* Words were presented at 65 dB SPL in quiet and with masking noise at 55 dB SPL at the same ear and SNR of 10. The patient was not wearing a device in the left (non-implanted) ear.



implantation.

It is always important for the otolaryngologist to consider the quality of hearing and quality of life of patients with hearing loss. Intervention should not end with a referral note to a hearing aid center or dispenser. It is important to request proof of improvement not only of hearing thresholds but of speech perception outcomes in quiet and in noise. That is, one should document actual performance with the device in place, regardless of the type of device (hearing aid, an EAS device, or a Cochlear implant). Minimal disturbance of the remaining intact structures of the cochlea of patients with low frequency residual hearing can be achieved by employing a meticulous surgical technique by using the advanced and flexible electrodes developed by some manufacturers and instilling intraoperative antibiotics and steroids. Thus, when one is faced with a ski-slope type audiogram it is likely the patient with this audiogram will not benefit from hearing aids. Such patients should be offered the option of EAS implantation which combines good acoustic stimulation with electric stimulation using a shorter (than conventional cochlear implantation) but very flexible electrode system. Counseling must also be done with a special emphasis on the risk of losing residual hearing and noting that post-operative rehabilitation may take a long period of time. This patient now has a better quality of life than was obtainable from the most expensive and advanced hearing aids in the market, and has demonstrated a new implantable solution to partial deafness. Truly, EAS technology has opened a new era in prosthetic rehabilitation for hearing impaired adults and children.⁵

ACKNOWLEDGMENT

Dr. Maria Rina Reyes-Quintos is gratefully acknowledged for performing all the excellent audiological testing following the surgery while Susan Javier and Angie Tongko of Manila Hearing Aid Center performed all the audiological testing prior to the surgery. Ms. Celina Ann Tobias, Professional Education Manager of Med-El is also credited with thanks for preparing the figures, reviewing the manuscript and interviewing the patient regarding his hearing performance following the surgery.

REFERENCES

1. von Ilberg C, Kiefer J, Tillein J, Pfenningdorf T, Hartmann R, Stürzebecher E, Klinke R: Electro-acoustic stimulation of the auditory system. New technology for severe hearing loss. *ORL J Otorhinolaryngol Relat Spec.* 1999 Nov-Dec;61(6):334-340
2. Gstoeftner WK, van de Heyning P, O'Connor AF, Morera C, Sainz M, Vermeire K *et al.*: Electric acoustic stimulation of the auditory system: results of a multi-centre investigation. *Acta Otolaryng* 2008 Sep;128(9):968-975.
3. Gstoeftner WK, Helbig S, Maier N, Kiefer J, Radeloff A, Adunka OF: Ipsilateral electric acoustic stimulation of the auditory system: results of long term hearing preservation. *Audiol Neurootol* 2006; 11(Suppl 1): 49-56. Epub 2006 Oct 6.
4. Skarzynski H, Lorens A, Piotrowska A, Anderson I. Preservation of low frequency hearing in partial deafness cochlear implantation (PDCI) using the round window surgical approach. *Acta Otolaryngol* 2007 Jan;127(1):41-48
5. Tobias CAM. A New Hearing Solution. Health and Lifestyle Magazine. [serial on the Internet] 2009 December: [cited 2010 September 5] 26-28. Available from <http://healthandlifestylemagazine.wordpress.com/2009/12/12/a-new-hearing-solution/>