

Rhoda Mae V. Boncalon, MD  
Marida Arend V. Arugay, MD  
Rachel Zita H. Ramos, MD

Department of Otorhinolaryngology –  
Head & Neck Surgery  
Western Visayas Medical Center

## A Preliminary Study on the Efficacy of *Plumeria acuminata* (*Kalachuchi*) Bark Extract Ointment Versus Clotrimazole Cream in the Treatment of Otomycosis

### ABSTRACT

**Objective:** To compare the therapeutic efficacy of *kalachuchi* (*Plumeria acuminata* Ait.) bark extract ointment (KO) and clotrimazole cream 1% (CC) in the treatment of otomycosis.

### Methods

**Design:** Randomized double blind controlled trial

**Setting:** Outpatient otorhinolaryngology clinic of a tertiary government hospital

**Subjects:** Patients aged 18-years-old and above diagnosed clinically to have otomycosis with a positive potassium hydroxide (KOH) smear were randomly assigned to *kalachuchi* (*Plumeria acuminata* Ait.) bark extract ointment or clotrimazole cream 1% in unlabeled containers. Self-application thrice daily for two weeks followed initial detailed instructions and demonstration. Symptoms, physical findings and repeat KOH smears were recorded after the first and second weeks of treatment.

**Results:** Eighteen patients with otomycosis were enrolled in the study. There was one dropout per treatment group with no intention to treat. There were no statistically significant differences between KO and CC, with 75% (n=8) and 87.5% (n=8) cure rates, respectively. One subject in the KO arm reported severe ear pain.

**Conclusion:** *Kalachuchi* extract ointment may be a promising topical antifungal agent. Multicenter clinical trials to establish its efficacy and safety as an effective alternative in the management of otomycosis should be conducted.

**Key words:** Otomycosis, *kalachuchi*, *Plumeria acuminata* Ait., clotrimazole, clinical trial, herbal medicine

Philipp J Otolaryngol Head Neck Surg 2009; 24 (1): 5-8

© Philippine Society of Otolaryngology – Head and Neck Surgery, Inc.

Correspondence: Rhoda Mae V. Boncalon, MD  
Department of ENT-HNS  
Western Visayas Medical Center  
Q. Abeto St, Mandurriao, Iloilo City 5000  
Philippines  
Phone: +639177222407  
Fax: (6333) 321 1797  
Email: docboink@yahoo.com  
Reprints will not be available from the author.

Funding support for this study was received from the Research Committee of the Western Visayas Medical Center. The authors signed a disclosure that they have no proprietary or financial interest in any organization that may have a direct interest in the subject matter of this manuscript, or in any product used or cited in this study.

Presented at the Western Visayas Medical Center  
1st Interdepartmental Residents' Research Contest (1st Place),  
WVMC Supply Building, Rooftop, Mandurriao, Iloilo City,  
November 26, 2007; Analytical Research Contest (3rd Place),  
Philippine Society of Otolaryngology - Head and Neck Surgery,  
December 1, 2007 at Romblon Room, Sofitel Philippine Plaza  
Manila, Pasay City, December 1, 2007;  
International Research Conference (West Visayas State  
University) Amigo Terrace Hotel, Iloilo City, February 29, 2008.

**Otomycosis is one of the common otologic** conditions requiring medical consult and therapy. Most otomycosis isolates include *Aspergillus* or *Candida* spp.<sup>1,2</sup> Clinical presentation may include intractable itching of the external auditory canal, otalgia, tinnitus and ear discharge.<sup>3,4</sup> Physical examination reveals an erythematous canal with black, gray or white fungal elements (*Figure 1*). Direct microscopy using 10% KOH confirms the diagnosis.<sup>5</sup> Treatment often requires mechanical cleansing and 1-2 weeks application of topical antifungal agents.<sup>6,7</sup> Clotrimazole 1% cream is commonly prescribed, providing symptom relief within 2 weeks in 96% of patients.<sup>8</sup> Other antifungal drops or powder medications (clotrimazole and nystatin) are also effective in many cases.<sup>9,10</sup>

Of the 10 locally available medicinal plants in the priority list of the Philippine Council for Health Research and Development (PCHRD) of the Department of Science and Technology (DOST) and Plant Resource of South East Asia (PROSEA), **kalachuchi** (*Plumeria acuminata* Ait.) has one of the highest activities in assays against *Candida* species. Antimycotic properties of **kalachuchi** (*Plumeria acuminata* Ait.) bark extract against *Aspergillus flavus* and *Aspergillus niger* have been shown in in-vitro studies.<sup>12</sup> Application of this extract in controlled and limited number of subjects may help establish its pharmacotherapeutic potentials.

The objective of this study was to compare the therapeutic efficacy of **kalachuchi** (*Plumeria acuminata* Ait.) bark extract ointment (KO) and the standard clotrimazole cream 1% (CC) in the treatment of otomycosis.

**METHODS**

**Design:** Randomized double blind controlled trial. The study was reviewed and approved by the ethics committee of the Western Visayas Medical Center.

**Setting:** Outpatient otorhinolaryngology clinic in a tertiary private hospital.

**Subjects:** Voluntary, informed consent was obtained from 18 patients aged 18 to 70 years with otomycosis defined as presence of itchiness, ear pain, ear discharge, ear fullness or hearing impairment with otoscopic findings of external auditory canal erythema, discharge and fungal elements, testing positive on KOH smear were included in the study. Ten percent KOH smears were performed on swabs taken from the affected ear canal. In cases of bilateral otomycosis, the right ear was chosen for evaluation. Exclusion criteria were use of any topical otic medication and/or oral antifungal medication the past 30 days, presence of tympanic membrane perforation, concomitant *otitis media*, previous surgery on the test ear, history of hypersensitivity to clotrimazole and pregnant or lactating patients.

**Intervention:** Following thorough mechanical ear cleansing, patients were randomly assigned to the use of unlabeled containers of either clotrimazole cream 1% in group A or **kalachuchi** (*Plumeria acuminata* Ait.) bark extract ointment in group B. Details of **kalachuchi** bark extract preparation followed those previously described<sup>12</sup> and are

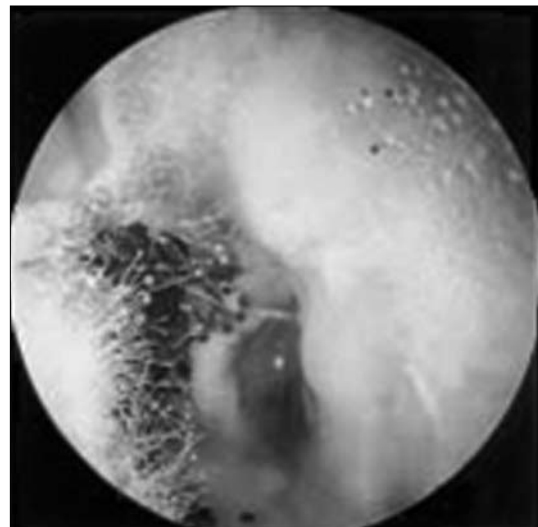



Figure 1. Otoscopy revealing black & white fungal elements



Figure 2. Preparation of **kalachuchi** (*Plumeria acuminata* Ait.) ointment

available through corresponding author (*Figure 2*). A voucher specimen of the said **kalachuchi** was sent to a taxonomist and was positively identified as *Plumeria acuminata* Ait.

After detailed instructions and demonstration, the topical agent was self-applied 3x a day for two weeks. Adverse events were monitored during the two-week treatment period. Patients with localized adverse effects such as hypersensitivity reactions, aural tenderness, formation of eczematous lesions and perichondritis were instructed to discontinue the test drug. Rescue drugs (antihistamines, analgesics or oral antibiotics) were administered to one such patient until events resolved. Patients who developed adverse effects, those with poor compliance to the assigned medication (use of <50% of the test drug) and those who did not wish to continue the treatment were further excluded from the study.



**Outcome Measures and Statistical Analysis:** Clinical symptoms, physical examination findings and KOH smear results were recorded before treatment and at Day 7 and Day 14 of treatment. Comparison between two proportions testing for significant difference was performed using the z-test and chi square test.

## RESULTS

Eighteen patients diagnosed clinically and microbiologically to have otomycosis were initially enrolled in the study comprising 9 test ears in each treatment group. Dropouts included one subject lost to follow up under CC treatment and one subject experiencing severe aural pain and tenderness under KO treatment. Sixteen patients with 8 patients in each treatment arm remained for analysis. These were 7 males and 9 females with a mean average age of 44 years.

The most common presentation of the patients upon consult was ear fullness (75%) and hearing impairment (75%) followed by itchiness of the affected ear (62.5%). On otoscopic examination, all patients had hyphal elements in the test ear. Fifty percent had ear canal erythema and only 34% had ear discharge. There was no significant difference between baseline characteristics of the two groups (Table 1).

After 7 days of treatment, 37.5% of the subjects using CC and 25% of the subjects using KO reported symptom resolution. After two weeks, both groups had an equal incidence of patients (62.5%) who did not report any residual symptoms (Table 2).

After one week of therapy, otoscopic examination revealed normal findings in 62.5% and 32.5% of subjects of the CC and KO groups, respectively. There was no statistically significant difference between the two treatment arms after 7 and 14 days of therapy (Table 2). It must be noted that in this study, the 62.5% response rate to the standard treatment CC requires a 0% response scenario to KO in order to establish a statistically significant difference.

After a week of treatment, only one patient (12.5%) in the KO group had a negative KOH smear while 50% of the CC group already showed absence of fungal elements. After two weeks of therapy, 75% and 87.5% had negative KOH smear for the KO and CC groups, respectively. The difference, however, was again not statistically significant (Table 2).

Mild stinging of the involved ear canal was a common adverse reaction noted especially in the KO treatment. However, the intensity of the stinging was usually tolerable and was not strong enough to cause discontinuation of the treatment. There was only one patient who developed severe aural tenderness on the third day of treatment using KO, which caused her to discontinue the use of the said medication. Other adverse effects were not encountered with either treatment.

## DISCUSSION

With its persistence and annoying symptoms, otomycosis can be a challenging and frustrating disease for both patient and otolaryngologist. With the increasing cost of commercially available antifungal agents, finding locally-available alternative herbal treatments can greatly help

patients, especially the less affluent.

A previous in vitro study of the antifungal activity of four medicinal plants versus clotrimazole in the treatment of otomycosis showed that *kalachuchi* (*Plumeria acuminata* Ait.) bark extract using methylethylketone as solvent at 100% concentration was comparable in efficacy with the standard clotrimazole solution in treating *Aspergillus flavus* and *Aspergillus niger*.<sup>12</sup>

This in vivo trial conducted to further determine the *kalachuchi* (*Plumeria acuminata* Ait.) bark extract's benefit as a topical antifungal agent against otomycosis showed no statistical significant difference between *kalachuchi* (*Plumeria acuminata* Ait.) bark extract ointment and clotrimazole cream 1% in terms of cure and complication rate. The cure rate for KO was 75% compared to 87.5% for CC. The results showed no significant difference between the two treatment groups based on chi-square analysis (Table 3). The failure rate for both treatment groups was relatively low (12.5% and 25%) for CC and KO, respectively (Table 3). This may be due to residual fungal growth in the difficult-to-access antero-inferior recess near the tympanic membrane which may not be reached by topical medications in the form of creams and ointments as well as improper application of the medication. Other preparations for *kalachuchi* extract may need to be explored for ease of application.

While this preliminary study may suggest that KO may be as effective as the CC as an antifungal agent for otomycosis, to compare two proportions testing for efficacy of either treatment, a sample size of at least 88 for each treatment group is needed to test for statistically significant difference, accounting for treatment success in each arm and drop out rates. Complication rates should also be documented to establish the safety of *kalachuchi* bark extract compared to standard treatment. A multicenter study is needed to develop *kalachuchi* extract as an important antifungal agent for otomycosis.

**Table 1. Baseline characteristics of Patients in the Kalachuchi bark extract & Clotrimazole treatment groups**

CHARACTERISTICS	TOTAL NO. OF PATIENTS	FREQUENCY	KALACHUCHI		CLOTRIMAZOLE		p-value
			NO. OF PATIENTS	%	NO. OF PATIENTS	%	
<b>SIGNS &amp; SYMPTOMS</b>							
ITCHINESS	10	62.5%	5	62.5	5	62.5	0.50
EAR PAIN	6	37.5%	3	37.5	3	37.5	0.50
EAR DISCHARGE	4	25%	2	25	2	25	0.50
EAR FULLNESS	12	75%	6	75	6	75	0.50
HEARING IMPAIRMENT	12	75%	6	75	6	75	0.50
<b>OTOSCOPIC FINDINGS</b>							
ERYTHEMATOUS EAC	8	50%	4	50	4	50	0.50
HYPHAL ELEMENTS	16	100%	8	100	8	100	0.50
EAR DISCHARGE	5	34%	3	37.5	2	25	0.29

Critical values:

p-value  $\leq$  0.05 **significant difference**

p-value  $>$  0.05 **no significant difference**

**Table 2. Comparison of the response after 7 days of treatment between Kalachuchi bark extract & Clotrimazole**

CHARACTERISTICS	AFTER 7 DAYS OF TREATMENT					AFTER 14 DAYS OF TREATMENT				
	KALACHUCHI		CLOTRIMAZOLE		p-value	KALACHUCHI		CLOTRIMAZOLE		p-value
	NO. OF PATIENTS	%	NO. OF PATIENTS	%		NO. OF PATIENTS	%	NO. OF PATIENTS	%	
<b>SIGNS &amp; SYMPTOMS</b>										
ITCHINESS	3	37.5	2	25	0.29	2	25	2	25	0.50
EAR PAIN	2	25	1	12.5	0.26	0	0	1	12.5	0.15
EAR DISCHARGE	1	12.5	2	25	0.26	0	0	0	0	-
EAR FULLNESS	5	62.5	3	37.5	0.16	2	25	2	25	0.50
HEARING IMPAIRMENT	5	62.5	3	37.5	0.16	2	25	2	25	0.50
NO SYMPTOMS	2	25	3	37.5	0.29	5	62.5	5	62.5	0.50
<b>OTOSCOPIC FINDINGS</b>										
ERYTHEMATOUS EAC	2	25	2	25	0.50	0	0	0	0	-
HYPHAL ELEMENTS	5	62.5	2	25	0.07	1	12.5	1	12.5	0.50
EAR DISCHARGE	1	12.5	2	25	0.26	1	12.5	1	12.5	0.50
NORMAL FINDINGS	3	37.5	5	62.5	0.16	7	87.5	7	87.5	0.50
<b>KOH SMEAR</b>										
(+)	7	87.5	4	50	0.11	2	25	1	12.5	0.52
(-)	1	12.5	4	50		6	75	7	87.5	

**Critical values:**

p-value ≤ 0.05 **significant difference**  
 p-value > 0.05 **no significant difference**

**Table 3. Comparison of the cure rate between the Kalachuchi bark extract & Clotrimazole treatment**

TREATMENT	CURE		FAILURE	
	NO. OF PATIENTS	%	NO. OF PATIENTS	%
KALACHUCHI	6	75	2	25
CLOTRIMAZOLE	7	87.5	1	12.5
p-value	0.52			

**Critical values:**

p-value ≤ 0.05 **significant difference**  
 p-value > 0.05 **no significant difference**

**ACKNOWLEDGEMENT**

The authors wish to thank Dr. Jose Mari Fermin, Medical Director of Western Visayas Medical Center and its Research Committee for their financial support. Mrs. Monalisa Avanceña and staff of the Western Visayas Medical Center Pathology Department for their help with microbiologic examinations. Dr. Gerard Penecilla of the West Visayas State University Microbiology Laboratory for his help and guidance during the process of *kalachuchi* bark extraction and preparation of *kalachuchi* ointment. Prof. Isabel Blanca for her expertise, time, and service in statistical analysis and the residents of the Department of Otorhinolaryngology Head and Neck Surgery, Western Visayas Medical Center for their support.

**REFERENCES**

1. Geaney GP. Tropical otomycosis. *J Laryngol Otol.* 1967; 81: 987-97.
2. Lakshmi pati G, Murti RB. Otomycosis. *J Indian Med Assoc.* 1960; 34:439-41.
3. Paulose KO, Al Khalifa S, Shenoy P, Sharma RK. Mycotic infection of the ear (otomycosis): A prospective study. *J Laryngol Otol.* 1989; 103:30.
4. Than KM, Naing KS, Min M. Otomycosis in Burma and its treatment. *Am J Trop Med Hyg.* 1980; 29:520.
5. Mathur MD. Otomycosis: A clinicomycologic study. *ENT J.* 2000 ;79:606-9.
6. Ballantine J, Groves J. *Scott-Brown's Diseases of the Ears, Nose and Throat.* Boston : Butterworths, 4th ed., 93-114.
7. Patow CA. Fungi as a cause of otitis. *J Am Med Assoc.* 1995 ; 273 (1):25.
8. Ologe FE, Nwabuisi C. Treatment outcome of otomycosis in Ilorin, Nigeria. *West Afr J Med.* 2002; 21(1):34-36.
9. Kwok P, Hawke, M. Clotrimazole powder in the treatment of otomycosis. *J Otolaryngol.* 1987; 16:398.
10. Stern JC, Shah MK, Lucente FE. In vivo effectiveness of 13 agents in otomycosis and review of the literature. *Laryngoscope.* 1988; 98:1173.
11. Penecilla G, Magno C, de Castro J. et al. Production and testing of natural products for antimicrobial and antifungal action. *West Visayas State University College of Arts and Sciences Research Journal.* 2001; 2 (1):10-20.
12. Villanueva JM, Arugay MAV, Ramos RZH. In vitro antimycotic activity of four medicinal plants versus Clotrimazole in the treatment of otomycosis: a preliminary study. *Philipp J Otolaryngol Head Neck Surg* 2008; 23(1): 5-8.
13. *Plumeria acuminata* Ait. Republic of the Philippines, Department of Agriculture, Bureau of Plant Industry.