



Jan Paul D. Formalejo, MD
Jay Pee M. Amable, MD

Department of Otorhinolaryngology
Head and Neck Surgery
University of the East – Ramon Magsaysay Memorial
Medical Center, Inc.

Correspondence: Dr. Jay Pee M. Amable
Department of Otorhinolaryngology
Head & Neck Surgery
Rm. 463, Hospital Service Bldg., UERMMMC, Inc.,
64 Aurora Blvd., Quezon City 1113
Philippines
Telephone: +632-7150861 loc. 257
Telefax: +632-7161789
E-mail: jpamablemd@gmail.com

The authors declare that this represents original material that is not being considered for publication or has not been published or accepted for publication elsewhere in full or in part, in print or electronic media; that the requirements for authorship have been met by the author, and that the author believes that the manuscript represents honest work.

Disclosures: The authors signed a disclosure that there are no financial or other (including personal) relationships, intellectual passion, political or religious beliefs, and institutional affiliations that might lead to a conflict of interest.

Presented at the Philippine Society of Otolaryngology Head and Neck Surgery Interesting Case Contest (1st Place), May 12, 2018. Citystate Asturias Hotel, Puerto Princesa, Palawan.



Creative Commons (CC BY-NC-ND 4.0)
Attribution - NonCommercial - NoDerivatives 4.0 International

Non-Traumatic Cerebrospinal Fluid Leak from a Sphenoid Sinus Midline Roof Defect Previously Managed as Allergic Rhinitis

ABSTRACT

Objective: To present a case of a non-traumatic cerebrospinal fluid (CSF) rhinorrhea from a midline sphenoid sinus roof that presented as a persistent postnasal drip and was previously managed as allergic rhinitis for 43 years.

Methods:

Design: Case Report
Setting: Tertiary Private University Hospital
Participants: One

Results: A 58-year-old obese and hypertensive man presented with persistent post nasal drip and intermittent clear watery rhinorrhea. He had been managed as a case of allergic rhinitis for 43 years and was maintained on nasal steroid sprays without relief. Nasal endoscopy revealed pulsating clear watery discharge from the sphenoid ostium. On trans-sphenoidal surgery, a midline sphenoid sinus roof defect was sealed using a Hadad-Bassagasteguy flap.

Conclusion: CSF rhinorrhea is uncommon and may mimic more common diseases such as allergic rhinitis. Because misdiagnosis can then lead to life threatening complications, physicians should be vigilant when seeing patients with clear watery rhinorrhea to be able to arrive at a proper diagnosis and provide prompt treatment.

Keywords: *cerebrospinal fluid rhinorrhea; cerebrospinal fluid leak; sphenoid sinus midline roof defect*

Cerebrospinal fluid (CSF) leaks are uncommon with most cases due to traumatic causes (iatrogenic or head injury) accounting for 80% of all CSF rhinorrhea.¹ Spontaneous CSF rhinorrhea is even more uncommon accounting for only 4% of all CSF leaks.¹ There is limited clinical data available regarding CSF rhinorrhea.¹ Patients can be mismanaged when they only present with clear watery rhinorrhea and no other associated symptoms. This may result in life threatening complications such as meningitis or brain abscess if not addressed appropriately.¹ We report a case of a non-traumatic cerebrospinal fluid leak in a hypertensive obese man with a 43-year history of post nasal drip and clear watery rhinorrhea.

CASE REPORT

A 58-year-old obese, hypertensive man who had no previous history of surgery or trauma presented with persistent post nasal drip and intermittent clear watery rhinorrhea. The postnasal drip started 43 years prior to admission, accompanied by intermittent clear watery rhinorrhea especially when he would lean forward. Multiple physicians managed this as a case of allergic rhinitis and he was maintained on various of nasal steroid sprays without relief.

These symptoms persisted until 2 months prior to admission when the patient experienced headache, fever and decrease in sensorium. Admitted at a local hospital with an impression of meningitis, a possible CSF leak was considered. His rhinorrhea revealed an elevated glucose level. Other laboratory tests were normal. The patient was discharged after 2 weeks of antibiotics and advised to consult a neurosurgeon.

A month prior to admission, recurrence of fever, headache and decrease in sensorium prompted readmission for meningitis and antibiotic therapy. A computed tomography (CT) scan showed a non-communicating hydrocephalus and polysinusitis with soft tissue densities in the ethmoid and sphenoid sinuses. (Figure 1) Magnetic resonance imaging (MRI) showed expansion of the pituitary fossa, associated with a crescent-shaped hypoenhancing soft tissue material involving the infrasellar region and the left parasellar region. (Figure 2) The patient was eventually discharged and was advised to undergo repair of the CSF leak.

He consulted a Neurosurgeon 1 week before admission. A repeat CT scan showed abnormal widening of the sella turcica, thinning of the clivus with destruction of the left parasellar margins and inferior wall of the left sphenoid sinus, abnormal fluid collection in the left sphenoid sinus with near-CSF attenuation, and a bone defect on the sphenoid roof. (Figure 3) The patient was referred to our service and nasal endoscopy showed pulsating clear watery discharge from the left sphenoid ostium. (Figure 4)

The patient was admitted for endoscopic transsphenoidal repair of the CSF leak. Intraoperatively, edema of the sphenoid mucosa was noted. (Figure 5A) Upon stripping of the mucosa, there was a well-defined circular hole in the sphenoid sinus wall. The hole extended superiorly consistent with the CT scan image. (Figure 5B) Cerebrospinal fluid was noted to be pulsating out of the dura. Inspection of the lateral sphenoid sinus was unremarkable. The defect was repaired using a Hadad-Bassagasteguy flap. (Figure 6) Repeat nasal endoscopy 16 days after surgery revealed the flap in place and no CSF leak. (Figure 7)

DISCUSSION

Cerebrospinal fluid leak is caused by a direct communication between the subarachnoid space and the mucosa of the paranasal

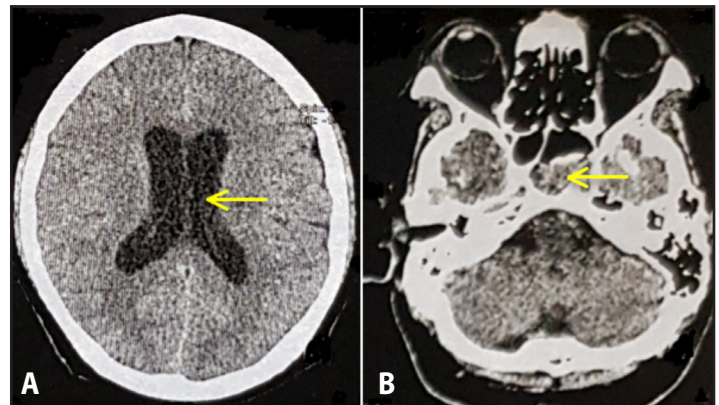


Figure 1. Plain Cranial CT Scan. A. Non-communicating hydrocephalus (arrow). B. Polysinusitis involving the sphenoid (arrow).

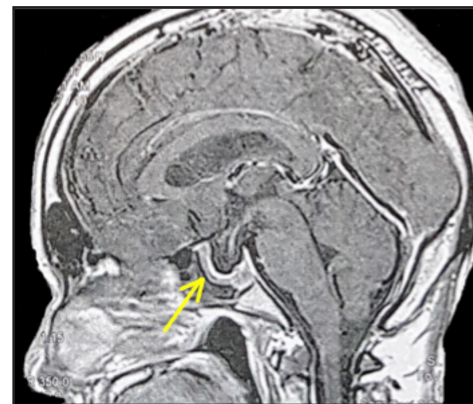


Figure 2. Cranial MRI with contrast, midsagittal view. Note expansion of the pituitary fossa with crescent shaped hypoenhancing soft tissue material (arrow).

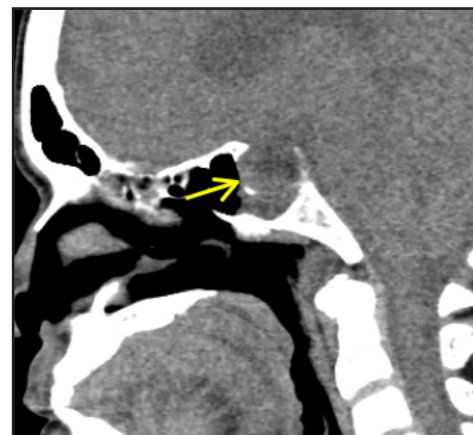


Figure 3. Cranial CT scan with contrast, midsagittal view. There is absence of bone on the sphenoid roof (arrow).

sinuses.¹ The first report of CSF leak was from the time of Galen in 200 B.C. when they thought that this was a physiologic phenomenon.² It was only in 1899 when Thomson noted that CSF leak is an abnormal phenomenon in a series of 21 cases coining the term “cerebrospinal rhinorrhea.”³ The largest case series of CSF leak reported 161 cases, of which only 5% were idiopathic.^{2,4}

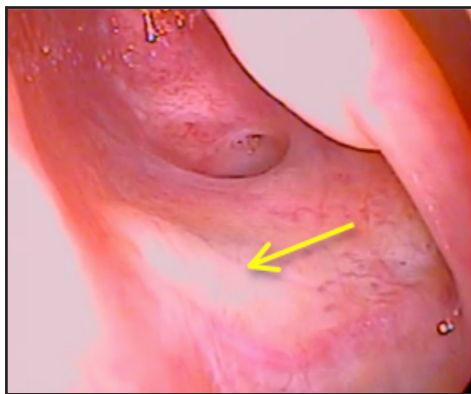


Figure 4. Preoperative Nasal Endoscopy. Arrow shows a wave of clear fluid coming from the sphenoid ostium.

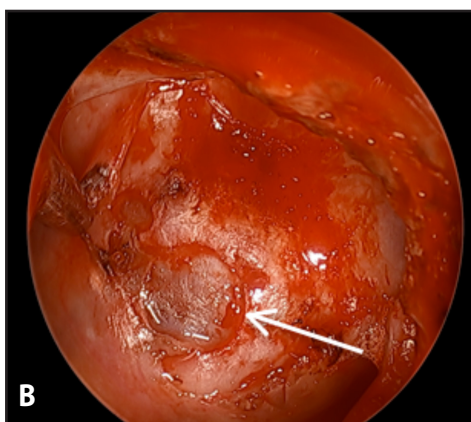
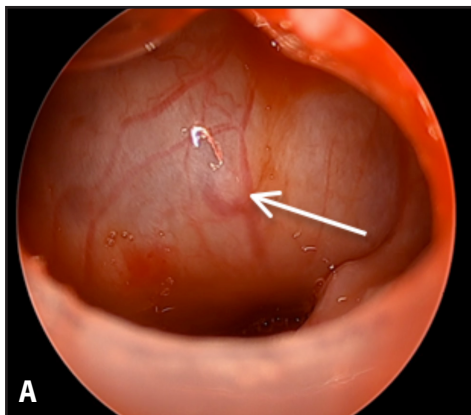


Figure 5. Intraoperative findings. **A.** Edematous sphenoid sinus mucosa (arrow). **B.** Hole in the sphenoid sinus wall after mucosal stripping (arrow).

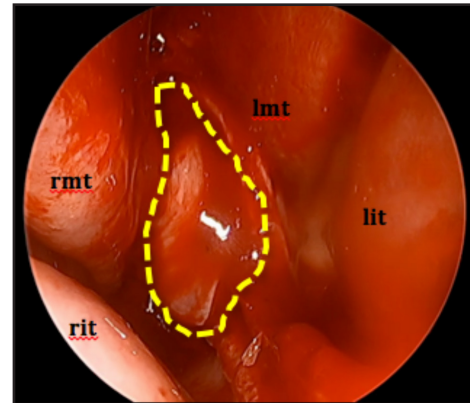


Figure 6. Hadad-Bassagasteguy flap (broken lines), right middle turbinate (rmt), right inferior turbinate (rit), left middle turbinate (lmt), left inferior turbinate (lit).

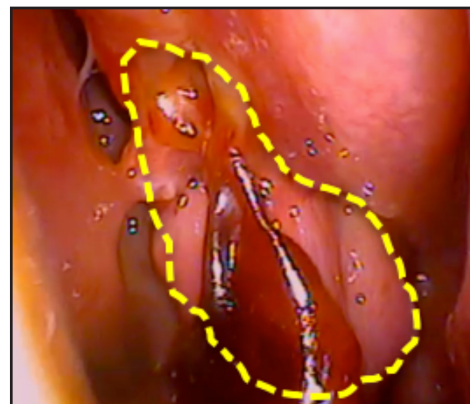


Figure 7. Hadad-Bassagasteguy flap 16 days after surgery (broken lines)

The usual profile of a patient with spontaneous CSF rhinorrhea is an obese, hypertensive female who has no history of head trauma or surgery.^{2,5} Our patient was an obese, hypertensive male with no history of head trauma or surgery. Also, CSF leak usually presents as a clear watery rhinorrhea.² However, the clinical presentation of our patient was mostly postnasal drip. The patient would only have watery rhinorrhea whenever he would lean forward.

What was also interesting was that our patient was previously managed as a case of allergic rhinitis for 43 years. He was only treated repeatedly with nasal sprays. CSF rhinorrhea can have fatal consequences when not treated appropriately. It can lead to meningitis and intracranial infections as was the case with our patient. It was only when the patient presented with meningitic symptoms that the possibility of a CSF leak was investigated. The patient already had two episodes of meningitis when the CSF leak was diagnosed.

Diagnosis of CSF leak is confirmed by the presence of CSF and localization of the skull base defect.¹ Confirmation of the presence of CSF leak is ideally done using β -2 transferrin or β trace protein.¹ Glucose testing may also be done however there are cases of false positives and false negatives.¹ Localization of the skull base defect may be done through CSF tracers via CT, MR cisternography and nasal endoscopy after intrathecal tracer fluorescein.¹ However in case reports of spontaneous CSF leak, diagnosis is mostly made through nasal endoscopy, CT scan and MRI.^{2,6} In some case reports, the CSF leak was an incidental finding during transsphenoidal surgery for sellar masses.⁷ The CSF leak was



confirmed in our patient using glucose testing. Repeat CT scan of the patient also noted a bone defect in the roof of the sphenoid sinus. Nasal endoscopy also revealed a pulsating clear watery discharge from the sphenoid ostium.

In our patient, the defect was found in the midline sphenoid sinus roof. This is a rare location of CSF leak.⁶ The defect was a well-defined circular hole in the wall of the sphenoid sinus. Traumatic CSF leaks do not usually create a defect that well-defined.

The exact etiology of non-traumatic CSF leaks is still unclear. There are studies that point to increased intracranial pressure (ICP). Benign intracranial hypertension (BIH) or *pseudotumor cerebri* is a syndrome of increased ICP in the absence of specific causes such as intracranial masses, hydrocephalus and dural sinus thrombosis.¹ Clinical manifestations include headache, pulsatile tinnitus, papilledema and visual disturbances.¹ Pulsatile increased hydrostatic pressure is capable of bone erosion during the course of many years.⁶ Another syndrome implicated in non-traumatic CSF leak is empty sella syndrome.⁸ The postulated mechanism of CSF leak from empty sella is basically the same as benign intracranial hypertension which is increased ICP that can eventually cause progressive bone erosion.⁸ However, we can rule out empty sella syndrome as our patient had a normal-appearing pituitary on MRI. Hydrocephalus is a condition in which there is an accumulation of CSF in the brain.¹ This typically causes increased ICP and could also cause CSF leak.⁶ However, there were no signs of hydrocephalus in our second CT scan. Intracranial neoplasm can cause CSF leak in two ways. It can cause a direct invasion to the sinuses thus creating a CSF leak. Another is through increased intracranial pressure.⁹ In our case, there was no imaging evidence of an intracranial neoplasm. Non-traumatic CSF rhinorrhea can also be idiopathic when all other causes have been ruled out.¹ Having ruled out other causes, our patient may have had an idiopathic case of CSF rhinorrhea.

Our patient had no headache, pulsatile tinnitus, papilledema or visual disturbances. However, patients who have CSF rhinorrhea would be asymptomatic even if they have benign intracranial hypertension due to the CSF leak acting as a pressure valve that releases pressure.⁶ Pressure measurement using lumbar puncture would also yield normal results because of this phenomenon.⁶ Postoperatively, the patient should present with benign intracranial hypertension since the defect that acts as a valve pressure has been closed. However, our patient did not present with postoperative papilledema, headache and visual disturbances. Furthermore, the postoperative increase in ICP can cause failure of flap closure. Postoperative follow up after 1 month showed an intact flap and the patient was asymptomatic.

Our patient underwent endoscopic transsphenoidal repair of the CSF leak using a Hadad-Bassagasteguy flap. Endoscopic management is the

primary technique for surgical management of skull base defects.^{1,6,11} Hadad *et al.*¹⁰ first described the use of a neurovascular pedicled flap of the nasal septum mucoperiosteum and mucoperichondrium based on the nasoseptal artery, a branch of the posterior septal artery. They coined the term Hadad-Bassagasteguy flap for this type of reconstructive technique.¹⁰ This technique has decreased the rate of CSF leak post operatively from >20% to only 5%.^{10,11} A recent prospective study involving 53 patients who underwent Hadad-Bassagasteguy flap reconstruction showed only 3.8% rate of CSF leak post operatively.¹² A Hadad-Bassagasteguy flap therefore is an efficient technique in repairing CSF leak defects with low recurrence of CSF leak. Postoperatively our patient has no recurrence of CSF leak. The patient underwent repeat nasal endoscopy after 16 days post surgery. There was no noted CSF leak and the Hadad flap was in place.

In conclusion, CSF rhinorrhea is uncommon and physicians may tend not to consider a diagnosis of CSF leak. Because the presentation of CSF leak can mimic that of more common diseases such as allergic rhinitis, patients can be easily misdiagnosed. A misdiagnosis of CSF leak can lead to life threatening complications and physicians should be vigilant when seeing patients with clear watery rhinorrhea to be able to arrive at a proper diagnosis and provide prompt treatment.

REFERENCES

- Citardi M, Samer F. Cerebrospinal Fluid Rhinorrhea In Flint P, Haughney B, Lund V, Niparko J, Robbins T, Regan T et al, editors. Cummings Otolaryngology Head and Neck Surgery. 6th ed. Philadelphia City: Elsevier; 2015. 803-815.
- Darouassi Y, Mliha Touati M, Chihani M, Akhaddar A, Ammar H, Bouaity B. Spontaneous cerebrospinal fluid leak of the sphenoid sinus mimicking allergic rhinitis, and managed successfully by a ventriculoperitoneal shunt: a case report. *J Med Case Rep.* 2016 Nov 3; 10(11): 308. DOI: 10.1186/s13256-016-1107-0; PMID: 27809892 PMCID: PMC5094058.
- Thomson S. The Cerebrospinal Fluid. Its Spontaneous Escape from the Nose. With Observations on Its Position and Function in the Human Subject. *The Journal of Nervous and Mental Disease.* 1900 Feb; 27(2):125.
- Schick B, Weber R, Mosler P, Keerl R, Draf W. Long-term follow up of fronto-basal dura-plasty. *HNO.* 1997;45(3):117-22.
- Kortbus MJ, Roland JT, Lebowitz RA. Sphenoid sinus cerebrospinal fluid leak: Diagnosis and management. *Operative Techniques in Otolaryngology-Head and Neck Surgery.* 2003 Sep;14(3):207-211. DOI: [https://doi.org/10.1016/S1043-1810\(03\)90027-3](https://doi.org/10.1016/S1043-1810(03)90027-3).
- Schuknecht B, Simmen D, Briner HR, Holzmann D. Nontraumatic skull base defects with spontaneous CSF rhinorrhea and arachnoid herniation: imaging findings and correlation with endoscopic sinus surgery in 27 patients. *Am J Neuroradiol.* 2008 Mar; 29(3): 542-549. DOI: 10.3174/ajnr.A0840; PMID: 18079185.
- Ntsambi-Eba G, Fomekong E, Raftopoulos C. Spontaneous submucosal sphenoidal fistula discovered intraoperatively: A case report. *Neurochirurgie.* 2014 Oct; 60(5): 262-264. DOI: 10.1016/j.neuchi.2014.02.009; PMID: 24856048.
- Schlosser R, Bolger W. Significance of Empty Sella in Cerebrospinal Fluid Leaks. *Otolaryngology-Head and Neck Surgery.* 2003;128(1):32-38.
- Pérez M, Bialer O, Bruce B, Newman N, Biousse V. Primary Spontaneous Cerebrospinal Fluid Leaks and Idiopathic Intracranial Hypertension. *Journal of Neuro-Ophthalmology.* 2013;33(4):327-334.
- Hadad G, Bassagasteguy L, Carrau RL, Mataza JC, Kassam A, Snyderman CH, et al. A novel reconstructive technique after endoscopic expanded endonasal approaches: vascular pedicle nasoseptal flap. *Laryngoscope.* 2006 Oct; 116(10):1882-1886. DOI: 10.1097/01.mlg.0000234933.37779.e4; PMID: 17003708.
- Brunworth J, Lin T, Keschner DB, Garg R, Lee JT. Use of the Hadad-Bassagasteguy flap for repair of recurrent cerebrospinal fluid leak after prior transsphenoidal surgery. *Allergy Rhinol (Providence).* 2013 Fall; 4(3): e155-161. DOI: 10.2500/ar.2013.4.0072; PMID: 24498521 PMCID: PMC3911805.
- Singh C, Shah N. Hadad-Bassagasteguy flap in reconstruction of skull base defects after endonasal skull base surgery. *International Journal of Otorhinolaryngology and Head and Neck Surgery.* 2017;3(4):1020.