

1989

Property of:
Phil. Society of Otolaryngology-
Head & Neck Surgery, Inc.
Unit 2512, 25/F, Medical Plaza Ortigas,
San Miguel Ave., Ortigas Ctr., Pasig City
Tel.: 633-2783, 633-8344, 0920-906-6652
Code No.: *JOMH-1989*

The Philippine Journal of

OTOLARYNGOLOGY — HEAD & NECK SURGERY

Editor's Note
President's Page
*List of PSO-HNS Officers/
PSO-HNS Financial Report*
*Microscopic Endolaryngeal
Arytenoidectomy*
*Globus Hystericus--A Joke
No More*
The 401st Option
*Malar Swelling: A Long
Distance Affair*
*Three-In-One Standby
Operating Room Unit*
*Peritonsillar Abscess:
Recurrence Rates Following
Incision and Drainage*
*Atrophic Rhinitis: Clinical
and Histologic Response to
Topical Conjugated Estrogen
10, 20, 30 What Is It Really?*
*"Akala Ko Luga Lang" Mother's
Myth, Child's Malady*
*A Bloody Dilemma Juvenile
Nasopharyngeal Angiofibroma*
Unclassified Cleft
*Endoscopic Sinus Surgery: UST
Experience (Review of 39 Cases)*
A Benign and Malignant Ear
*Mastoid Cavity Dimensions Among
Filipinos: Its Surgical Relevance*
*Anatomy of the Middle Ear Among
Filipinos Considered from the
Viewpoint of the Current Trends
in the Rehabilitation of the Deaf*
A Locally Made Temporal Bone Holder
Temporal Bone Dissection Course



Publication of the Philippine Society of
Otolaryngology-Head and Neck Surgery, Inc.

*Property of PSC-HNS, INC.
Unit 2512, 25/F, Medical Plaza Ortigas,
San Miguel Ave., Ortigas Ctr., Pasig City
Tel.: 633-2783, 633-8344, 0920-906-6652
Code No.: JOURNAL . 009*

THE PHILIPPINE JOURNAL OF OTOLARYNGOLOGY
HEAD AND NECK SURGERY

THE EDITORIAL STAFF

Eusebio Llamas, M.D.	Editor-in-Chief
Alfredo Pontejos, M.D.	Assistant Editor
Carlos Reyes, M.D.	Managing Editor

BOARD OF EDITORS

Vicente Chiong, M.D.	Head & Neck Tumor Surgery
Manuel Lim, M.D.	Otology
Mariano Caparas, M.D.	Maxillofacial Surgery
Teodoro Llamanzares, M.D.	Rhinopharyngology
Remigio Jarin, M.D.	Reconstructive & Plastic Surgery
Milagros Lopez, M.D.	Bronchoesophalogy & Laryngology
Carlos Reyes, M.D.	Audiology & Neuro-Otology

All manuscripts and other editorial matter should be addressed to Eusebio Llamas, M.D., Editor-in-Chief, The Philippine Journal of Otolaryngology - Head and Neck Surgery, Department of Otolaryngology, Santo Tomas University Hospital, Suite 208.

CONTENTS

Editor's Note	Page 4
President's Page	5
List of PSO-HNS Officers/PSO-HNS Financial Report	8
Microscopic Endolaryngeal Arytenoidectomy by Drs. Ellen Y. Ng, William Lim, Norberto Martinez and Milagros S. Lopez	9
Globus Hystericus--A Joke No More by Dr. Eduardo C. Yap....	14
The 401st Option by Dr. Emmanuel S. Samson	17
Malair Swelling: A Long Distance Affair by Dr. William L. Lim	20
Three-In-One Standby Operating Room Unit by Drs. Pio R. Pajarillo, Bernardo D. Dimacali, and Charlotte M. Chiong	24
Peritonsillar Abscess: Recurrence Rates Following Incision and Drainage by Drs. Bernardo Dimacali, Romualdo Aragon, Jr., Ruzanne Caro, and Natividad Aguilar	27
Atrophic Rhinitis: Clinical and Histologic Response to Topical Conjugated Estrogen by Drs. Teresa Paz B. Garcia, Romualdo Aragon, Jr., Cesar Anthony Yabut, and Joselito Jamir	31
10, 20, 30 What Is It Really? by Dr. Arsenio L. Pascual III	41
"Akala Ko Luga Lang" Mother's Myth Child's Malady by Drs. Eusebio E. Llamas and Benjamin S.A. Campomanes, Jr.	44
A Bloody Dilemma Juvenile Nasopharyngeal Angiofibroma in a Female: A Case Report by Drs. Elmo R. Lago, Alejandro P. Oplencia, and Teodora P. Llamanzares	47
Unclassified Cleft by Drs. Liberty Acedillo-Monleon, Abelardo Perez, and Robie Zantua	51
Endoscopic Sinus Surgery: UST Experiences (Review of 39 Cases) by Drs. Benjamin S.A. Campananes, Jr., and Eusebio E. Llamas	57
A Benign and Malignant Ear by Dr. Leonardo D. Wee	61
Mastoid Cavity Dimensions Among Filipinos: Its Surgical Relevance by Drs. Norberto Martinez, Leopoldo Uichanco, Eric Nubla, William Lim, Ellen Ng, and Daniel Alonzo	68
Anatomy of the Middle Ear Among Filipinos Considered from the Viewpoint of the Current Trends in the Rehabilitation of the Deaf by Drs. Abelardo Perez and Robie V. Zantua	79
A Locally Made Temporal Bone Holder by Drs. Norberto V. Martinez, Daniel M. Alonzo, Ellen Y. Ng, and William L. Lim	82
Temporal Bone Dissection Course	85

Editor's Note

Immortality in Print

Nine years ago, the maiden issue of the Philippine Journal of Otolaryngology - Head and Neck Surgery created a ripple in the country's circle of scientific publications. For the first time in its twenty-five years of existence, the society had the opportunity to attain "immortality in print." Whereas interesting cases, researches, and experiences by our mentors were more often than not lost to oblivion, the journal serves as a goldmine, a repository of knowledge that can be shared and passed on to colleagues.

From its beginnings, the official publication of the society has been nurtured and cared for by the Father of the Philippine Journal of Otolaryngology - Head and Neck Surgery, Dr. Angel Enriquez. Every year since 1981, I remember in awe as to how this man would constantly remind the consultants and residents to submit their papers for publication. And when his "baby" finally came out fresh from the press, the editor-in-chief, with fervent enthusiasm, transformed into the advertiser, distributor, and newsboy rolled into one.

In this ninth issue, we dedicate and pay tribute to the man who had dreamed and envisioned the publication, for without which our residents and consultants may never experience this touch of relative immortality. We salute and congratulate Dr. Angel Enriquez and his staff for giving us nine years of worthwhile literature. We hope that in the following publications we can at least equal, if not surpass, the works laid down by the previous editorial staff.

Eusebio Llamas, MD

THE PRESIDENT'S PAGE

In a relatively small and young society such as the Philippine Society of Otolaryngology — Head and Neck Surgery, it is not really that difficult to get into the top of the pinnacle. As one of our past presidents aptly remarked, "Just stick around in all its functions, show genuine concern for the welfare of the society and its members, flavor it with a pinch of leadership and soon you will get the mandate of your colleagues and of course a chance to inject your own policies and ideas. Perhaps even improve on the previous leadership notwithstanding the flawlessness the society was ran by the former presidents. In short, to contradict the words of Shakespeare, I will, as your new president, attempt to "improve on a masterpiece."

Allow me to briefly observe with you this evening the progress, pitfalls, and heartaches of our specialty, particularly in the local setting. Just like any successful endeavor, it has endured the slings and arrows of professional suspicions and jealousies from members of other specialties whose interest is in the same region of the human body as ours.

We are accused of sticking our fingers into all aspects of head and neck surgery by the very people who admit that they being generalists, a special training of a few more years are needed to become a full pledged head and neck surgeon.

Our knowledge of head and neck diseases and its management was not the result of the ear, nose, and throat being in the region but logically because of the natural pathophysiology of the diseases particularly the biology of tumors in this organ system. Just as we expect a heart surgeon to have mastered the hemodynamics of the cardiopulmonary system whenever he operates on the heart so too an otolaryngologist is expected to manage, let's say, an advance stage of cancer of the larynx, its regional spread, the options available to manage it, and the subsequent reconstruction of the defect his surgery might have created.

Our specialty therefore has gone a long way since the time it was popularly known as EENT which seemed more like a package deal offering to the patient but in reality is more ophthalmologic expertise rather than otolaryngologic knowledge. A little knowledge is of course dangerous so much so that our national hero, Dr. Jose Rizal, practiced good ophthalmology but never touched otolaryngology. So much so that the Founding Fathers of this society, in its desire to start competent ENT practice in the country, formed the nucleus of what is then known as the Philippine Society of Otolaryngology and Bronchoesophagology, exactly 33 years ago this 17 February. They were known as the "Heroic 9" for they were brave enough to declare independence from a domineering mother society known as the POOS. My major role as your new president therefore will be to get rid of all these misconceptions about us.

The first step to be taken will be a revision of our By-laws which unfortunately did not go hand in hand with the progress of the organization. It still retains the old name -- Philippine Society of Otolaryngology and Bronchoesophagology; has restricted membership to American Board certified and eligibles, and has lagged behind the economic picture of the times so as to charge a measly P75 per member per year. But in revising the Constitution we should not fall into the same mistake which our American colleagues did two years ago when they

changed the name of the American Board of Otolaryngology and Head and Neck Surgery making them a target of ridicule for people in the neurological, ophthalmological and even dental sciences who rightfully belong to the same region. The Greek word 'otolaryngology' is our time honored badge just as the head mirror and the tuning are the indispensable figures in our logo. Therefore it should not be stricken out of our title. As a corollary to this, I hereby create a committee for the revision of our By-Laws and I will designate as chairman Dr. Mariano Caparas, a former president of the society, and the incumbent president of the ASEAN Otolaryngologic Federation.

The next step will be the basic approach to the problem and that is to establish an independent policy making Department of Otolaryngology and Head and Neck Surgery in all medical schools where logically it should originate if we are to inculcate in the minds of our future doctors that otolaryngology is a distinct entity in the medical curriculum. For this I appreciate the open mindedness and candidness of our guest of honor tonight, Dean Joven Cuanang (and that of our distinguished guest Dr. Raul Fores) who after listening to the pros and cons of creating a separate ENT department, finally agreed to establish such in their own institutions, the UERM College of Medicine (and the Makati Medical Center). To date, our Accreditation Committee has approved seven residency training programs, all in Metro Manila, four out of these belong to medical schools, a poor 15% of the total 26 medical schools in the country. The proper channel of communications therefore should be with the Association of Deans of Medical Schools and Colleges and I take this opportunity to request Dean Cuanang to help pave the way for this endeavor. And for this purpose, I will form an ad hoc committee to bridge the gap between us.

The third priority will be to create a healthy dialogue out of our many scientific meetings and symposia wherein experts in other fields particularly the other surgical specialties will be invited as speakers, reactors, or plain guests so these individuals will realize how far and how sophisticated we have gone in the realm of ENT-head and neck surgery.

If funds will allow or sponsors available and through the office of the Honorable PMA President, Dr. Santiago del Rosario, sorties to the provinces without ENT specialists by our members who may even perform wet clinics, will also be arranged with the organizing host. This is definitely not self-serving alone but a sort of outreach program to help our overworked provincial doctors who do not even have the time to read and update themselves in the field.

And to make the task more realistic, I implore our young colleagues with roots in the provinces to visit and explore the possibility of practicing back home and experience the satisfaction of sharing your ability with the community which can never be realized materially. Don't go back when your fingers cannot even grasp a tissue forceps because of tremors or when you cannot even remember the generic equivalent of Ponstan or Tylenol. Lest you forget, the trail has already been blazed by people like Drs. Carlos Dumlao and Edwin Cosalan of Baguio City, Zeh Wi of Pangasinan, Leonardo Mangahas of Tarlac, Resty Gorosin and Rudy de la Cruz of Iloilo, Dr. Dosdos of Cebu, Manny Tan of Davao, Bla Pajaro of Cotabato, and Apollo Garcia of Zamboanga. Let's hope that their tribe will increase in the years to come. And for those who elect to practice in the urban areas, may I remind you to always stick to the proper indications defined for each specific surgical procedure and not be influenced by a fancy life style or the need for a new house or perhaps a new car. Remember that one rotten apple can destroy the rest in the basket.

The night, ladies and gentlemen, will not be self-fulfilling without looking back with awe at the accomplishments of the previous presidents of both the society and the board. To Dr. Siu Chuan Leh, immediate past president of the society, credit is hereby given for an unprecedented number of quality scientific meetings and symposia, seven in all in 1988 alone. He had to pitch-in financially because we ran out of sponsors. And to Dr. Nap Ejercito, immediate past president of the board, credit is likewise due for maintaining the high standards of otolaryngology practice in the country through the traditionally but reasonably rigid board examinations. And to Dr. Angel Enriquez, the outgoing Editor-in-Chief of the only journal in ENT-head and neck surgery in the country, your erudite editorials have stimulated all the members to contribute excellent articles.

To the Founding Fathers, the "Heroic Nine", some of whom are here tonight to honor the occasion, rest assured that the standards you aimed for for the society 33 years ago will not go to waste.

And finally to my fellow officers: the road to success in running the organization will be realized only by imploring the help of the Almighty Physician and by putting our acts together.

PHILIPPINE SOCIETY OF OTOLARYNGOLOGY - HEAD AND NECK SURGERY, INC.

OFFICERS 1989-1990

President: TEODORO LLAMANZARES, MD Vice-President: EDILBERTO JOSE, MD

Secretary: ALFREDO Q.Y. PONTEJOS, JR., MD Treasurer: ROBIE V. ZANTUA, MD

PRO: JACOB S. MATUBIS, MD

Board of Directors: DOMINADOR ALMEDA, MD CARLOS DURLAO, MD
SIU CHUAN LEH, MD LEONARDO MANGAHAS, JR., MD
FELIX NOLASCO, MD ANGEL ENRIQUEZ, MD (Ex-Officio)

PSO-HNS FINANCIAL REPORT
AS OF 7 DECEMBER 1988

Receipts:

Beginning Cash	₱ 896.42
Annual Dues	15,000.00
Accreditation Fees	2,500.00
Share from 3rd ASEAN Congress	12,775.42
Interest in Bank	142.46
Total	₱31,314.30

Less Expenses:

Representation (meetings)	4,784.42
Secretary's Stipend (Jan-Sep)	1,800.00
Telegram	976.85
Messengerial	337.00
Mail	142.00
Plaque	4,180.00
Xerox	264.30
IFOS Annual Dues	1,555.00
Supplies	91.95
Bank Charges	138.00
Miscellaneous	330.00
Withholding Tax	16.55
Total	<u>14,616.07</u>

CASH AT END ₱16,698.23

Submitted by: DR. ROBIE V. ZANTUA
Treasurer

MICROSCOPIC ENDOLARYNGEAL ARYTENOIDECTOMY*

Ellen Y. Ng, MD, William Lim,
MD, Norberto V. Martinez, MD,
Milagros S. Lopez, MD

Abstract

Bilateral recurrent nerve paralysis is one of the most distressing maladies which can happen to an individual. Fortunately, immediate relief can be obtained through a tracheostomy. However, patient develops a distinct aversion to the tracheal stoma and are willing to trade the risk of a surgical procedure for the opportunity to eliminate the tube. This paper presents 4 case reports wherein surgical correction of bilateral recurrent nerve paralysis using microscopic endolaryngeal arytenoidectomy has been applied. It has proved reliable, easy to perform, with no major complications, and an alternative to patients who opt to undergo a lesser surgical procedure.

Introduction

Bilateral recurrent nerve paralysis is one of the most distressing maladies which can happen to an individual. The agonizing moments of gasping for air create confusion, panic, and utmost fear. The anxiety of total breathlessness should the glottis become completely occluded drives the patient to the point of feeling what can only be the "inevitable end."

*3rd Place-Surgical Innovation December 1988 Shangri-la presented at the 4th ASEAN Otolaryngology Congress, Singapore, April 1989

It is comforting to note that immediate relief can be obtained through a tracheostomy. However, the problem is far from over as it is only the beginning of a more tedious process of trying to suggest measures towards doing without a tracheal stoma. Patients develop a distinct aversion to the tracheostomy and are willing to trade the risks of a surgical procedure for the opportunity to eliminate the tube.

Another dilemma which confronts both the surgeon and the patient is that as improvement of the airway is achieved, there is a corresponding adverse effect on the ability to phonate and vice versa. The risk of aspiration as the airway is improved is another serious consideration.

This paper presents 4 cases where surgical correction of bilateral recurrent nerve paralysis using microscopic endolaryngeal arytenoidectomy has been applied.

Case Reports

Case No. 1

V.A., a 53 yr-old female, with a previous history of thyroidectomy was admitted because of severe dyspnea. Emergency tracheostomy was done and subsequent direct laryngoscopy performed. Examination revealed bilateral midline vocal cord paralysis. On the third hospital day, a left endolaryngeal arytenoidectomy was done. The tracheostomy tube was removed after ten days. Eleven months post-operatively, the patient still has an adequate airway and breathy voice.

Comments

Patient refused any external cervical procedure because of her traumatic experience during the emergency tracheostomy. When presented with the option of an endolaryngeal approach, she then consented.

Case No. 2

R.G., a 48 yr-old female, was admitted because of dyspnea. One year prior to admission, the patient underwent a Woodman

procedure because of bilateral midline vocal cord paralysis. Since then, she has been having exertional dyspnea which became severe accompanied by inspiratory stridor one week prior to admission. Examination revealed bilateral midline vocal cord paralysis, the degree of which was similar to that prior to the Woodman procedure. A left endolaryngeal arytenoidectomy was done. Tracheostomy was removed after 10 days. She has returned to near normal life with an adequate airway and a functional voice.

Comments

After a failed lateralizing procedure through an external approach, the patient chose to undergo a less invasive surgical procedure.

Case No. 3

J.A., a 38 yr-old male, was admitted because of dyspnea. One year prior to admission, tracheostomy was done because of severe dyspnea. Patient was weaned from the tracheostomy tube after three months. A year later, patient again developed severe dyspnea requiring a repeat tracheostomy. Examination revealed immobile cords with one mm glottic opening. A left endolaryngeal arytenoidectomy was done and the tube was removed after 10 days. Seven months later, airway was still sufficient and voice was slightly breathy.

Comments

He had problems getting a job because of the employer's fear of his tracheal stoma. Due to financial constraints, he consented to a less expensive surgical procedure.

Case No. 4

F.D., a 46 yr-old female, was admitted because of dyspnea and stridor. Three years prior to admission the patient was diagnosed to have a left vocal cord paralysis. One year prior to admission, she developed "noisy breathing" and was treated as bronchial asthma which did not improve her condition. One week prior to admission, she had dyspnea and stridor

which progressed prompting admission. Examination revealed bilateral midline vocal cord paralysis. Orotracheal intubation was done followed by tracheostomy. A left endolaryngeal arytenoidectomy was done on the third hospital day. Tracheostomy was removed after 10 days.

Comments

Given the choice between an endolaryngeal and an external cervical approach, the patient readily chose the former.

Technique

After the patient has been anesthetized through a previous tracheostomy, direct laryngoscopy is performed using a Pilling laryngoscope anchored with a Lewy chest laryngoscope holder. An operating microscope with a 375 mm front lens is set up and focused over the posterior commissure. A Mayo table is placed in front of the surgeon to serve as elbow rest during the course of the procedure. An injection of epinephrine 1:200,000 dilution through a gauge 25 spinal needle is done. A one-cm incision is made over the anteromedial portion of the aryepiglottic fold overlying the arytenoid cartilage. Soft tissues are separated using sharp and blunt dissection exposing the superior aspect of the arytenoids which is held with a grasping forceps. The cartilage is dissected free from its surrounding periararytenoid tissues and the attachments cut using laryngeal scissors until the cartilage is delivered. Periararytenoid pocket is cauterized and the mucosal edges trimmed and sutured using Vicry 15-0.

Discussion

Bilateral vocal cord paralysis usually results from surgical injury to the recurrent laryngeal nerve during thyroidectomy. It can also be due to any accident with related cervical trauma, neurotropic viruses, neuromuscular compromise secondary to metabolic diseases such as diabetes, carotid endarterectomy, intracranial coma, cricoarytenoid joint fixation, and idiopathic causes.^{2,3,10,14,16}

Indirect laryngoscopy can be performed to assess laryngeal movement, however, it does not

allow for discrimination between vocal cord paralysis and ankylosis of the cricoarytenoid. Thus, direct laryngoscopy is deemed necessary in order to assess laryngeal neuromuscular integrity, evaluate mobility of the cricoarytenoid joint, and evaluate the interarytenoid region with respect to tethering fibrosis.¹

The management of patients with bilateral recurrent nerve paralysis has always been a challenge to the otolaryngologists.² Through the years, numerous procedures have been devised which offered a considerable measure of success.⁵ Therapeutic options rest on the principle of improving the airway with little or no compromise in the ability to phonate.⁸ These include tracheostomy, lateralizing as well as dynamic procedures. Lateralizing procedures of the paralyzed cords may be carried out through either intralaryngeal or extralaryngeal surgical approaches. These involve surgical techniques aimed at securing the lateralization of the vocal ligaments by entering the larynx anteriorly through a midline thyrotomy; posteriorly, behind the margin of the thyroid cartilage; and laterally, through a window in the thyroid lamina.^{2,6,8,13} The decision as to which of the procedures to undertake to secure an adequate airway should be determined by the patient's individual needs and preference and the surgeon's skill and confidence.

In 1948, Thornell described an intralaryngeal operation whereby the arytenoid was removed through the suspension laryngoscope.^{2,6,7} Indications include improved glottic airway without a cervical incision and the inherent morbidity of wound infection and prolonged hospital convalescence; dissatisfaction of the patient with tracheostomy tube and inadequacy of the airway on the basis of arytenoid cartilage immobility.¹³

Compared to extralaryngeal techniques, intralaryngeal arytenoidectomy more consistently preserves voice quality and avoids the major complication of aphonia.¹¹ The voice quality changes to a more whispering coarse type after the procedure - a change preferred by a majority of patients over the approach ending up with a tracheostomy tube or chronic glottic obstruction.

Endoscopic examination and surgery of the larynx have come a long way since the advent of

the early laryngoscopes used by Kirstein, Yankauer, and others at the turn of the century. Since the development of the wide bore laryngoscopes with fiberoptic illumination for use with the operating microscope, microscopic laryngoscopy and microsurgery of the larynx have come of age. Microscopic laryngoscopy allows examination of the fine details of the vocal cords and adjacent areas with binocular vision. The resulting depth of perception with increase exposure and additional illumination allows bimanual manipulation and execution of microsurgical procedures.¹¹

The surgical correction of bilateral recurrent nerve paralysis is a procedure of millimeters. A careful, bloodless, subperichondrial dissection of the arytenoid cartilage performed under direct visualization through the operating microscope will result in less fibrosis in the arytenoid bed and therefore, an improvement of the airway by an additional 1 or 2 mm.²

This increase in size of the glottic aperture following arytenoidectomy by the microsurgical technique occurs posteriorly in the arytenoid bed. Very little lateralization of the membranous vocal cords develop and as a result, the voice remains good. A 2 to 3 mm space between the membranous vocal cords persists which preserves vocal function and an estimated 5 to 6 mm space is present in the collapsed bed, which provides an adequate airway.^{2,16}

Screening of candidates for intralaryngeal approach includes lateral neck radiographs to rule out tracheal stenosis, pulmonary function studies, and laryngoscopy before the definitive procedure.

Case selection is important. Patients with significant cardiac disease are not good candidates for arytenoidectomy because this procedure does not allow the respiratory exchange which is accomplished through a tracheal stoma.¹² Obesity and psychological make-up also influence the results. Anatomic configuration impairing laryngeal access to the supraglottic larynx creates a technical difficulty. Reduced visibility, restriction of surgical manipulation, and distance from the operative target combine to make endolaryngeal arytenoidectomy more difficult to accomplish.¹⁶

This procedure, as in any other surgical procedure, is not without complications. There could be incomplete removal of the arytenoid cartilage, failure to lateralize the vocal cords, intraoperative bleeding causing abortion or revision of the procedure, and postoperative scarring making external revision more difficult. 2,14,16

Conclusion

The problem of bilateral midline vocal cord paralysis was addressed by the use of microscopic intralaryngeal arytenoidectomy. It has proved reliable and easy to perform with no major complications encountered.

Microscopic intralaryngeal arytenoidectomy is not presented to replace other approaches to bilateral midline vocal cord paralysis but for the otolaryngologists to assess its unique place as one of the alternative for the surgeon and the patient who elects to undergo a lesser surgical procedure.

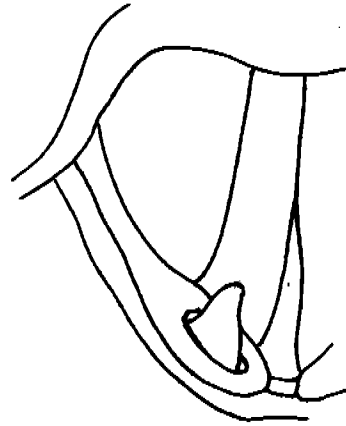


Fig. 2. Arytenoids dissected free from surrounding periararytenoid tissues.

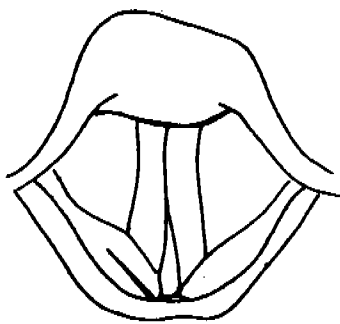


Fig. 1. 1 cm incision over the anteromedial part of the aryepiglottic fold

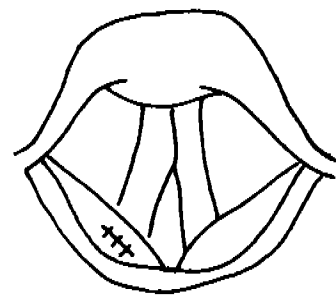


Fig. 3. Periararytenoid pocket cauterized and sutured.

Bibliography

1. Bailey, B.J., et al. *Surgery of the larynx*. W.B. Saunder Co. 1985.
2. Helmus, C. et al. Microsurgical thyrotomy and arytenoidectomy for bilateral current laryngeal nerve paralysis. *Laryngoscope* 80:491-503, 1970.
3. Holinger, L. et al. Etiology of bilateral abductor paralysis. *Annals of Otolaryngology* 85:428-435, 1976.
4. Holinger, P. et al. Vocal cord paralysis and psychopathology. *Archives of Otolaryngology* 107:33-36, 1981.
5. Kelly, J.D. Surgical treatment of bilateral paralysis of the abductor muscles. *Archives of Otolaryngology* 33:293-304, 1941.
6. Kirchner, F.R. Endoscopic lateralization of the vocal cord in abductor paralysis of the larynx. *Laryngoscope* 89:1779-1783, 1979.
7. Kirchner, F.R. Endoscopic rehabilitation of the airway in laryngeal paralysis. *Annals of Otolaryngology, Rhinology and Laryngology* 91:382-383, 1982.
8. Lewy, R.B. et al. Validation of vocal cord lateralization procedure. *Laryngoscope* 92:697-699, 1982.
9. Michike, A. Rehabilitation of vocal cord paralysis. *Archives of Otolaryngology* 100:431-441, 1974.
10. Parnell, F.W., et al. Vocal cord paralysis: Review of 100 cases. *Laryngoscope* 80:1036-1043, 1970.
11. Strong, M.S. Microscopic laryngoscopy. *Laryngoscope* 80:1540-1552, 1970.
12. Strong, M.S., et al. Cardiac complications of microsurgery of the larynx: Etiology, incidence, and prevention. *Laryngoscope* 84:908-919, 1974.
13. Thornell, W.C. Intralaryngeal approach for arytenoidectomy in bilateral abductor paralysis of the vocal cords. *Archives of Otolaryngology* 47:505-508, 1948.
14. Thornell, W.C. Transoral intralaryngeal approach for arytenoidectomy in bilateral vocal cord paralysis with inadequate airway. *Trans. Am. Acad. Ophthalmol. and Otolaryngol.* 53:631, 1949.
15. Ward, P., et al. Observations in so-called idiopathic vocal cord paralysis. *Annals of Otolaryngology, Rhinology, Laryngology* 91:558-562, 1982.
16. Whicker, J.H. et al. Long term results of Thornell arytenoidectomy in the surgical treatment of bilateral vocal cord paralysis. *Laryngoscope* 82:1331-1335, 1972.
17. Woodman, D.G. Bilateral abductor paralysis: A survey of 521 cases of arytenoidectomy via the open approach. *Archives of Otolaryngology* 58:150-153, 1953.

I wish to present a case that proves all
these allegations wrong.

**GLOBUS HYSTERICUS ---
A JOKE NO MORE***

Eduardo C. Yap, MD**

Report of a Case

E.C., a 36-yr old female, consulted at the
Hospital ng Maynila for a "lump in the throat."
Three years previously, she noticed an abnormal
sensation in her throat better described as
lumpy without really making her swallowing
difficult. As her condition progressed,
swallowing noticeably became more and more
difficult but always with improvement towards
the end of her meals. However, the difficulty
gradually became worse but not to a point where
she cannot tolerate solids.

A month prior to admission, E.C. went down
with a "flu" and at least on one occasion, the
patient threw up at which time she said the
sensation of a lump became more obvious and
noticeable in her throat. At the same time,
the patient also claimed that her breathing
became difficult but the moment she swallowed,
respiration became easy. She immediately
sought consultation to an EENT specialist and
was told that there was nothing wrong in her
throat. Truth to tell, this was not the first
time she sought consultation but all previous
examinations proved non-revealing and in each
instance, her case was labelled as a case of
"pharyngitis."

At the time of admission, E.C. was on
regular diet with no weight loss. On physical
examination, she appeared apprehensive,
well-built, and fully cooperative. Among
others, ENT examinations by four ENT residents
proved normal.

Esophagogram obtained at the Pasay-Para-
naque Hospital on 23 July 1987 showed "Essen-
tially Normal Esophagogram."

However, on account of her insistence that
we take a look inside, the patient was admitted
for diagnostic esophagoscopy.

Introduction

Scott Brown's Disease of the Ear, Nose,
and Throat defines Globus Hystericus as "a
condition in which a patient, often a middle
aged woman, complains of the sensation of a
lump in the throat usually in the region of the
thyroid cartilage. There may be other symptoms
suggestive of a functional state, and the
patient may admit that a relative or a friend
has recently succumbed to cancer of the
throat." George A. Gates, on the other hand,
in his Current Therapy in Otolaryngology-Head
and Neck Surgery 1982-83 considers all non-food
related dysphagia as Globus Hystericus. Gerald
M. English defines the condition as "a lump in
the throat of psychosomatic origin."

More recently, Puhakka et al believed that
globus mechanism is part of a normal bodily
function, and that the symptom can be provoked
as a result of strong emotional mechanism in
almost any person. Lindsay P. Gray junked the
term "Globus Hystericus" and instead suggested

* 3rd Prize-Scientific Symposium on Interesting Cases held on
11 September 1987 at the Manila Garden Hotel

** Chief Resident, Department of Otolaryngology, OLM-Hospital ng
Maynila

Discussion

Up to this point, this story is not anything unique. After all, we see patients with this complaint quite often in our daily practice.

Esophagoscopy was scheduled under general anaesthesia. Pre-endoscopically a number of throat examinations were performed and in each time her larynx, hypopharynx, and base of her tongue showed no abnormality. At the time of induction, however, the resident in Anaesthesia complained of some difficulty in intubating the patient and further examination revealed what appeared to be a solid mass in the hypopharynx which disappeared suddenly. Fortunately, intubation was uneventful and the contemplated procedure commenced.

With a 9/45 esophagoscope, the cricopharyngeal opening was identified and the scope insinuated and almost immediately a fleshy mass was observed and when the scope was pulled back a little it was further observed that it has a pedicle measuring 1 cm long attached to the right lateral wall of the cricopharyngeal opening. With the available endoscopic forceps, the pedicle was avulsed and the tumor grasped and extracted together with the esophagoscope. The mass was firm and measured 7.0x1.5x0.8 cm. On microscopic section, it revealed aggregates of huge vascular channels filled with red blood cells which has occupied the walls of the elongated tumor mass, thereby augmented the obliteration of the esophageal lumen. The final diagnosis was Hemangioma.

Comment

A patient with Globus Hystericus is usually a female between 30 and 60 yr of age. There must be no real pain, and no real impairment in swallowing and eating, and the clinical examination shows no evidence of abnormality. All the doctors who have examined this lady do not stand indicted. As previously opined, any case coming to us with the above complaint with negative findings on indirect or direct laryngoscopy deserved to be diagnosed as Globus Hystericus.


Unfortunately, nobody among those consulted believed the patient when she claimed that she felt something inside her throat when she threw

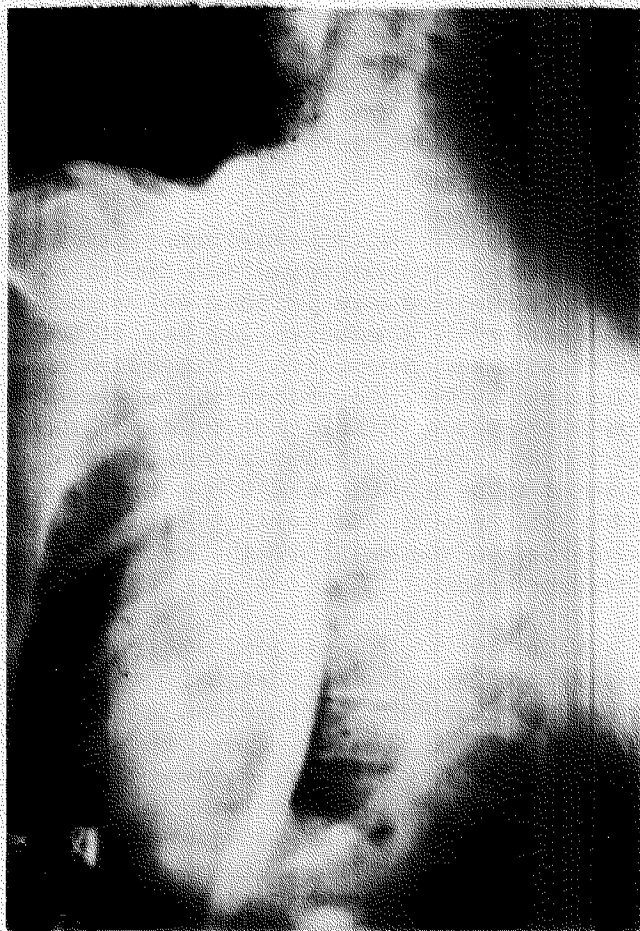
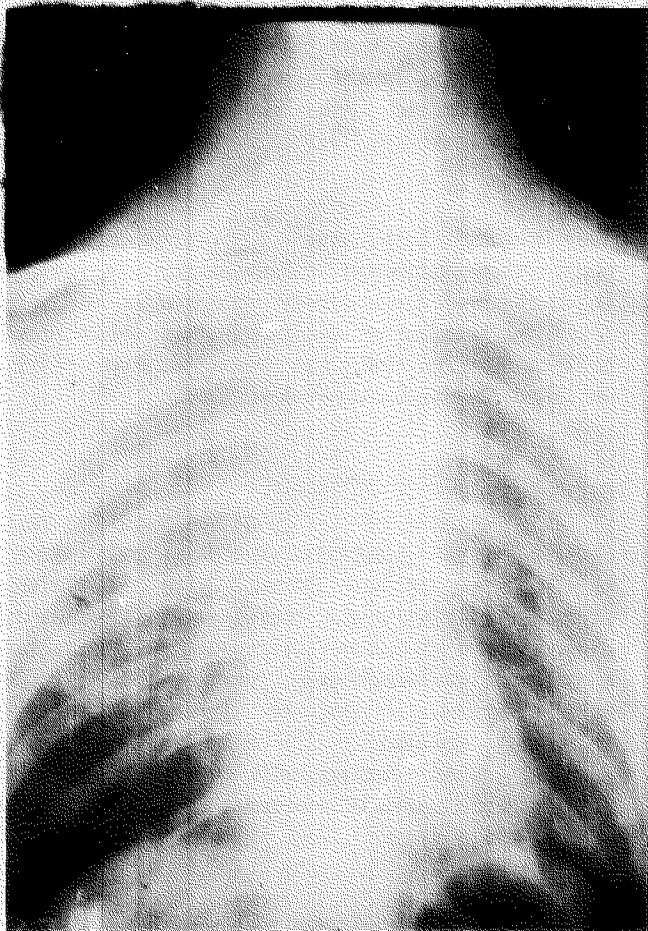
up a month prior to admission. Apparently, the obstructing mass that made the intubation a problem was the same lesion the patient claimed to have felt and reswallowed so that at the time esophagoscopy, the mass was back in the esophagus.

Looking back and on retrospect, the negative esophagogram was not after all normal in the sense that closer examination with a little stretching of the imagination would show tell-tale sign of the mass lesion being outlined at the location described.

Summary

A 36 yr old apprehensive lady complaining of "a lump in her throat" with no throat findings initially and therefore appropriately diagnosed as Globus Hystericus turned out to be a case of an esophageal tumor. This should make practitioners in the specialty to keep this rare possibility in mind when handling similar cases particularly when it proved intractable to usual treatment.





Esophagogram revealed essentially normal findings.

Bibliography

Enrique, A.F. Personal communication.

Ballantyne, J. and J. Groves. Scott-Brown's diseases of the ear, nose, and throat. 4th ed., Vol. 4, Butterworths, London, 1979. pp. 109.

English, G.M. Otolaryngology a textbook. 1984.

Gray, L. The relationship of the "inferior constrictor swallow" and globus hystericus or the hypopharyngeal syndrome. The J. of Laryngology and Otology. July 1983, Vol. 97, pp. 607-618.

Puhakka, H., V. Lehtinen and T. Aalto. Globus hystericus - a psychosomatic disease? J. of Laryngology and Otology. Vol. 90. pp. 1021.

and hardly portable. In the 1940's, because of the reduction in size of the vacuum tubes and batteries, hearing aids assumed the size of a cigarette pack.

Another significant breakthrough occurred in 1950 with the development of the transistor, which replaced the vacuum tube.

As a consequence, microminiaturization of aids became a reality in 1960. Hearing aid sizes were greatly reduced without sacrificing efficiency.

Finally, the 1970's witnessed the introduction of very powerful wearable hearing aids utilizing microchips, which we are using up to the present.

From the very crude instrument of Hutchinson in 1900, the growth of hearing aid technology has been almost logarithmic. At present, about 300-400 models are offered for sale to suit each individual.

In man's desire to achieve better hearing, a price, literally, has to be paid. It is high: about ₱3,000-₱5,000. When patients go to government hospitals like Ospital ng Maynila and Philippine General Hospital to obtain the best, but free ENT care, it is very discouraging to see patients who are hard of hearing, left unimproved because they cannot afford the instrument. Therefore, better than giving them an ear trumpet, but short of presenting the real device, the author looked back almost 40 years when the transistorized hearing aid was still in its conception, and decided to make one himself.

Thus, we are presenting the poor, deaf man, the 401st option: an efficient, portable, and cheap hearing aid.

The Instrument

A hearing aid consists basically of 3 parts: (1) a microphone which converts sound energy to electrical impulses; (2) an amplifier, which intensifies these electrical impulses; and (3) a receiver, which receives the intensified electrical impulses and reconverts to sound energy. In effect, a hearing aid is nothing but a miniaturized P.A. system, or a minus-one cassette.

THE 401st OPTION *

Emmanuel S. Samson, MD**

Any instrument that brings sound to a listener's ear may be called a hearing aid. As far back as one can remember, man has attempted to improve his hearing by placing his cupped hand against his pinna. This is probably the earliest known hearing aid. It is crude, but very effective.

Man's search to further improve his hearing led to the ear trumpet, which provided 10 to 20 decibels increase in sound intensity.

In 1900, Hutchinson introduced the first electronic aid which became the forerunner of the present aids. It consisted of a carbon microphone, batteries, and ear phones. It was more efficient, but carrying the whole set-up required strength and determination because it was big and heavy.

In the 1930's, with the invention of vacuum tubes, the carbon microphone became obsolete. But vacuum tube aids were still big

* 3rd Prize-6th Scientific (Surgical Innovation and Instrument Design) Research Contest in Otolaryngology held at Quezon City Sports Club, 4 December 1987

** Junior Resident, Department of Otolaryngology, PLM-Ospital ng Maynila

The search for the poor man's hearing aid started by doing rounds of downtown Manila's electronic shops. After quite an extensive search, we ended up getting a second-hand earphone, a condenser microphone, and a 1.5 volt amplifier kit. A gain, or volume control was likewise taken from an old transistor radio.

With expert supervision from an electrician, the components were assembled. The final result is shown, with specifications:

Dimensions : 2x3x.5 in.
Weight : 75 grams
Power source : one size AA penlight
 battery
Voltage : 1.5
Power gain : ???
Frequency range: ???
Total cost : ₱80.00

Discussion

In 1976, the American National Standards Institute published a new standard for measuring the electroacoustic properties of hearing aids. This included such terms as (1) SSPL 90 (Saturation Sound Pressure Level for a 90 dB sound); (2) HF-average SSPL 90 (High-frequency Saturation Sound Pressure Level), (3) Full-on gain curve; (4) HF-average full-on gain; (5) Frequency response curve; (6) Harmonic distortion; (7) Battery current drain, etc. All of these are very technical and do not need to be explained further.

Because of obvious limitations, our prototype cannot be calibrated so as to conform with these standards.

Instead, the merits of our device was measured using a single parameter: an improvement of the patient's hearing as per patients' own claims.

All patients with deafness are candidates for hearing aids. But it has been shown that patients with flat, purely conductive hearing loss, with good speech discrimination, and without recruitment, are the better candidates.

Patients who consulted at the ENT OPD with hearing impairment were used as test subjects for our device. These patients were subjected

to pure tone, speech audiometry, and SISI. To screen the candidates who would most likely benefit, the following criteria were used:

1. 95-100% speech discrimination score;
2. normal SISI;
3. a flat, purely conductive hearing loss. The latter was necessitated by the fact that the frequency range of our instrument has not been predetermined.

Patients with audiometric patterns which did not conform with these criteria were not included.

A total of 15 patients were used as test subjects: 6 were post-mastoidectomy; 8 with dry perforation; 1 with normal looking tympanic membranes.

12/15 (70%) claimed improvement of their hearing.

Comments

It cannot be overemphasized that the manner by which our hearing aid was created was crude, at its best. It pales in comparison with the more than 400 models available in the market. It does not have a tone control which could selectively amplify certain frequencies. It does not have an automatic volume control which could protect the user from sudden bursts of loud sounds, thereby protecting him from discomfort and acoustic trauma. Nor does it have computer microchips as components. Instead, bulky transistors and batteries are utilized.

Also, as stated previously, it cannot be calibrated as of yet to meet the set standards for hearing aids.

All things considered, what we have created in the Department of ENT of Ospital ng Maynila is not a new and revolutionary device. It is from all angles, a primitive device that was created primarily as a solution to a poor, deaf man's dilemma.

Hearing aid manufacturers may not view our instrument on a serious note. They may regard it as a novelty item which does not stand a chance competing with 400 other models, much less, merit mention in major ENT journals.

But a deaf man will never be impressed by specifics like SSPL 90's, harmonic distortions, frequency response curves, etc. The only thing that is of paramount importance to him is the restoration of his hearing at a price within his means.

Our instrument has proven its worth, although in a very limited sense.

What about long-term complications? The author is very much aware of these, notably acoustic trauma. We therefore plan to do serial hearing tests over long periods, and only then can we make concrete conclusions. We also plan to calibrate it to make it approximate the qualities of preexisting models. Lastly, we might incorporate a tone control to make frequency amplifications more selective.

All of these we plan to accomplish without defeating our main purpose: to make a hearing aid that is functional as well as cheap.

We can see that there are still a lot of refinement to be made. But nonetheless, we at the Department of ENT of Ospital ng Maynila, with our very strong commitment to help the poor, deaf man, strongly believe that it can be done.

Bibliography

Cody, Robert, M.A. Hearing aids Chap 6, Otolaryngology, Paparella and Shumrick, 1980.

Mawson, S. and H. Ludman. Part 2, Chap 5, Diseases of the ear: a textbook of otology, 4th ed. 1979.

Enriquez, Angel, M.D. Personal communication.

Yap, Eduardo, MD. Personal communication.

MALAR SWELLING: A LONG DISTANCE AFFAIR*

William L. Lim, MD**

Introduction

Malar swelling, proptosis, trismus, and chemosis will invariably lead one to entertain a primary tumor in the maxilla or perhaps in the orbit. Although, metastasis may enter into the differential diagnosis, the possibility is often overlooked owing to its relative rarity in parts where primary neoplasms are more likely to be encountered.

Paranasal sinus and orbital metastases from a distant primary focus are not frequently encountered in practice. Most articles on these subjects have been in the nature of case reports. In 1965, Rose found only 51 reported cases of orbital metastasis in his extensive survey of literature.¹ On the other hand, there were less than 70 cases of paranasal sinus metastatic tumors reported in world literature.²

A case report, probably the first in our local literature of a metastatic tumor to the orbit, maxilla, infra-temporal fossa, and fronto-epidural space is being presented.

* 3rd Place-Interesting Case Paper Presentation held at the Manila Garden Hotel, 1987

** Resident, Department of Otorhinolaryngology, UST Hospital

A 37 yr old, female teacher, was admitted on June 25, 1987 at the Santo Tomas University Hospital Clinical Division because of swelling of the left half of the face.

About 4 months prior to confinement, the patient noticed swelling of the left side of her face, her left eye smaller than usual and displaced upward. There were no other accompanying signs and symptoms. Towards the latter part of the month she developed difficulty of raising both arms.

Two months prior to admission, the patient consulted a physician and was prescribed an eye drop which afforded no relief of her condition.

A month and a half prior to admission, she consulted an ophthalmologist and was given an eye drop, steroid, and antibiotics. A few days later, she developed swelling of the lower eyelid, dull pain on the left cheek, and difficulty in opening her mouth.

Two weeks prior to admission, the patient developed left temporal headache, proptosis, and blurring of vision of the left eye, prompting consultation at the Ophthalmology section of the Santo Tomas University Hospital Clinical Division. She was advised admission but she refused.

The night prior to admission, the patient consulted at the emergency room because of the same complaints. She was referred to Neurology and was subsequently admitted.

Pertinent Physical Examination

On admission, the patient was conscious, coherent, ambulatory, and with stable vital signs.

Examination of the head and neck revealed left malar swelling, trismus, the left eye proptosed, chemotic, displaced superomedially, and had limitation of movement in all gaze. Visual acuity was 20/25, OD and 20/200, OS. Intra-ocular pressure was elevated on the left eye to 28 mm Hg. Fundoscopy revealed blurred disc margin of the left eye.

Otoscopy and anterior rhinoscopy were essentially normal. Posterior rhinoscopy, however, could not be done due to marked trismus.

Pertinent neurologic examination revealed the patient to have weakness of both upper extremities but could grasp objects very well. There were no sensory deficit nor long tract signs.

An incidental finding of a 6 cm diameter hard, relatively mobile mass at the lower outer quadrant of the right breast was noted.

Course in the Ward

The patient was admitted under the service of Neurology. Initial work-ups which included chest, skull, and orbital x-rays were essentially normal. However, ESR was elevated to 90 mm. Initial medications were naproxen sodium, diazepam, and an eye ointment.

The patient was referred to Ophthalmology for evaluation of proptosis. Fundoscopic findings revealed indistinct disc margin with flame-shaped hemorrhages along the peripillary area of the left eye. An impression of papilledema, OS, rule out retrobulbar mass was given. She was then transferred to the service of Ophthalmology and was started on steroids.

A referral to Otorhinolaryngology was done for further evaluation of malar swelling. With findings of left malar swelling, trismus, proptosis, and chemosis of the left eye, maxillary tumor was highly entertained. Flexible nasopharyngoscopy was done when posterior rhinoscopy was impossible due to marked trismus. Tissue samples were taken from the nasopharynx for histopathological examination and were found to be negative.

X-ray of the maxillary sinus showed haziness of the left antrum. A naso-antrostomy was done and specimens from antral curettage were sent for histopathological examination and were negative.

A CT scan was done and it revealed a short tissue tumor with malignant characteristics involving the left maxillary sinus, left orbit, left infra-temporal fossa, left frontal sinus

as well as the left fronto-temporal epidural space.

Guided with the CT scan plate, an incisional biopsy was done at the left zygomatic area and it revealed a metastatic undifferentiated carcinoma. With this result, the search for the primary tumor site was in order.

Having incidentally palpated a breast mass on physical examination, we then thought that this could be the primary tumor site. An incisional biopsy was done and the result was infiltrating ductal carcinoma.

Review of slides revealed that the tumor cells from the zygomatic area exhibited features similar to those of the breast carcinoma.

With a final diagnosis of infiltrating ductal carcinoma, right breast with metastasis to the left orbit, left maxilla, left frontal sinus, infra-temporal fossa, and left fronto-epidural space, the patient was referred to the section of Oncology for chemotherapy. The patient, however, refused further treatment.

Discussion

Metastatic tumors to the orbit and paranasal sinuses are comparatively rare. Less than 70 cases have been reported in the world literature.² This may be due to the fact that a complete skeletal survey on patients with cancer is not a routine procedure; or at time of death, only a limited number of bones are examined. Paranasal sinus or orbital metastases, therefore, are apt to be recognized only if some other symptom characteristic of primary tumor in the area occurs.

In most cases of orbital or paranasal sinus metastasis from breast carcinoma, the diagnosis of the primary tumor antedates the onset of manifestations by an average of 3-5 years.² The case that is presented is exceptional in that, the signs and symptoms of metastasis came first than the diagnosis of the primary tumor.

The most common ocular manifestations of metastatic orbital tumors are exophthalmos, pain, decreased vision, and periorbital swelling.^{1,3} In cases of metastatic paranasal

sinus tumors, epistaxis, facial deformity, facial pain, and nasal obstruction are the most common presentations.^{2,4,5} It is interesting to note that in cases of metastatic paranasal sinus tumors from the breast, epistaxis, which is one of the earliest signs of sinus tumors rarely occurs.⁶

In our review of literatures, the breast and the lung were the most common primary foci of metastatic orbital tumors, followed by the genito-urinary tract and the gastro-intestinal tract.^{1,6} In cases of metastatic paranasal sinus tumors, the genito-urinary tract and the lungs are the most common primary foci followed by the breast and gastrointestinal tract.^{2,5}

All eight cases of mammary carcinoma metastasizing to the orbit reported by Font and Ferry were of the infiltrating ductal type.¹ This type of breast cancer is commonly involved in metastasis because of its high incidence and its propensity to spread by the hematogenous and lymphatic routes.⁷

The most plausible means by which tumor cells may reach the orbit and paranasal sinuses is through the hematogenous route.^{1,2,7,8} The most readily apparent route is via the arterial vessels of the head and neck. In addition, the work of Batson on the spread of carcinoma, suggests two other routes of metastasis.⁹ He demonstrated that during periods of increased intrathoracic pressure, a retrograde flow occurs from the usual venous channels back to the vertebral venous plexus. A similar retrograde flow may occur in the jugular venous system.

The patient in the case presented had weakness of the upper extremities manifested by inability to raise both arms. This could be due to polymyositis. Polymyositis is defined as a systemic connective tissue disease characterized by inflammatory and degenerative changes in the muscles, leading to symmetric weakness and to some degree atrophy principally on the limb girdles.¹⁰

In 1975, Bohan and Peter classified the Polymyositis-Dermatomyositis complex into 5 groups.¹¹ Group 1 - primary idiopathic polymyositis; Group 2 - primary idiopathic dermatomyositis; Group 3 - dermatomyositis/polymyositis associated with neoplasia; Group 4 childhood dermatomyositis/polymyositis

associated with vasculitis; Group 5 - polymyositis/dermatomyositis associated with vascular disease.

Evidently, our patient belongs to Group 3, i.e., polymyositis with neoplasia. To date, the association of polymyositis with malignancy is still unresolved. Whatever the explanation, it must be consistent with the clinical observation that the removal of the cancer may result in the remission of the polymyositis.¹²

Conclusion

When a patient presents with signs of unilateral malar swelling or any tumor of the head and neck for that matter, the clinician is quite limited and solely dependent upon previous history of cancer elsewhere in the body for a presumptive diagnosis of metastatic carcinoma. If such a history is available, then one should undertake appropriate clinical and radiographic studies in search for additional evidence of a metastatic disease. If these prove nonrevealing, a biopsy of the tumor becomes necessary.⁷

It is suggested that a complete medical history and a thorough physical examination be done in cases of head and neck tumors. Treatment of a metastatic tumor as if it were a primary malignancy constitutes inadequate and ineffective therapy and can result to subjecting the patient to an unnecessary, extensive, and mutilating procedure.

In this age of highly specialized medicine, physicians tend to focus attention in their areas of specialty. The holistic approach in the management of patients is best exemplified by the case presented. Physicians, therefore, must be concerned with the whole patient, not with specific parts of the body.

References

1. Font, R.L. and A.P. Ferry. Carcinoma metastatic to the eye and orbit. *Cancer* 38: 1326-1335. 1976.
2. Bernstein, J.M. Metastatic tumors to the maxilla, nose, and paranasal sinuses. *Laryngoscope* 34:621-650. 1965.

3. Huda, N. Metastasis of carcinoma of the breast to both orbits. *American J. of Ophthalmology* 64:779-780. 1967.
4. Friedmann, I. Metastatic tumors in the ear, nose, and throat region. *J. of Laryngology and Otolaryngology* 79:576-590. 1965.
5. Boone, M.L. et al. Malignant disease of the paranasal sinuses and nasal cavity. *Archives of Otolaryngology* 102:627-636. 1968.
6. Nahum, A.M. et al. Malignant tumors metastatic to the paranasal sinuses: case report and review of the literature. *Laryngoscope* 73:942-952. 1963.
7. Schwartz, S.I. et al. Principles of surgery. McGraw-Hill Book Co., USA. 1979.
8. Shibuya, H. et al. Second primary carcinomas with squamous cell carcinoma of the maxillary sinus. *Cancer* 58:1122-1125. 1986.
9. Batsakis, J.G. Tumors of head and neck, 2nd ed. Baltimore. 1979.
10. Berkow, R. (ed). The Merck manual, 14th ed. Merck and Co., New Jersey. 1982.
11. Bohan, A. and J.B. Peter. Polymyositis and dermatomyositis. *New England J. of Medicine* 292:344. 1975.
12. Robins, S.L. and R.S. Cotran. Pathologic basis of disease, 2nd ed. Philadelphia. 1979.

THREE-IN-ONE STANDBY OPERATING ROOM UNIT*

Pio R. Pajarillo, MD, Bernardo
D. Dimacali, MD, and Charlotte
M. Chiong, MD**

Abstract

Electric power failures pose a problem to any surgical procedure. A low cost and simple three-in-one operating room unit was designed and constructed with a suction apparatus, light source, and thermal cautery probe powered by a 12-volt car battery with a built-in charger. The unit serves as an additional ENT unit for the operating room for regular use and also as a standby emergency unit for power failure conditions.

Introduction

Electric power which is basic to modern life is largely responsible for the high standard of living and advanced level of industrialization of much of the world. Medicine has largely gained likewise from the benefits of electricity and has powered many types of very useful and important medical equipment such as the suction machine, headlight, and cautery unit among others. These

special equipment have imposed a significant financial burden to the otolaryngologist, even more so in these times of economic depression. These expensive electrically powered equipment are however useless when power failure occurs. Consider too the risks such power failure brings to the patient in the middle of major surgery.

This project explores the development of a low cost battery powered ENT unit consisting of a suction apparatus, headlight, as well as a cautery unit and may prove invaluable in the event of a power blackout while performing a surgical procedure or treating an emergency case.

Basic Theory

The basic set-up is that of a car air horn used in reverse to create suction. The power source is an ordinary 12-volt car battery maintained in a fully charged condition by a charging system plugged into a 220-volt AC socket. A regular circuit converts the 12 volts into 6 volts and 3 volts for the headlight and thermal cautery, respectively (Figure 1).

Materials and Methods

The components of our portable operating room unit include:

- 1) telephone stand with wheels
- 2) 12-volt car battery with terminal clamps
- 3) car air horn motor (12 volts)
- 4) dextrose bottle (1 liter)
- 5) rubber suction tubings (3 meters)
- 6) door bell switch
- 7) 18 volt stepdown transformer rated at 6 amperes
- 8) high current diode bridge assembly
- 9) DC regular circuit
- 10) three-way switch
- 11) formica
- 12) 0-6 amperes DC meter
- 13) 0-15 volts DC meter
- 14) two pairs of banana plugs and sockets
- 15) control knobs (3)
- 16) hook-up wire
- 17) headlight with cord
- 18) disposable thermal cautery probe
- 19) pilot light

* 1st Prize-6th Scientific (Surgical Innovation & Instrument Design) Research Contest in Otolaryngology held at Quezon City Sports Club on 4 December 1987

** Residents. Department of Otolaryngology, UP-PGH Health Sciences Center

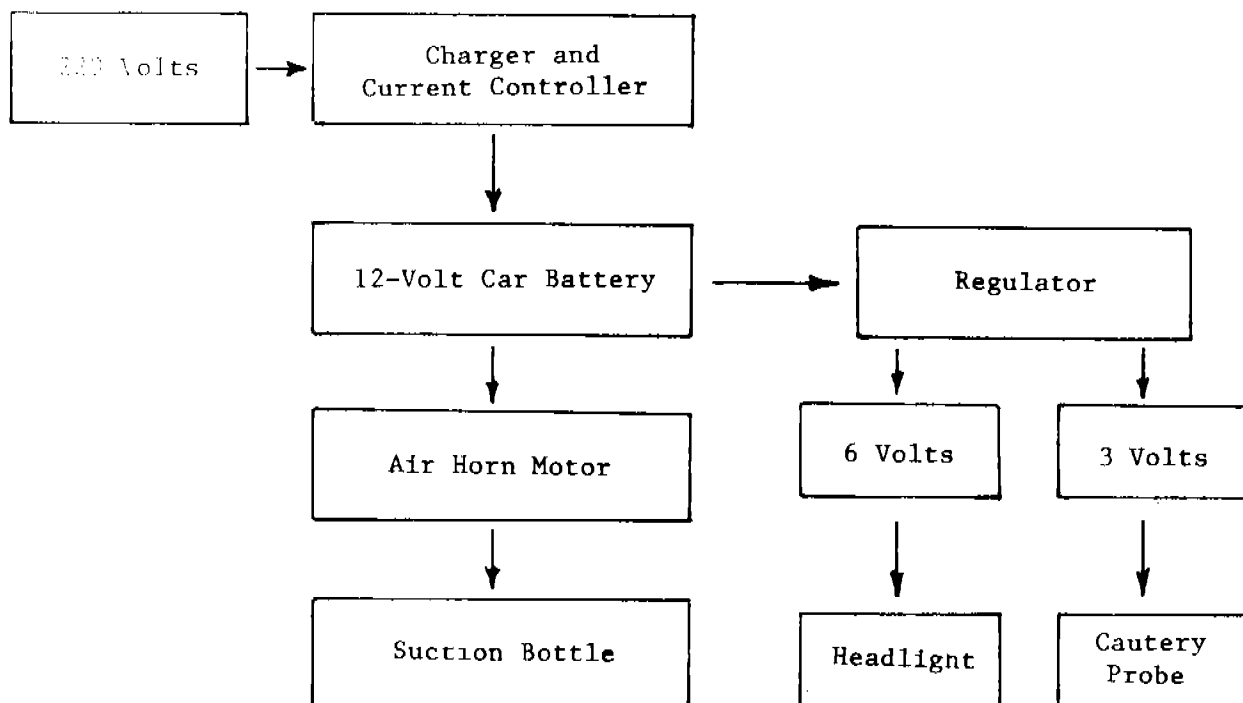


Figure 1. Block Diagram of the 3-in-1 Standby O.R. Unit

Construction and Assembly

The battery is mounted on the telephone stand with clamps and bolted to the base. The suction bottle is a used 1-liter dextrose bottle secured to one of the legs with a metal band. Short pieces of metal tubings are inserted into the holes of the bottle's stoppers. The suction motor is bolted to the telephone stand above the battery. Rubber tubing is used to connect the air inlet of the motor and the suction bottle. The suction motor is controlled by a footswitch made from a doorbell switch mounted on a piece of wood, with a hinged metal plate over the button for the surgeon to depress. The charger and regulator assemblies are mounted above the motor. Controls and meters are mounted at the top level of the stand.

The used batteries of a disposable thermal cautery probe are replaced by electrical wires with terminal banana plugs. This is sterilized by gas autoclave and kept on standby. A locally improvised 6-volt headlight with compatible banana plugs is used as a light source. A standard Welch-Allyn headlight may also be used if leads are modified to fit the connectors.

Discussion

The unit develops a maximum suction pressure of negative 250 mm Hg. One liter of fluid can be suctioned in sixty eight seconds. Table 1 shows a comparison of the generated suction pressure as measured by a vacuum gauge in this unit, the portable electric suction machine, and the centralized wall mounted suction system. Rates of suctioning in milliliters per minute are also compared. Results show that this unit compares well with both the portable electric and centralized wall mount suction machines.

Table 1. Comparative data between the centralized hospital suction system, portable 220-volt suction apparatus and the 3-in-1 ENT unit.

	Centralized	Portable	3-in-1 Unit
Maximum suction pressure (mm HG)	300	230	250
Maximum delivery rate (ml/min)	1250	830	884

The suction motor is controlled by a foot-switch to develop suction only on demand. This intermittent use conserves battery power and minimizes the rate of wear of the suction motor.

The illumination achieved with a headlight connected to the light source is comparable to that of a 220 volt power source.

The thermal cautery probe generated sufficient heat as that of a regular battery powered disposable cautery probe.

The charger was designed with the following features:

- 1) It has a variable charging rate.
- 2) Charging can be done even while the unit is being used.

Immediately after a power failure, the charger can be set to "fast charge" to quickly recharge the battery. However, if the unit is to be used as an additional operating room unit even with electricity available, the charger can be set to "slow charge" to maintain full battery charge. These provide the advantage of charging the battery at a rapid rate in anticipation of another power failure. The slow charging rate likewise prevents the battery from losing power while the unit is used when there is electricity. A volt meter is provided to monitor battery condition at all times.

This unit was tested in the PGH operating rooms during various procedures as parotidectomy, thyroidectomy, and open reduction of mandibular fracture. No difficulties were encountered throughout the surgical procedures.

The cost of this unit is approximately ₱1700.00, excluding the headlight, and is considerably cheaper than a brand new electric suction machine costing more than ₱3000.00.

Summary

A three-in-one operating room unit combining a suction machine, light source, and thermal cautery probe powered by an ordinary 12-volt car battery was designed and constructed. The unit proved to be a simple, low cost alternative for continued surgery despite a power failure. Even in the presence of electricity, it serves as an additional operating room unit.

References

- Fink, D. (ed.). Electronic engineers handbook. McGraw Hill Book Company. 1975.
- Linear applications handbook. National Semiconductors. 1986.
- Savalla and Aligui. Brownout suction machine, The Philippine J. of Otolaryngology - Head and Neck Surgery. 1986. 472-75.

**UNIVERSITY OF THE PHILIPPINES-
PHILIPPINE GENERAL HOSPITAL**

**Congratulations
to the**

**Newly Appointed Chairman
of the Department of ENT
Head and Neck Surgery,**

DR. ARMANDO CHIONG

**PERITONSILLAR ABSCESS:
RECURRENCE RATES FOLLOWING
INCISION AND DRAINAGE***

**Bernardo Dimacali, MD, Romualdo
Aragon, Jr., MD, and Ruzanne
Caro, MD**
Natividad Aguilar, MD*****

Abstract

Is an episode of peritonsillar abscess an absolute indication for tonsillectomy? Records of patients who were diagnosed as having peritonsillar abscess from June 1979 to June 1982 were examined. Patients who underwent incision and drainage were sent questionnaires by mail and/or interviewed. Only those who did not undergo subsequent tonsillectomy were included in the study. Recurrence rates of peritonsillar abscess and frequent tonsillitis for a 4 to 7-yr period following drainage were determined and analyzed. Conclusions and recommendations are presented.

Introduction

The most common deep infection of the head and neck is peritonsillar abscess, usually occurring in patients with recurrent tonsillitis or inadequately treated chronic tonsillitis.

*3rd Prize-7th Scientific (Clinical) Research Contest in Otolaryngology held at the Manila Midtown Hotel on 30 October 1987

**Residents, Department of Otolaryngology, UP-PGH Health Sciences Center

***Consultant, Department of Otolaryngology, MCU-FDTMF

Medical measures may abort an early peritonsillar abscess. However, once loculated pus forms, surgical evacuation is required. The fourteenth century French surgeon Guy de Chauliac (1362) is credited with the first account of incision and drainage for a peritonsillar abscess. His description was: "Try to incise it with a lancet and then rinse the mouth out with parsley water; but if the abscess is so far in that you cannot see it, break it with a fingernail or by rubbing it with some object." Ever since, incision and drainage has been the most widely accepted form of initial treatment. However, tonsillectomy is usually suggested to these patients and this represents one of the absolute indications. The philosophy of performing a tonsillectomy is based upon the premise that reinfections and abscesses will recur in a significant number of patients to warrant removal of the tonsils as a preventive measure. However, studies have been undertaken which showed a low recurrence rate after drainage alone. Thus, the need for a tonsillectomy after an incision and drainage for a peritonsillar abscess is being questioned.

This study, to our knowledge the first local endeavour, was then undertaken with the following objectives:

- (1) To determine the recurrence rate of peritonsillar abscess treated only with incision and drainage;
- (2) To find out the frequency of tonsillitis following incision and drainage of a peritonsillar abscess; and
- (3) To compare the results with those of foreign studies.

Materials and Methods

Records of the 73 patients initially diagnosed at the Philippine General Hospital as peritonsillar abscess or peritonsillitis from June 1979 to June 1982 were reviewed. Of these 73 patients, only 53 were considered as proven peritonsillar abscess on the basis of presence of pus either on needle aspiration or frank incision and drainage. Twenty patients were excluded because of revision of diagnosis to acute tonsillitis (12 patients), peritonsillar cellulitis (7 patients), and tonsillar neoplasm (1 patient).

Of the 53 proven peritonsillar abscesses, 33 were treated using the regimen advocated in the UP-PGH Department of ENT, consisting of incision and drainage, and systemic antibiotics (usually intravenous penicillin and chloramphenicol, then shifting to oral antibiotics after doing the drainage). No subsequent tonsillectomy was done for these patients. The 20 who were excluded consisted of 15 patients who later underwent interval tonsillectomy and 5 who refused treatment.

Questionnaires were sent by airmail to the 33 patients who underwent incision and drainage but not tonsillectomy. Questions included, among others, inquiries into: (1) whether or not the peritonsillar abscess recurred, and when, if it did; and (2) the frequency of tonsillitis per year after the incision and drainage.

Some 18 patients of the 33 responded as follows: by returning the answered questionnaires by mail (7 patients), returning by mail the answered questionnaires and following up at the PGH-Outpatient Clinic (9 patients), and by simply following up at the PGH (2 patients). The remaining 9 were visited and interviewed by these researchers at their addresses. A total of 27 patients (or 82% response rate) were included in this study.

Results

Of the 53 proven peritonsillar abscess cases, the right tonsil was affected in 33, the left in 19, and there was one case of bilateral involvement. Signs and symptoms in these 53 patients were as follows (Table 1):

Table 1: Presenting signs and symptoms of peritonsillar abscess

Dysphagia	28
Fever	27
Sore throat	22
Cervical lymphadenopathy	14
Trismus	12
Voice change	10
Odynophagia	3
Cough	2
Dyspnea	2
Headache	1

The 27 respondents included in this study had an age range of 9 to 56, with a mean age of 25.5 years. Fifteen were male, 12 female. Follow-up periods ranged from 4 to 7 years, with an average of 5 years. Frequency of recurrence of tonsillitis following drainage as related to sex is shown in Table 2.

Table 2. Recurrence rates of tonsillitis as related to sex.

Sex	0-2 Episodes per yr	3 or more episodes per yr	Total
Male	12 (44%)	3 (11%)	15 (55%)
Female	7 (26%)	5 (19%)	12 (45%)
Total	19 (70%)	8 (30%)	27

Table 3 below shows the recurrence of tonsillitis by age. It was found that the differences could be best shown by having two age groups: (1) less than 30 years and (2) more than 30 years old.

Table 3. Recurrence of tonsillitis as related to age.

Age group	0-2 episodes per yr	3 or more episodes per yr	Total
30 yr and under	11 (41%)	8 (30%)	19 (70%)
over 30 yr	8 (30%)	0	8 (30%)
Total	19 (70%)	8 (30%)	27

As can be gleaned from the tables, 70% of our respondents had less than 3 episodes of tonsillitis per year following drainage, while only 30% had 3 or more attacks per year. Relating recurrence of throat problems to sex, it was found that 12 of 15 males and 7 of 12 females had 0-2 recurrences of tonsillitis per year, while only 3 males and 5 females had 3 or more. On the other hand, relating age to recurrence of tonsillitis, 11 of the 19 patients who were 30 years or younger and all 8 patients older than 30 years had 0-2 recurrences per year. Eight in the younger age group had 3 or more recurrences of tonsillitis a year, while there was none in those older than 30.

Only 3 of our 27 respondents had recurrence of peritonsillar abscess, for a recurrence rate of 11%. Examination of their records showed that all were less than 30 years old (16, 18, and 28 years old, respectively). Two were female and one male, and that the post-drainage antibiotics were clindamycin, penicillin-chloramphenicol combination, and cloxacillin. It was discovered that the patient given the combination therapy had poor compliance with the regimen.

The first patient had an interval of 4 years between the initial quinsy and the recurrence, the second 5 years, and the third had two recurrences, each one occurring one and half years later than the one that preceded it. Two of these patients had their recurrent peritonsillar abscesses treated with incision and drainage at PGH and were advised to undergo tonsillectomy. The other had his tonsillectomy done in the province. Of the 3 patients who had recurrent peritonsillar abscess, two had 3 or more episodes of tonsillitis per year; the other reported 1 to 2 attacks per year.

Discussion

Peritonsillar abscess, or quinsy, represents a localized accumulation of pus within peritonsillar tissue, resulting from a suppurative infection of the tonsils. It penetrates the tonsillar capsule and extends into the connective tissue space between the capsule and the tonsillar bed (which is mostly the superior constrictor muscle).

It is a disease of young adults. The average age in this present study is 25.5 years. Bilateral abscess formation occurred in one patient (1.8%). In a large series reported by Bonding (1973), bilaterality was present in 3% of cases. Our most common presenting symptom was dysphagia, which is a prominent feature of peritonsillar abscess.

Most otolaryngology textbooks describe acute treatment as Incision and Drainage together with antibiotics and supportive measures. The primary objective of incision and drainage is rapid localization and drainage of the abscess. It is believed by some that incision and drainage do not provide total evacuation of multiple abscesses and all pockets of pus.

This, plus the presumption that the tonsils become diseased and fibrotic, and thus render frequent recurrences of throat infection more likely, are the reasons why most textbooks advise that definitive tonsillectomy be done a few weeks after inflammation has resolved. Early investigations such as that by Beeden and Evans (1970) showed recurrent tonsillitis in 50% of 111 adult patients with peritonsillar abscess. Subsequent studies however showed lower rates of recurrence.

1. Fried and Forrest (1981), in a 3-yr follow-up, noted one recurrence of quinsy in 23 patients not subject to tonsillectomy after I & D. They had a 20% recurrence rate of tonsillitis.

2. Herbild and Bonding (1981) noted recurrent quinsy or tonsillitis in 48% of those younger than 40 years, but had only 17% recurrence if older than 40.

3. Nielsen and Greisen (1981) reported 10 recurrent abscesses in 44 patients. All except one were less than 30 years old.

4. Schechter et al (1982) reported no recurrence of quinsy in 32 patients in a 1 to 5 yr follow-up. Four of these patients had recurrent tonsillitis but 3 already had a previous history of frequent tonsillitis.

In this study, there were 48 patients who underwent incision and drainage. Fifteen patients underwent interval tonsillectomy. Twenty-seven of the remaining 33 were contacted, a response rate of 82%. In our local series, a 4 to 7 yr follow-up of 27 patients showed that only 3 (11%) experienced recurrence of quinsy after incision and drainage. All of them were under 30 yr old, which concurs with the observation of Nielsen and Greisen and of Herbild and Bonding that recurrences occur more in the younger age groups.

After incision and drainage, 70% in our series had less than 3 episodes of tonsillitis per year while 30% had more than 3 attacks per year.

Our results and those of foreign authors (see Table 4) show that the recurrence rates of quinsy are generally low following incision and drainage alone as the surgical management. The high frequency of post-quinsy tonsillitis in

our study is attributable to the low socio-economic status and crowded living conditions of most of our respondents.

Table 4. Comparison of incidence of frequent tonsillitis and recurrence of quinsy following I & D among different studies.

Series	Mean Follow-Up Period (yr)	Recurrent Tonsillitis ($\geq 3x/yr$) (%)	Recurrent Quinsy (%)
Fried & Forrest (Boston, USA)	3	20	6
Herbild & Bonding (Copenhagen)	5	20	22
Nielsen & Greisen (Denmark)	3	24	23
Local study (PGH)	5	30	11

Indication for tonsillectomy in peritonsillar abscess is based on a past history of frequent tonsillitis and/or recurrent quinsy. Nielsen and Greisen as well as Herbild and Bonding recommend this procedure in patients younger than 30 and 40, respectively. It thus behooves one to be more selective in choosing candidates for tonsillectomy. In the PGH set-up, this is of great value since not only will it reduce patient load on the hospital but also ensure that all tonsillectomies are indicated. Thus, both the patient and the hospital are benefitted.

Summary and Recommendations

Our series had 27 patients with peritonsillar abscess and were treated by incision and drainage and antibiotics, without tonsillectomy. They were followed up for 4 to 7 years and results showed:

- (1) 11% experienced recurrence of quinsy, all of them less than 30 years old;
- (2) 70% had less than 3 episodes of tonsillitis per year;

- (3) 30% had 3 or more attacks per year, the relatively higher frequency (as compared to foreign studies) being attributed to poor socio-economic conditions.

Peritonsillar abscess as an absolute indication for tonsillectomy is contradicted. More rigid criteria for patient selection should be imposed. Tonsillectomy should be considered for patients younger than 30, or those with past history of frequent tonsillitis or recurrent abscesses. In view of this, a prospective study with emphasis on past history of throat problems should be undertaken.

Bibliography

- Fried and Forrest. Peritonsillitis, *Archives of Otolaryngology*, May 1981, 107:283-86.
- Fry and Pillsbury. The implications of 'controlled' studies of tonsillectomy and adenoidectomy, *The Otolaryngologic Clinics of North America*, May 1987, 20(2):273-78.
- Hardingham. Peritonsillar infections, *The Otolaryngologic Clinics of North America*, May 1987, 20(2):273-78.
- Herbild and Bonding. Peritonsillar abscess, *Archives of Otolaryngology*, September 1981, 107:540-42.
- Kornblut, A. A traditional approach to surgery of the tonsils and adenoids, *The Otolaryngologic Clinics of North America*, May 1987, 20(2):349-63.
- Kornblut and Kornblut. Tonsillectomy and adenoidectomy, *Otolaryngology*. Philadelphia: WB Saunders Company, 2283-2301.
- Nielsen and Greisen. Peritonsillar abscess, *The Journal of Laryngology and Otology*, August 1981, 95:801-7.
- Richtsmeyer and Shikhani. The physiology and immunology of the pharyngeal lymphoid tissue, *The Otolaryngologic Clinics of North America*, May 1987, 20(2):219-228.
- Schechter et al. Changing face of treatment of peritonsillar abscess, *Laryngoscope*, June 1982, 92:657-59.

ATROPHIC RHINITIS: CLINICAL AND HISTOLOGIC RESPONSE TO TOPICAL CONJUGATED ESTROGEN*

**Teresa Paz B. Grecia, MD,
Romualdo Aragon, Jr., MD,** and
Cesar Anthony Yabut, MD***
Joselito Jamir,, MD*****

Abstract

Atrophic rhinitis is described as a triad of fetor, nasal crusting, and atrophic intranasal structures. This study verified the validity of the Endocrine Theory, and studied the effects of tropical estrogen (both histologically and clinically) on atrophic rhinitis. Thirty-two clinically diagnosed ozena patients were enrolled in the study, but only 25 completed the study. Fourteen belonged to the test group and were given topical estrogen together with alkaline nasal wash. Eleven patients in the control group were given only alkaline nasal washing and mucolytic. Punch biopsies were taken on three periods: pre-treatment; after two weeks with treatment; and after two weeks off treatment. Protocol sheets were filled up. Data were analyzed. Topical estrogen was found to significantly improve both the clinical and histologic picture of atrophic rhinitis, as compared to the control. Further recommendations were mentioned.

* 2nd Prize-7th Scientific (Clinical) Research Contest held at the Manila Midtown Hotel on 30 October 1987

** Residents, Department of Otolaryngology, UP-PGH Health Sciences Center

*** Consultant, Department of Otolaryngology, UP-PGH Health Sciences Center

Atrophic rhinitis is a chronic nasal disease characterized by progressive atrophy of nasal mucosa and underlying bone and the formation of thick dry crusts in the greatly enlarged nasal cavity. It has been known since the biblical times; however, the development of the reflecting mirror and improved methods of rhinoscopy allowed the distinction of this ailment as a separate clinical entity. It has been described by Fraenkel in 1876 as a triad of fetor, atrophy of intranasal structures, and crusting. The disease has the same symptoms whatever its cause; the victim is distressed by the feeling of nasal obstruction and his associates by a characteristic foul odor. The strong permeating offensive odor may dominate the clinical presentation.

On examination, thin mucosa which bleeds easily is obscured by greenish crusts of thick secretions which dry in the nose. When these are removed, the abnormal patency of the nasal fossa becomes obvious in advanced cases.

The sense of obstruction is associated with lack of sensory input from receptors in the mucosa; these are either atrophic, encrusted or simply too far from the main stream of tidal air to be stimulated. Crusts may reach a size such as to produce actual nasal obstruction which may become complete. Consequently, with the feeling of obstruction comes headache. Often, these patients complain of dryness of throat, mucopurulent nasal discharge, halitosis, and epistaxis. The psychiatric changes may be quite manifest on interview. The cruel social rejection which is experienced by those with atrophic rhinitis, together with sleep disturbances caused by nasal obstruction, often results in marked psychotic behavior.

Anosmia results from atrophy of the neuroepithelium in the roof of the nose, and the first order neurones on the first cranial nerve pathway. This is often described as a merciful provision of nature in the odoriferous circumstances (Gray, 1980).

During the past 40 years, there has been a notable decline in the incidence of atrophic rhinitis in North America, Britain, and some parts of Europe. However, the incidence in Asia and Africa has remained unchanged. Improved socioeconomic factors are probably responsible for the fact that atrophic rhinitis is one of the vanishing diseases in the world (Goodman, 1973).

The true etiology of atrophic rhinitis (or ozena) has not been established as of late. Various theories have been implicated in its etiology.

Hereditary Theory

There have been isolated reports of members of the same family having atrophic rhinitis. Young (1967) mentions a daughter "inheriting" the condition from her mother. In 1966, Girgis quotes identical female twins and, separately, another mother and daughter with primary atrophic rhinitis. Barton, et al (1980) discussed an Irish family with the father having atrophic rhinitis, and 8 out of 15 of his children similarly affected, their disease varying in degree from moderate to severe. The incidence of atrophic rhinitis in this family fits in well with dominant inheritance with variability of expression.

Infection by Specific Organism Theory

Ssali (1973) reports 7 children, all of whom developed atrophic rhinitis when an affected child from another family stayed in the house. He proposed infection as the cause of atrophic rhinitis in this family. Three principal organisms have at various times been held responsible for ozena: *Klebsiella ozenae*, an atoxic form of *C. diptheriae*, and the Perez-Hofer bacillus. In a local study by Wl, et al (1980) gathered *Klebsiella* species as the most common offending organism. In this study, 47% showed the presence of *Klebsiella* species.

Nutritional Deficiency Theory

Adam (1934) experimentally showed that rats fed on diets deficient in Vitamins A and D developed a disease similar to atrophic rhinitis. Strandbygard (1956) used Vitamin A in the treatment of ozena and rhinopharyngitis sicca. The pharmacologic action probably consists of activation of an impaired function of mucous epithelium and perhaps, also of the previously not considered effect upon the vegetative nervous system. Bernat (1965), supported by experiments in mice on which hypsiderosis was induced, concluded from his studies and from the results of iron therapy in his patients, that ozena is not a localized disease of the upper respiratory tract, but a generalized condition that is due to hypsiderosis.

Sinus Infection Theory

Ssali suggested neglected rhinitis leading to sinusitis as the cause for atrophic rhinitis. Secretions from the ethmoidal air cells get trapped causing stasis and infection follows. The pus irritation starts the atrophic changes.

Endocrine Theory

In the study of Wl, et al, the sex and age distribution revealed that there were more females affected with the disease, and at their adolescent years. In a study by Cruz, et al (1979), this same trend was observed with 37 cases of atrophic rhinitis. Foreign data also show the same observation. The sex and age incidence supports this theory, the basis of which lies on the hormonal imbalance during this stage of life. Such imbalance, other authors claim, is more pronounced among females. Either estrogen lack or excess may be the etiologic factor. Young and Taylor (1961) reported several cases of atrophic rhinitis developing at puberty and of symptoms become worse in females during pregnancy and menstruation. Mortimer and coworkers (1937) evaluated the use of estrogen for this disorder in clinical trials and found that estrogen produced a marked improvement in most cases.

Other theories which received attention before are the Developmental, Autonomic Imbalance, and Collage Disease theories.

The present study verifies the Hormonal or Endocrine Theory and evaluates the effectiveness of topical estrogen as a form of treatment for atrophic rhinitis. It has the following objective: to evaluate the value of topical conjugated estrogen cream (Premarin) in the treatment of atrophic rhinitis:

- (1) To determine the effectiveness of topical conjugated estrogen cream in the treatment of atrophic rhinitis clinically;
- (2) To determine the histologic effects of topical conjugated estrogen cream on atrophic rhinitis; and
- (3) To compare the results of topical conjugated estrogen therapy with that of the control group (nasal alkaline washing).

Materials and Methods

Cases were selected as they were clinically diagnosed at the Out-patient Department of ENT at the Philippine General Hospital over a period of nine months (Jan-Sep 1987). The criteria for selection were the following:

- (1) Presence of nasal crusting and atrophy of the turbinates with or without foul odor;
- (2) No history of previous nasal surgery except for antrostomy;
- (3) No previous medical treatment similar to study received within two months prior to initiation of present therapy;
- (4) No acute, active liver disease, and history of previous liver pathology; and
- (5) No history of estrogen-dependent tumors, i.e. breast carcinoma.

Protocol sheets were filled up and covered age, sex, occupation, duration of disease, chief complaint, past and family history, and physical examination.

The patients were randomly distributed to either Group A (control) or Group B (test group). Consents were obtained. Treatment was as follows:

Group A (control): Daily nasal washing with sodium bicarbonate (1 tablet NaHCO_3 dissolved in 250 cc of lukewarm water) to be irrigated into each nostril thrice a day. S-Carboxymethylcysteine, 250 mg thrice a day.

Group B (test group): Same as in Group A plus daily topical swabbing with conjugated estrogen cream (Premarin), into each nostril thrice a day, every after washing.

Before starting treatment, punch biopsies of the middle turbinate were taken. Because the amounts of squamous epithelium in the inferior and middle turbinates vary extensively, representative biopsy specimens were taken as far back in the middle turbinate as possible in order to be certain that true respiratory mucosa was obtained. The patients followed-up weekly. After 2 weeks of treatment, a repeat biopsy was taken. The specific treatment was continued to complete one month. In Group B, estrogen application was stopped for 2 weeks (after a month of treatment) and a third biopsy was taken thereafter. After one month of nasal washing, the patients in Group A were asked to

continue the procedure for another 2 weeks (to coincide with Group B) before a third punch biopsy was taken. Group A failures were crossed over to Group B. Group B failures were recommended other treatment modalities.

The criteria for improvement were the following:

- (1) Two or all of the following:
 - a) diminution or disappearance of nasal crusting;
 - b) presence of moist, pinkish nasal mucosa; and
 - c) disappearance of fetid odor.
- (2) 50% or more disappearance of patient's initial clinical signs and symptoms; and
- (3) Histologic evidence of improvement.

Histologically, pre- and post-treatment slides were compared using the following parameters:

- (1) Type of epithelium
 - a) atrophic squamous epithelium
 - i) generalized
 - ii) focal
 - b) squamous metaplasia
 - i) generalized
 - ii) focal
 - c) pseudostratified columnar epithelium
 - i) generalized
 - ii) focal
- (2) Quality of mucus/serous glands
 - a) atrophic
 - i) generalized
 - ii) focal
 - b) normal
- (3) Relative number of mucus/serous glands - calculated as the average of the total number of glands counted per LPF found in one cut.
- (4) Presence of mucus blanket
 - a) generalized
 - b) focal
- (5) Presence of inflammatory cells
 - a) 0-100/HPF = mild
 - b) 100-1000/HPF = moderate
 - c) >1000/HPF = severe

To avoid bias on the part of the pathologist as far as the results were concerned, the slides were read at random and the kind of treatment received by the patient was not known.

The patients were evaluated on three periods: initial, 2 weeks with treatment, and 2 weeks off treatment. Percentage disappearance of signs and symptoms are calculated as follows:

$$\% \text{ disappearance} = 100 - \frac{\text{Total \# of signs \& symptoms (after 2 wk of treatment or 2 weeks off treatment)}}{\text{Total \# of signs \& symptoms initially}} \times 100$$

Results

There was a total of 32 patients; 17 were assigned to the test group (B) and 15 to the control group (A). Of those in the test group, 3 dropped out. Four dropped out from the control group. No crossovers were recruited among the failures in Group A because the patients were not willing to follow-up anymore.

All patients were females, save for one who belonged to the test group. Age ranged from 18 to 65 years, with majority falling in the late middle-aged group. Among the cases, there were 2 sisters who have the same disease, but did not report similar disease among other family members.

The duration of disease reported ranged from 2 to 4 years, except for 2 patients who have been complaining of foul odor for 20 years. Six of the 32 patients already received varied forms of treatment for their condition, i.e. NaHCO₃ washing with application of Vandol and Terramycin ointment; Vitamin A supplements; and NaHCO₃ washing alone. All these six reported no improvement with their previous medications. Only one had history of antrostomy without improvement of condition.

Table I shows the varied chief complaints of the 32 patients recruited. Among these, foul nasal odor is the most common and reportedly most embarrassing complaint. Anosmia is also a bothersome complaint. The foul nasal odor is usually reported annoying by the people around the person with atrophic rhinitis, so most of those with ozena complain about this most often than more distressing symptoms as nasal obstruction and anosmia.

All patients had the triad of crusting, atrophic turbinates, and foul nasal odor. Together with these three, all 32 patients had the signs and symptoms presented in Table II.

In the test group (Group B with conjugated estrogen cream), only 14 out of 17 patients continued and completed the study. After 2 weeks of treatment with the estrogen cream, the patients reported significant disappearance of clinical manifestations, with percentage disappearance ranging from 57.5% to 95%, and average of 78.05%. While in the control group, % disappearance after 2 weeks of NaHCO₃ nasal washing ranged from 50% to 70%, with an average of 59.09%. Table III shows the average disappearance of signs and symptoms for each group.

Among the signs and symptoms presented initially, all Group B patients reported disappearance of foul nasal odor, anosmia, dry nasal mucosa, and halitosis. However, after 2 weeks off estrogen cream, certain signs and symptoms reappeared: nasal crusting in 2 patients; foul odor, anosmia, dry nasal mucosa, mucopurulent discharge, halitosis, and postnasal drip in 4 patients each. Table IV shows the signs and symptoms 2 weeks with and 2 weeks off treatment.

In the control group, however, all 11 patients reported disappearance of foul odor and dry nasal mucosa after 2 weeks of treatment. None were found to have improvement of atrophic turbinates. Nasal crusting disappeared in 6 patients. Only a maximum of 80% disappearance of nasal crusting was reported. After 1½ months with NaHCO₃ washing, there was deterioration of signs and symptoms save for anosmia. Table V shows the signs and symptoms 2 weeks with treatment and 2 weeks off treatment in the control group.

The histologic picture of atrophic rhinitis was clearly depicted in biopsies taken. There was a change of the normal pseudostratified columnar nasal epithelium to the stratified squamous variety. Squamous metaplasia was the most common alteration observed. There was either generalized or focal atrophy of the glands. Abundant inflammatory cells were seen in the tunica propria. Mucus blanket was usually absent.

Except for 2 patients, the rest of Group B cases reported improvement of atrophic turbi-

nates after 2 weeks of treatment. In these patients, the histopath results (after 2 weeks of treatment) were compatible with the clinical trend. Table VI shows the histologic changes in type of epithelium in improved cases in Group B.

In the 2 patients without apparent clinical improvement in atrophic turbinates after 2 weeks of topical estrogen, only one had compatible histologic findings in type of epithelium. The biopsy showed squamous metaplasia with focal pseudostratified columnar epithelium; becoming squamous metaplasia with atrophy 2 weeks after treatment. However, in the other, despite lack of clinical improvement, there was significant histologic improvement from atrophic squamous epithelium to squamous metaplasia with focal pseudostratified columnar cells.

Table VI displays that 2 weeks off treatment there is slight deterioration of the epithelium in 4 cases, compatible with clinical reappearance of atrophic turbinates in the same 4 cases.

In the control group, no clinical improvement of atrophic turbinates was noted. The type of epithelium did not change significantly. See Table VII.

Among the 5 histologic criteria used in the study (type of epithelium, quality of mucus serous glands, relative number of serous/mucus glands, presence of mucus blanket, presence of inflammatory cells), only in the type of epithelium and quality of glands was there a trend compatible with clinical findings. Table VIII shows these changes.

For the control group, the quality of the glands did not change remarkably. See Table IX.

No trend was found in the relative number of glands. Presence of inflammatory cells was unchanged in both groups. Presence of mucus blanket was variable.

Discussion

The age and sex distribution of patients in this study reveals that there are more females afflicted with the disease and usually

falling in the late middle-aged group, with the oldest being 65 years old. The age distribution clearly contrasts the report of Wi, et al and Cruz, et al that atrophic rhinitis is more commonly seen at the adolescent stage. However, the sex and age incidence recovered in this study still verifies the Hormonal (Endocrine) Theory, since most of them belonged to the premenopausal and menopausal stage. Six of the 32 patients belonged to the younger age group (18-29 yr).

Many authors have advocated the Hereditary Theory. Occasionally there is a strong family history of this condition. The occurrence in this study of 2 sisters having atrophic rhinitis may suggest a familial tendency. However, no further support was offered for this.

Although the patients have anosmia, the most common chief complaint is foul nasal odor as complained to the patients by others. Cruel social rejection is probably a more frustrating state than having nasal obstruction, headache, or mucopurulent discharge. This emphasizes the strong tendency of atrophic rhinitis patients to develop antisocial attitudes or marked psychotic behavior.

There is a remarkable disappearance of clinical signs and symptoms in the patients treated with topical conjugated estrogen cream even after 2 weeks off treatment. Please see Table III. There is a difference of 12 to 19% disappearance of symptoms over that of the control. Mostly the signs and symptoms of nasal crust, foul odor, atrophic turbinates, anosmia, dry nasal mucosa, and halitosis are greatly improved in Group B. Whereas in Group A, no improvement of the turbinates is seen. Histologic findings convincingly support the clinical report.

Atrophic rhinitis does not present a pathognomonic picture histologically. Squamous metaplasia of the surface epithelium, by far the most common alteration as observed, occurs in the form of islands in the epithelium. Taylor and Young (1961) have shown clearly the changes seen on light microscopy. These vary from loss of cilia with flattening of cells to a developed 4-layered stratified squamous epithelium. In the lamina propria, abundant inflammatory infiltration is common. The connective tissue elements and basement membrane are not increased in thickness. The

absence or scarcity of columnar and goblet cells is one of the typical features, as is the abundance of neutrophils and bacteria. The blanket of mucus is absent. There is either generalized or focal atrophy of glands. Such a thinned-out epithelium is prone to infection and inflammation of the submucosal tissues, with resulting local irritation, and may tend to bleed at the slightest trauma or even spontaneously.

The Hormonal Theory suggests a lack of estrogen or hormonal imbalance as the cause of atrophic rhinitis, in much the same way that atrophic vaginitis is secondary to lack of it. In the absence of adequate amounts of estrogen, the vaginal mucosa undergoes a characteristic thinning and atrophy. This process is not restricted to the vagina, however, but appears to be shared to some extent by mucous membranes elsewhere in the body. Clinically significant mucosal atrophy induced by estrogen lack and responding favorably to estrogen therapy is also typically seen in urethra and trigone of the bladder, and also occurs in the nasal, buccal, and even gastric mucosa (Green, 1977).

Estrogens have been administered locally for atrophic rhinitis. Some authors say that the occasional improvement encountered has been only temporary (Ssali, 1973). Mortimer and coworkers (1937) evaluated the use of estrogen for this disorder in clinical trials and found that estrogen produced a marked improvement in most cases. Yadav and Seth (1979) used intranasal injection of placental extract, and found that 80% of their patients obtained dramatic and quick improvement clinically. And 65% of them have been asymptomatic for more than a year. Placental extract contains estrogen and progesterone.

In this study, the application of topical estrogen caused reversion of the atrophic epithelium (92.5% or 13/14), and improved the histologic quality of the nasal glands (64.3%). With improvement in the type of epithelium, other signs and symptoms improved consequently. Nasal crusting, dry nasal mucosa, halitosis, and anosmia improved. Estrogen is said to act by stimulating regeneration of diseased tissue, in this case producing normalization of nasal mucosa. Estrogen also promotes gland mitoses, thus the improvement of quality of serous/mucus glands.

However, no significant trend has been found to indicate the effects of estrogen on the quantity of glands and mucus blanket. The variable of sampling may be considered. Estrogen, however, is not found to affect the presence of inflammatory cells because in all, no change has been demonstrated.

In the control, all patients (11) reported disappearance of both foul odor and dry nasal mucosa. On follow-up visits, nasal crusting is still observed in 5/11 patients. None showed improvement of turbinates. No histologic evidence of epithelial improvement is observed. Likewise, no trend is seen with the quantity of glands, presence of mucus blanket. Degree of inflammation remains unchanged.

Regular nasal cleansing with alkaline solution is the basis of conservative treatment of atrophic rhinitis (Yadav and Seth, 1979). If the patient is prepared to carry out this simple treatment with unfailing regularity, freedom from offensive effluvia and crust formation can be achieved. The alkaline solution acts as a mucolytic and cleansing agent. Nasal washing helps to remove crusts, but they reform within 24 hours. The effects are mechanical and does not cause any clinical improvement in nasal mucosa and turbinates, nor reversion of epithelium.

The patients treated with topical estrogen are followed up till the present. They were asked to tape off washing and estrogen over a period of 2 months. The turbinates are still clinically improved, nasal crusting is very minimal, foul nasal odor is not often complained of, and anosmia is alleviated.

This study therefore concludes that topical estrogen has a place in atrophic rhinitis therapy. Clinical and histologic evidence support this.

CONCLUSION

A randomized study on the clinical and histologic effects of topical estrogen on atrophic rhinitis has been presented. The various histologic features of atrophic rhinitis were described. Topical estrogen significantly improved the clinical and histologic picture of atrophic rhinitis as compared to the control. It is recommended

that topical estrogen cream be applied daily together with alkaline nasal washing for a period of one month, and gently tapered off in a period of 1-2 months. Regular monthly follow-up is advocated.

Table I. Chief complaints.

Chief complaint	# of patients with complaint	Percentage
foul nasal odor	8	25.0
anosmia	6	18.7
nasal obstruction	5	15.6
crusting	5	15.6
frequent colds	4	12.4
headache	3	9.4
productive cough	1	3.2
Total	32	99.9

Table II. Clinical manifestations (signs and symptoms)

nasal crust
foul odor
atrophic turbinates
headache
anosmia
dry nasal mucosa
mucopurulent discharge
halitosis
dry or sore throat
postnasal discharge
blocked nose

Table III. % disappearance of signs and symptoms

Group	2 weeks with treatment (%)	2 weeks off treatment (%)
A	59.09	68.18
B	78.05	80.70

Table IV. Signs and symptoms 2 weeks with and 2 weeks off treatment in Group B.

Signs and symptoms	# of patients who reported disappearance (n=14)	
	2 wks w/ tx	2 wks off tx
nasal crust	12	10
foul odor	14	10
atrophic turbinates	12	10
headache	12	12
anosmia	14	10
dry nasal mucosa	14	10
mucopurulent d/c	12	8
halitosis	14	10
dry or sore throat	12	12
postnasal drip	8	4
blocked nose	5	5

Table V. Signs and symptoms 2 weeks with and 2 weeks off treatment in Group A.

Signs and symptoms	# of patients who reported disappearance (n=11)	
	2 wks w/ tx	2 wks off tx
nasal crust	6	5
foul odor	11	6
atrophic turbinates	0	0
headache	6	0
anosmia	5	11
dry nasal mucosa	11	5
mucopurulent d/c	7	0
halitosis	6	5
dry or sore throat	5	0
postnasal drip	5	0
blocked nose	5	0

Table VI. Changes in type of epithelium in improved cases treated with topical estrogen.

Pre-tx	2 wks w/ tx	2 wks off tx	# cases
squamous metaplasia w/ focal pseudostratified columnar	pseudostratified columnar w/ focal squamous metaplasia	atrophy w/ focal pseudostratified columnar	2
squamous metaplasia w/ focal psuedostratified	pseudosratified columnar w/ focal squamous metaplasia	pseudostratified columnar w/ focal atrophy	6
atrophic w/ focal squamous metaplasia	squamous metaplasia w/ focal pseudostratified columnar	squamous metaplasia w/ focal atrophy	2
atrophic w/ focal squamous metaplasia	squamous metaplasia w/ focal pseudostratified columnar	pseudostratified columnar w/ squamous metaplasia	2

Table VII. Changes in type of epithelium in Group A cases

Pre-tx	2 wks w/ tx	1 mo of tx	# cases
squamous metaplasia w/focal atrophy	squamous metaplasia w/ focal pseudostratified columnar	squamous metaplasia w/ focal atrophy	4
psuedostratified columnar w/ squamous metaplasia and atrophy	squamous metaplasia w/ focal atrophy	pseudostratified columnar w/ focal atrophy	3
atrophic w/ focal squamous metaplasia	atrophic w/ focal squamous metaplasia and pseudostratified columnar	atrophic w/ focal squamous metaplasia	4

Table VIII. Histologic changes in quality of glands in Group B (topical estrogen)

Pre-tx	2 wks w/ tx	2 wks off tx	# cases
atrophic w/ focal normal	atrophic w/ focal normal	normal w/ focal atrophy	3
atrophic w/ focal normal	normal w/ focal atrophy	normal	4
atrophic	normal	normal w/ focal atrophy	2
normal w/ focal atrophy	atrophic	normal w/ focal atrophy	1
normal w/ focal atrophy	normal w/ focal atrophy	normal w/ focal atrophy	4

Table IX. Histologic changes in quality of mucus/serous glands in Group A.

Pre-tx	2 wks w/ tx	1 mo of tx	# cases
atrophic w/ focal normal	atrophic	atrophic w/ focal normal	5
normal w/ focal atrophy	focal atrophy	atrophy w/ focal normal	4
normal w/ focal atrophy	normal w/ focal atrophy	normal w/ focal atrophy	2

Bibliography

- Adam, J. Atrophic rhinitis. *J. of laryngology and otology* 49:375-395. 1934.
- Barton, R. et al. Familial atrophic rhinitis: a scanning electron microscopic study. *J. of laryngology and otology* 94:993-996. 1980.
- Barton, R. and J. Sibert. Primary atrophic rhinitis: an inherited condition? *J. of laryngology and otology* 94:979-983. 1980.
- Bernat, I. Ozena - a manifestation of iron deficiency. Oxford, Pergamon Press, 1965.
- Cruz, B. Atrophic rhinitis - use of erythromycin and bromhexine hydrochloride. *Phil. J. of Otorhinolaryngology*. 1980.
- Girgis, I.H. *Journal of laryngology and otology* 80:615. 1966.
- Goodman, W.S. and F.M. De Souza. Atrophic rhinitis. *Otolaryngologic clinics of North America* 6:773-789. 1976.
- Gray, R.P.E. et al: Primary atrophic rhinitis: a scanning electronic microscopic study. *J. of laryngology and otology* 93:985-992. 1980.
- Green, T.H. *Gynecology: essentials of clinical practice*. Little, Brown and Co. 1977.
- Hammond, C.B. and W.S. Maxson. Estrogen replacement therapy. *Clinical obstetrics and gynecology* 29:2,407-429. 1986.
- Jamir, J.C. et al. Atrophic rhinitis: histology and histological response to treatment. *Phil. J. of otorhinolaryngology*. 1980.
- Martin, P.L. et al. Systemic absorption and sustained effects of vaginal estrogen creams. *JAMA* 242:24, 2699-2700. 1979.
- Mortimer, H. et al. Atrophic rhinitis: constitutional factor and treatment with oestrogenic hormones. *Canadian Med. Assoc. J.* 37:445-456. 1937.
- Ssali, C.L. Atrophic rhinitis: a new curative surgical treatment (middle turbinectomy). *J. of laryngology and otology* 87:397-403. 1973.
- Strandbygard, E. Treatment of ozena and rhinopharyngitis chronica sicca with vitamin A. *Acta Otolaryngology Sup.* 95. 1956.
- Taylor, M. and A. Young. *J. of laryngology and otology* 75:574. 1961.
- Wi, Z.T. et al. Atrophic rhinitis: a bacteriologic study. *Phil. J. of otolaryngology-head and neck surgery*. 1980.
- Yadav, Y.G. and R.R.S. Seth. Treatment of atrophic rhinitis. *Ear, nose and throat J.* 58. 1979.
- Young, A. *J. of laryngology and otology* 81:515. 1967.

10, 20, 30 WHAT IS IT REALLY?*

Arsenio L. Pascual III, MD**

Introduction

Is it 10, 20, or 30? It all begins as an outpouching of the nasal mucosa in the third month of fetal life and continues thereon to develop, maturing at about the second decade of life — the maxillary sinus.

It has been the topic of discussion in the centuries past and will continue to be in the days to come. Studied and described by so many authors as to its volume and functions, it is interesting to note that they agree only in one aspect, that the maxillary sinus is the largest of the paranasal sinuses.

To compound the problem, we continue to use the volumetric measurements of the maxillary sinuses set forth by these same authors as our reference in our daily practice of our specialty. A disturbing question at this point would be: Are the values relevant to the Philippine setting?

* 3rd Prize-7th Scientific (Clinical) Research Contest in Otolaryngology held at the Manila Midtown Hotel on 30 October 1987

** Resident, Department of Otolaryngology, PLM-Ospital ng Maynila

Objective

1. To determine the average capacity of the maxillary sinus among Filipinos.
2. To determine if there is a difference between the capacity of the antra in an individual.

Materials and Methods

The prospective study done was composed of 15 patients, whose ages range from 20 yr old and above, and were admitted from February 1987 to 15 October 1987 at the Department of ORL-HNS, Ospital ng Maynila. All of these patients were found to have radiographically dense antra and underwent Caldwell-Luc operation for the first time. However, intraoperatively, their antra were found to be normal.

This study also included 10 adult cadavers for the purpose of comparison.

Intraoperative Measurements

The antra of the patients who conformed with the criteria stated above were measured intraoperatively.

The head of the patients were first positioned in a manner by which the antero-lateral wall of the antrum parallel the level of the operating table. The nasal cavities were then packed with vaselized nasal strips to ensure that no leakage would occur through the natural ostium. Caldwell-Luc operation was then performed. After hemostasis was achieved and the antrum dried with nasal strips, we then proceeded to measure the cavity using NSS tinged with gentian violet and a 30 cc syringe with a needle to minimize bubble formation inside.

The antrum was filled up till the solution was at the level of the brim of the opening made on the anterolateral wall of the antrum. This procedure was repeated thrice in all the subjects and the average obtained.

Cadaveric Measurements

The antra of 10 adult cadavers were also measured for comparative studies. Instead of using NSS, we opted to use corn starch solution

to ensure that it will not leak through the natural ostium and in case the antrum has any perforation.

Data and Results

Group I (Live Patients)

No.	Name	Age	Sex	Capacity (cc)
1.	M.C.	36	F	5.5
2.	M.M.	54	M	8
3.	E.L.	28	F	7.5
4.	B.B.	38	F	8.5
5.	W.S.	49	M	15
6.	A.M.	26	F	9
7.	E.T.	24	M	9.2
8.	F.O.	71	M	12
9.	R.R.	42	M	6
10.	L.C.	30	F	14
11.	B.P.	36	M	9.4
12.	S.C.	25	F	13.5
13.	A.C.	28	M	8
14.	M.R.	32	M	6.5
15.	G.C.	65	F	7

Range: Min. 5.5 cc Mean Ave. 9.27 cc
 Max. 15.0 cc SD \pm 2.89 cc

Group I (Cadavers)

No.	Sex	Capacity (left)	Capacity (right)
1.	M	12.5	12.3
2.	M	7.5	7.7
3.	M	25	25
4.	M	1.8	2
5.	M	8	8
6.	F	8	8.3
7.	M	10.3	10.3
8.	M	9.4	9.2
9.	F	7.8	7.5
10.	F	11	11.1

Mean Ave. 10.13 cc SD \pm 5.77 cc
 Mean Diff. 0.15 cc SD \pm 0.19 cc

Discussion

The study consisted of two groups with a total of 25 subjects, 15 of which were patients whose ages range from 24 to 71 yr old with average of 47.5 yr old. On the other hand, there were 10 cadavers whose ages could not be determined due to the unavailability of their records, but were presumed to be adults based on their physical developments.

Group I represents the 15 patients who underwent Caldwell-Luc operation. The range of the capacity of the maxillary antrum obtained from 5.5 cc which was the smallest to 15 cc, the biggest. The mean average derived being 9.27 cc with a SD of \pm 2.99 cc.

Group II consists of 10 adult cadavers wherein both antra were measured and compared to determine whether there would be any significant variation in the capacity of both antra in a single individual. The mean average of all the antra was 10.13 cc with a SD of \pm 5.77 cc and the mean difference being 0.15 cc and a SD of \pm 0.19 cc.

We then compared the two groups for any disparity between their antra. The average of Group I as stated above is 9.27 cc with a SD of \pm 2.99 cc against that of Group II which is 10.13 cc with a SD of \pm 5.77 cc.

Using the T-test method for statistical analysis, the results obtained are as follows:

The data collected revealed a highly significant difference between the volumetric measurement stated by the foreign authors as compared to the values obtained in this study.

The comparison between the left and right antra of the cadavers proved to be insignificant. This was done to prove that the antra are more or less of equal size to justify the representation of either antrum instead of both.

We then used the values of Groups I and II to determine if there would be any significant difference between the antra of the patients measured intraoperatively from that of the cadavers. No significant difference was noted statistically.

Conclusion

1. The difference between the volumetric measurements previously accepted and those obtained by this author is highly significant.

2. The difference between the capacity of the maxillary antra in the same individual is not significant.

Comments

As K.J. Lee stated in his book, *Essentials of Otolaryngology, Head and Neck Surgery*, "The maxillary sinus is the largest of the paranasal sinuses and has a volume of 15 ml."

Morris Human Anatomy states that "the adult capacity of the sinus is approximately 15 ml."

Henry Gray, in his book, *Anatomy of the Human Body*, states that "the adult capacity varies from 9.5 cc to 20 cc, average about 14.75 cc."

Paparella, on the other hand, expresses that "the usual adult maxillary antrum has a capacity of 30 ml."

This study was undertaken to show the anatomical discrepancy between what is reported by foreign authors and our findings in the laboratory.

The relevance of this study will only be apparent if one considers the statement of Paparella and Shumrick (Vol. I Otolaryngology) that, "the existence of the paranasal sinuses has never been satisfactorily explained" and quoting Mink (1915) that, "there is no convincing evidence to suggest that the paranasal sinuses serve any purpose whatsoever."

A glance of the human skull reveals that the cervical spine, which serves to carry the weight of the skull, is situated far posterior from its dead center. If one carries a heavy object, it is axiomatic that to make it lighter, the weight should be balance on each side of the fulcrum. Using a line passing coronally through the center for the foramen magnum as a fulcrum or axis, the skull tilts forward on account of its heavier anterior segment. What has evolutionary process provided for this anomaly? Either:

- A pull is exerted from the back to keep the head from sagging forward and this is effected by the four deep muscles of the back of the neck, namely:
 1. Splenius capitis
 2. Splenius cervicis
 3. Trapezius
 4. Semispinalis capitis
- Make provision for the cervical spine to be as close as possible to the anatomical center of the skull by utilizing the atlanto-

occipital protuberance as the actual fulcrum as these are anteriorly located to each side of the foramen magnum. These articulate with the lateral masses of the atlas or first which are the most bulky and solid parts of the atlas.

- Put a counterweight on the lighter half, which in this instance is represented by the occipital protuberance which obviously is inadequate.
- Lighten the heavier anterior segment by making hollow some of its bones and this is represented by the paranasal sinuses.

Of these different options, the last appears to be the most effective and in a future study, a member of our staff at the Department of ORL-HNS, Ospital ng Maynila will prove this to be so.

Bibliography

- Ballenger, J.J., M.S., M.D. The nasal accessory sinuses: diseases of the nose, throat, ear, head, and neck. 1985. 4-10.
- English, G., M.D., F.A.C.S. Anatomy and physiology of paranasal sinuses, *Otolaryngology*. 1984. 254-260, 267.
- Enriquez, A E., M.D. Personal communication.
- Gray, H., F.R.S. The accessory sinuses of the nose, anatomy of the human body. 1918. 998-1000.
- Lee, K.J., M.D., F.A.C.S. Anatomy of paranasal sinuses, *Essential laryngology*. 1983. 379-391.
- Paparella, M., M.D. and D. Shumrick, M.D. Anatomy of paranasal sinuses, textbook of Otolaryngology, Basic sciences and related disciplines. 1980. Vol. 1, 119-123.

**"AKALA KO LUGA LANG"
MOTHER'S MYTH, CHILD'S MALADY***

Eusebio E. Llamas, MD
Benjamin S.A. Campomanes, Jr.,
MD*****

Introduction

Otitis media is a potentially serious disease chiefly because of its complications which may threaten life and health. This has been recognized from antiquity when Hippocrates about 460 B.C. noted that "acute pain of the ear with continued high fever is to be dreaded for the patient may become delirious and die".

In a third world country like the Philippines where 49 million out of 58.7 million Filipinos comprising 70% of our total population live in absolute poverty, where malnutrition abound and health care is prohibited, predisposition to infections particularly of the middle ear can be very common.¹

Of the many patients seen at the Santo Tomas University Hospital Otorhinolaryngology Out-Patient Department everyday, one cannot help but notice the numerous cases of COM coming for consult. Of the 7,161 patients seen at the OPD from June to November 1987, 992 were diagnosed to have COM comprising 14%. Surprisingly, mothers of

patients with chronically draining ears, when asked why no previous consult was made would often say, "akala ko luga lang" ("I thought it was just a draining ear.")

It is the objective of this study to find out the attitudes of Filipino mothers, particularly the poor, towards the common "luga" or draining ear and ultimately educate them of erroneous beliefs.

Methodology

An initial prospective study composed of 800 mothers from all walks of life, different social and economic backgrounds were included in the study. A questionnaire divided into General Information, Health Practices, Knowledge of the Disease, and Exposure to COM was formulated, tested, and distributed to randomly chosen respondents. Descriptive statistical analysis to show an over-all general survey was done. With the motivating results of the initial study, a more detailed analysis of 200 respondents from Luzon's poorer population was made using the same methodology.

Results

In the initial prospective study of 657 respondents, 86% called the condition wherein mucus or pus drains from the ear "luga."

As to the cause of the draining ear, 3% attributed it to infection while 53% thought it was brought by the common cold.

As a general belief, 42% of the mothers will not consult if their children will even encounter "luga" and 14% believed it can cause deafness.

Most common reason for non-consultation were, they believe: 43% it will spontaneously disappear; 42% it will heal on its own.

In the more detailed study of 200 mothers from the poor population, 14% attributed "luga" to infection and 58% believed the condition was due to colds.

50.5% had varied answers like too much crying, excessive cleaning, frequent bathing, and breastfeeding.

* Presented at the 4th ASEAN Otorhinolaryngological Head & Neck Congress, Singapore

** Consultant, Department of Otorhinolaryngology, UST Hospital

*** Resident, Department of Otorhinolaryngology, UST Hospital

As to the effects of "luga" on the child, 58.5% thought it will cause deafness and 8.5% thought it will affect the child's educational ability.

31.5% of the population had children with "luga"; 56% consulted a health personnel; 19% treated the condition on their own; and the rest simply left it unattended.

The most common reason for non-consultation: 48% would heal spontaneously; 36% it's just a part of growing up.

68.5% of the mothers interviewed had no children experiencing the condition.

If these mothers were to observe "luga" in their children, 76% would consult a health personnel and 21% would treat the "luga" on their own.

Most mothers in this categorical class who will not consult a health personnel, 40% believed the condition would spontaneously disappear and 28% believed that "luga" was just a part of growing up.

Discussion

According to J. L. Paradise, a noted pediatric otolaryngologist, otitis media with effusion is one of the most common chronic conditions encountered in pediatric practice.² Persistent fluid accumulations in the middle ear continue to be a perplexing problem to otologists and pediatricians throughout the world, and the disease has important social, economic, and health care implications.

Although their over-all incidence is low, meningitis, brain abscess, and sigmoid sinus thrombosis as a complication of COM are still encountered frequently in the Philippines. But, more importantly, is the developmental and psychoeducational sequela of COM. The principal auditory consequence of the persistent draining ear is, of course, hearing loss and the most feared consequence of hearing loss in children is an adverse effect upon the development of speech, language and cognition, and eventually their intellectual and personality development.^{4,5} The impact of such consequences define clearly the importance of the disease to the individual and society.

The United Nations reported that otitis media was the most common cause of hearing loss in children. In a Philippine study made by Dr. Abelardo Perez on causes of deafness in children, he concluded that otitis media was the most common cause of hearing impairment in his study of 598 students.⁵

With the aforementioned reasons, it is important that causes of COM be immediately identified and treated for they can be reversible if treated early and properly. It becomes equally important that parents are aware of the dangers and consequences of chronically draining ears.

In the Time-Life book on Sound and Hearing, S. S. Stevens, et al, wrote and I quote "How precious hearing is, becomes clear, when it is lacking. A baby born blind or insensitive to pain usually surmounts his handicap to lead a useful life. A baby with hearing loss may be lost to mankind. The first steps of intellectual development are beyond his reach. The sounds of life — his mother's lullaby, the clatter of a rattle, even his own yowl of hunger — remain unknown. He will have difficulty imitating meaningful sounds because he cannot hear them. Unless heroic measures rescue him, he will never truly master his own language, he will live cut off from the human race. It is hearing with its offspring, speech, that gives man his superlative capacity to communicate; to pass along hard won knowledge, and so to rule an entire planet."⁶

Complications of COM are preventable if seen early by a medical practitioner and it is the mothers who often notice the disease first with its common sign "luga." The study vividly describe how ignorant some mothers are towards the draining ear. Hearing loss secondary to COM is very real and the implications of such mothers myths can truly be a child's malady.

Bibliography

1. Land, poverty, and politics in the Philippines by Miranda, Canlas, and Pritzel, Catholic Institute for International Relations, London, 1988.
2. Paradise, J.L. Pediatricians view of middle ear effusions: more questions than answers; *Otol Rhinol Laryngol* 84 (Suppl 19, S-19) 1975.

3. Paparella, M. et al. Silent otitis media, clinical applications; Laryngoscope 96, Sep 1986.

4. Zinkus, P. et al. Developmental and psychoeducational sequela of chronic otitis media; Am Journal Dis Child, Vol. 132, Nov 1978.

5. Perez, Abelardo. Causes of deafness in children; Philippine Journal of Otolaryngology H & N Surgery, 1988.

6. S. S. Stevens, et al. Sound and hearing: Life science library, Time-Life Books, 1969.

CONGRATULATIONS AND WELCOME

to the

**JOSE REYES MEMORIAL MEDICAL CENTER
Department of Otolaryngology - Head & Neck Surgery**

Newly Accredited Member of the PSO-HNS

CONDOLENCE TO

THE FAMILY OF

**DR. VICENTE SANTOS
(deceased)**

From: The Officers and Members of the PSO-HNS

A BLOODY DILEMMA JUVENILE NASOPHARYNGEAL ANGIOFIBROMA IN A FEMALE: A Case Report*

Elmo R. Lago, Jr., MD
Alejandro P. Opuencia, MD and
Teodoro P. Llamanzares, MD*****

Introduction

It is common knowledge that Juvenile Nasopharyngeal Angiofibromas have a preponderance for pubescent males. These vascular tumors which usually arise from the nasopharyngeal vault were almost exclusively reported in males both in foreign and local literatures. This will be the first locally documented case of Juvenile Nasopharyngeal Angiofibroma in a female.

Case Report

The patient is Zaida Ellao, 5-yr old, female, admitted for the first time at the UERMMC Department of Otolaryngology, Head and Neck Surgery, because of right nasal obstruction and epistaxis.

The patient was apparently well until 4 months prior to admission when she experienced bilateral epistaxis. There was no history of trauma, nor any intranasal manipulation. From then on, she had monthly episodes of epistaxis

* Presented at the Scientific Symposium on Interesting Cases held at Manila Midtown Ramada Hotel on 7 July 1989

** Resident, Department of Otolaryngology, Head & Neck Surgery, UERMMC

*** Assistant Professors and Consultants, Department of Otolaryngology, Head & Neck Surgery, UERMMC

which stops spontaneously. Nasal obstruction with mucoid discharge were apparent in the next few weeks. Medical consultation was sought two weeks prior to admission and a right nasal cavity mass was noted. Medications given did not afford any relief. Because of the persistence of the signs and symptoms, the patient was referred and subsequently admitted to the UERMMC.

Clinical examinations revealed a F/N, F/D, child, conscious, and not in any form of distress. Vital signs were all within normal limits. External examination of the nose showed widening of the right nasal bridge. Anterior rhinoscopy revealed the presence of a pinkish, fleshy, mass in the right nasal cavity which bled profusely on slightest manipulation. Posterior rhinoscopy was accomplished under general anesthesia and showed the posterior septum to be deviated to the left and the nasopharynx devoid of any masses.

Radiography of the paranasal sinuses showed a soft tissue mass density within the right nasal cavity displacing the septum to the left with effacement of the superolateral aspect of the lateral wall of the cavity. There was also noted haziness of the paranasal sinuses on the right. Angiography revealed a blush at the posterolateral wall of the right nasal cavity consistent with that of a vascular lesion. The main feeding vessel is the right internal maxillary artery.

The mass was subsequently embolized with Gelfoam and excised three days later via a lateral rhinotomy approach. The post-operative course was unremarkable.

Intraoperative Findings

A right nasal cavity mass was noted, described as predominantly reddish with some grayish patches. The borders were separated from the surrounding structures and the main stalk located at the posterolateral wall of the nasal cavity near the roof. The nasopharynx was devoid of any masses.

Histopathologic Findings

Gross description of the mass showed a specimen consisting of small irregular fragments of whitish to brownish tissues amounting to 5 cc in aggregate volume. Cut sections of the tissue also showed multiple irregular foci of red-brown hemorrhages.

Microscopic section showed a tumor composed of loose fibrous stroma arranged in a wavy pattern with interspersed gaping and slit-like vascular channels lined with a single layer of endothelial cells. Stromal cells are stellate in shape. Numerous monocular inflammatory infiltrates are scattered within the intervening stroma. The overlying epithelium is necrotic.

Discussion

Misdiagnosis of vascular tumors of the sino-nasal tracts and nasopharynx in children often occur, for most of these tumors present with similar characteristics. Moreover, a thorough examination of these tumors are quite difficult because of profuse bleeding. Preoperatively, one can only speculate. This puts the otolaryngologist in a dilemma: should he be aggressive or conservative? Our patient, because of age and sex, probabilities ranged from the most benign pyogenic granuloma to the most malignant rhabdomyosarcoma, hence a dilemma. To settle the issue, we opted for a biopsy with double set-up preparations in the operating room. This histopathological examination revealed Juvenile Nasopharyngeal Angiofibroma.

Juvenile Nasopharyngeal Angiofibroma (JNA) is a benign, highly vascular, locally invasive tumor. It is the most commonly encountered vascular mass in the nasal cavity. This tumor is not that uncommon, a UP-PGH study showed an incidence of 1.4% of all ENT admissions.¹ Most of the tumors manifest during adolescence, with patients ages ranging from 7-30 years with a median of 14 years. Although, these tumors have a sexual predilection for males, foreign literature have already documented cases in females. In the Philippines, however, no female case has yet been reported (see Table 1).

Table 1.

Author	Period	No. of cases	Sex
Caparas et al	1973-78	50	all males
Tuazon et al	1979-83	12	all males
Bautista et al	-	4	all males
UERMCC	1980-89	4	all males

In the strict sense, juvenile angiofibroma does not arise from within the nasopharynx. The specific point of origin being on the postero-

lateral wall of the roof of the nose, where the sphenoidal process of the palatine bone meets the horizontal ala of the vomer bone and the root of the pterygoid process. This junction forms the superior margin of the sphenopalatine foramen and the ethmoid crest (or the attachment of the posterior end of the middle turbinate). This site of origin has led some authors to suggest that JNA would be more appropriately identified as a Juvenile Postnasal Angiofibroma.²

The etiology of these tumors are still uncertain. However, several theories have been proposed and they are: (1) deficiency of androgen activity or an overproduction of estrogen, (2) deviation from the embryonic cartilage during the development of the skull, (3) as an ectopic nidus of vascular tissue lying unilaterally at the origin of the sphenopalatine foramen awaiting stimulation by endogenous testosterone,³ and (4) from large endothelial-lined spaces about the origin of the foramen and the base of the pterygoid plates.⁴

The growth of these tumors follow a natural course.² The tumor grows just inside the posterior choanal margin on the roof laterally. It enlarges reaching the posterior border of the septum extending downward along its margin. The tumor then grows forward to fill the nasal cavity, displacing the septum to the opposite nasal cavity and flattening the turbinates. From here, the tumor fills the nasopharynx displacing the soft palate. As the tumor grows further, it enters the pterygomaxillary fossa through the sphenopalatine foramen. Here, it can affect the posterior wall of the maxillary sinus (anterior wall of the fossa), or grow laterally and manifest itself as bulge in the cheek. It can grow superiorly and affect the orbit. In about 80% of patients, the tumor can also grow straight upward from its origin to affect the sphenoid sinus. The rate of spread is unknown.

Microscopically, the tumor has two striking features: a fibrous stroma and a rich vascular network. These components, however, are not diagnostic for they are also components of other lesions like pyogenic granuloma, polyps with chronic fibrovascular laterations or even a normal turbinate with its prominent vascularity. JNA, however, follows a pattern which is distinctive enough to allow specific histologic recognition.⁵ There is the presence of the slit-like (long and thin) vascular channels uniformly distributed in a given area. The stromal col-

lagen often has a wavy pattern. The stromal cells often have a stellate shape. But the most important feature is that the vessels are devoid of elastic and muscular fibers and are filled with blood. This readily explains the presence of severe hemorrhage even when the tumor is touched lightly.⁶

The clinical signs and symptoms presented by JNA are characteristic but they are by no means diagnostic. Nasal obstruction which, if unilateral and moderate in degree, may go unnoticed for sometime; the tumor may, therefore, reach a significant size to cause deformity before any consultations are made. Epistaxis is recurrent and usually severe and most often caused by the slightest trauma or even sneezing. Nasal discharge initially is watery or mucoid becoming purulent when there is secondary infection from the paranasal sinuses. Rhinolalia clausa and anosmia complete the clinical picture.

Many modes of imaging are utilized to supplement diagnosis and determine the therapeutic approach. Radiography of the paranasal sinuses, computerized tomography, and angiography are all invaluable preoperatively. Angiography is particularly important in determining the tumor blood supply and by providing access for preoperative embolization.

Numerous treatment methods are described. The use of cryotherapy, sclerotherapy, electrocoagulation, chemotherapy, and permanent embolization were utilized for both definitive and adjunctive therapy. Cummings presented fairly convincing statistics to support the use of radiation therapy, however, it is not without its cumulative risk plus the chance of developing a radiation-induced cancer.¹² Because of the relative accessibility of these tumors, surgery with complete removal is the only way to obtain radical cure. Strategies are based on the site and extent of tumor invasion. Caparas et al reported a number of surgical approaches to the tumor varying from the transpalatal, lateral rhinotomy, transmaxillary, and Weber-Ferguson.

Prognosis is fairly good. Batsakis reports recurrences occurring in about 50% of patients and a mortality of only 3%. Recurrences occur within the first twelve months after therapy.

Comparing the features of our patient to a typical male with Angiofibroma, only one difference is noted (see Table 2). This was also

Table 2.

	UE patient	Typical male
<u>Clinical presentation</u>		
triad of symptoms: (nasal obstruction, recurrent epistaxis, nasal discharge)	present	present
tumor bleed easily on manipulation	present	present
signs related to tumor size (located in nasal cavity): displacement of septum to the opposite side, flattening of the turbinates, widening of the nasal bridge	present	present
<u>Origin on posterolateral wall near the room</u>		
	same	same
<u>Location</u>		
	mainly in nasal cavity	presents with a nasopharyngeal component
<u>Laboratory data</u>		
Angiography (main feeding vessel)	internal maxillary artery	internal maxillary artery
<u>Histopathologic data</u>		
Microscopically, fibrous stroma - wavy stroma cells - stellate slit-like vascular channels	present present present	present present present
vascular walls devoid of elastic/muscular fibers	present	present
presence of inflammatory cells	may be present	may be present

raised by Heffner. ** He points out that the location of the tumor is not typical of an Angiofibroma, stating that the Angiofibromas have a nasopharyngeal component and not solely found within the nasal cavity. Let us recall the natural course of the tumor, it first fills the nasal cavity before extending into the nasopharynx. It is highly possible, therefore, that the patient was diagnosed early enough that the tumor has not yet extended into the nasopharynx. Had we waited for another two years, the tumor would not only have filled the nasopharynx but would also fall within the age bracket.

Based on the clinical features, laboratory data, gross and histologic morphology and after a thorough review of existing literature, it is without doubt that this female has indeed a Juvenile Angiofibroma.

Summary

A case of Juvenile Nasopharyngeal Angiofibroma in a female is reported for the first time in the Philippines. Its clinical as well as pathological features have been described and discussed and it has been shown to simulate the Angiofibromas observed in males.

** Personal correspondence with Dr. Heffner

Bibliography

1. Caparas, M., T. Jardeleza, and J. Flor. Surgical management of nasopharyngeal angiofibroma with pterygoid extension. *The Phil. J. of Otolaryngol., Head and Neck Surg.*, 349-351, 1985.
2. Neel, B., J. Whicker, K. Devine, and L. Weiland. Juvenile angiofibroma: a review of 120 cases. *The American J. of Surgery*, 126:547-555, Oct 1973.
3. Bautista, A. and R. Nanagas. Experiences in the management of juvenile nasopharyngeal angiofibroma. *Phil. J. of Ophthal. and Otolaryngol.*, 12:120-126, Oct-Dec 1960.
4. Harrison, D. The natural history, pathogenesis, and treatment of juvenile angiofibroma. *Arch. of Otolaryngol., Head and Neck Surg.*, 113: 936-942, Sep 1987.

5. Heffner, D. Problems in pediatric otorhinolaryngic pathology II, vascular tumors and lesions of the sinonasal tract and nasopharynx. *Int. J. of Pediatric Otorhinolaryngol.*, 5:125-138, 1983.

6. Acuna, R. Juvenile nasopharyngeal fibroma. *Ann. of Otolaryngol.*, 90:420-421, 1981.

7. Tuazon, R., C. Villafuerte, A.M. Espiritu, E. Guevara, and E. Panganiban. Pre-operative embolization in juvenile nasopharyngeal angiofibroma. *The Phil. J. of Otolaryngol., Head and Neck Surg.*, 305-308, 1985.

8. Lopez, J.E., R. Tuazon, and M. Caparas. Boiling water as an adjunct in the treatment of angiofibroma: a case report. *The Phil. J. of Otolaryngol., Head and Neck Surg.*, 305-308, 1985.

9. Osborn, D.A. and A. Sokolovski. Juvenile nasopharyngeal angiofibroma in a female. *Arch of Otolaryngol.*, 82:629-632, Dec 1965.

10. Svoboda, D. and F. Kirchner. Ultrastructure of nasopharyngeal angiofibromas. *Cancer*, 19:1949-1961, Dec 1966.

11. Witt, T., J. Shah, and S. Sternberg. Juvenile nasopharyngeal angiofibroma: a 30-yr clinical review. *The Amer. J. of Surg.*, 146:521-525, Oct 1983.

12. Chen, Karl and F. Bauer. Sarcomatous transformation of nasopharyngeal angiofibroma. *Cancer*, 49:369-371, 1982.

13. Goepfert, H., A. Cangir, A. Ayala, and F. Eftekhari. Chemotherapy of locally aggressive head and neck tumors in the pediatric age group: desmoid fibromatosis and nasopharyngeal angiofibroma. *The Amer. J. of Surg*, 144:437-444, Oct 1982.

14. Waldman, et al. Surgical experience with nasopharyngeal angiofibroma. *Arch. of Otolaryngol.* 107:677-682, Nov 1981.

15. Davis, K. Embolization of epistaxis and juvenile nasopharyngeal angiofibromas. *Amer. J. of Radiology*, 148:209-218, Jan 1987.

16. Personal correspondence with Dr. Dennis K. Heffner, Capt, MC, USN Chairman, ENT Pathology Department, Department of Defense, Armed Forces, Institute of Pathology, Washington, DC.

UNCLASSIFIED CLEFT*

Liberty Acedillo-Monleon, MD**
Abelardo Perez, MD and Robie
Zantua, MD***

Unclassified Cleft

There are only 8 reported cases of facial cleft with cleft nose in the world literature as of 1977. In this case report, the facial cleft involving the upper lip and left alae nasi defies the standard classification.

Report of Case

A 5-yr old boy was seen because of facial cleft (Fig. 1). History revealed no unusual prenatal factors nor birth trauma. Family history revealed patient's grandfather with cleft lip.

Patient was born with the bilateral facial cleft with incomplete cleft on the right and complete cleft on the left side. The nasal cleft was classified as cleft no. 2 in the Tessier's classification (Fig. 7). He had a complete bilateral or cleft of the primary and secondary palate (Fig. 2).

At age 7 days old, the parents sought consultation for necrosis of the left nostril which persisted despite treatment with antibiotics. There was progression of necrosis until it became a cleft extending from the rim to the lateral sulcus of the alae nasi (Fig. 3).

The patient has concomitant lop ear on the left side.

Management

Two months ago, he had undergone the first stage reconstruction of the nose (Fig. 4). The nasal cleft incised and coaptated.

The cleft lip was repaired using the Barsky Technique (Fig. 5). The lateral lip elements are freshened by turndown of the vermilion flaps (Fig. 6-A). Sides of prolabium are freshened and the inferior vermilion turned down. Mucosa of the lateral lip elements were sutured together (Fig. 6-B). The prolabium was replaced and the vermilion flaps overlap the turndown or the prolabium vermilion (Fig. 6-C). The patient was fitted with dorsal prosthesis 2 weeks post-op.

A second stage will be done after 6 months to close the cleft palate and repair the left alae nasi with a cartilage graft from the left ear. The lip will likewise be corrected. Lengthening of the columella will also be apart of the second stage repair.

Discussion

Facial cleft with cleft nose are extremely rare with 8 reported cases in the world literature in contrast to common facial clefts with nasal deformity described as distorted position and shape which occurs once in every 1,300 births. According to Johnson, Vieau, etc. the current concepts concerning the origin of the cleft lip nose deformity suggest the presence of intrinsic disturbances of growth and development as opposed to extrinsic forces postulated by Blair, Giller, etc.

Sadove, et al in 1987 in his effort to study the cartilaginous histology of cleft lip nose without disregard to the theory of Johnson, Vieau, etc. postulated that the nasal deformity is not due to intrinsic abnormalities of the nasal tissue but rather ensue from extrinsic abnormal vectors of force in utero resulting from discontinuity of the perioral musculature.

* Presented at the Scientific Symposium on Interesting Cases held at Manila Midtown Ramada Hotel on 7 July 1989

** Resident, Department of Otorhinolaryngology, PHMC

*** Consultants, Department of Otorhinolaryngology, PHMC

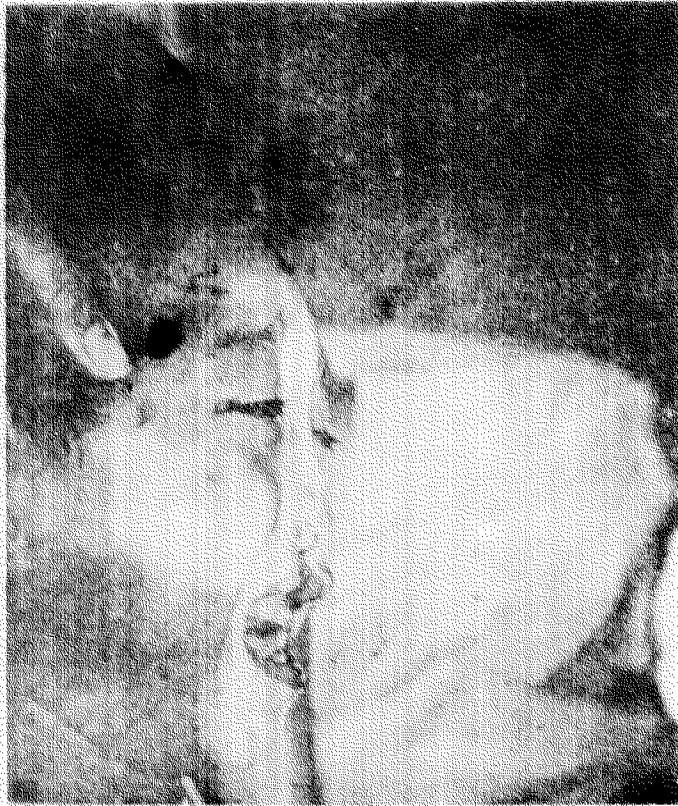

Figure 1. Bilateral cleft lip with cleft nose and cleft palate.

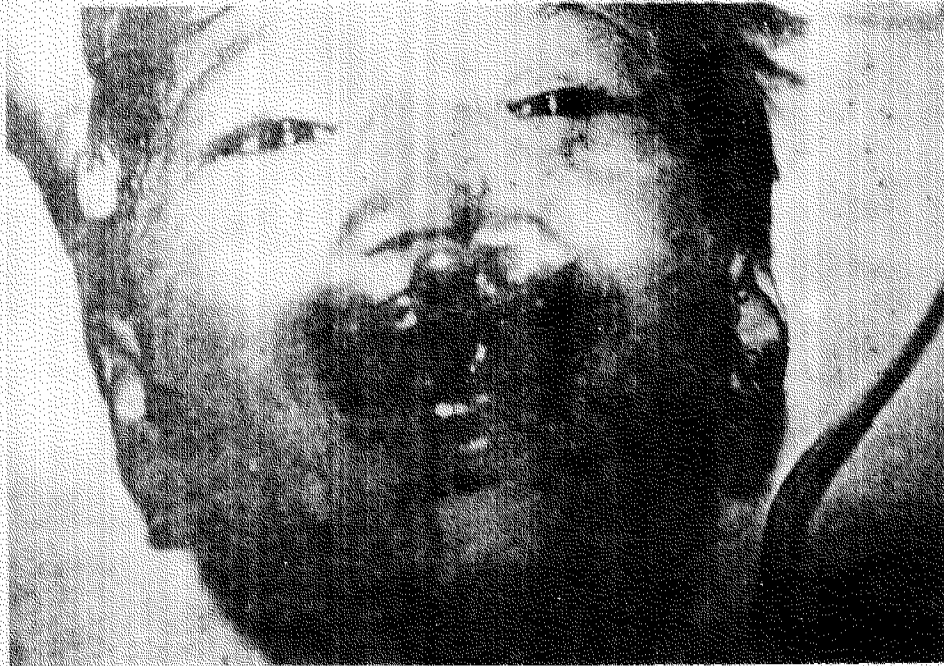

Figure 2. Complete bilateral cleft palate.

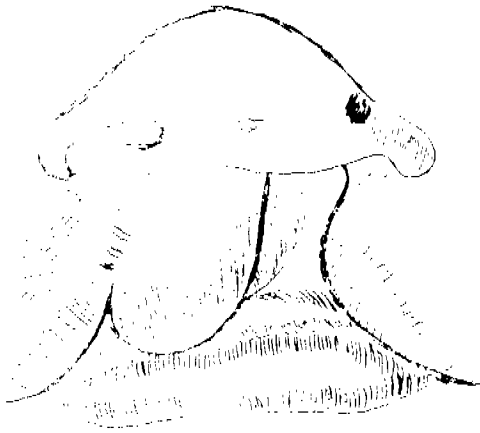


Figure 3-A. Formation of necrosis.

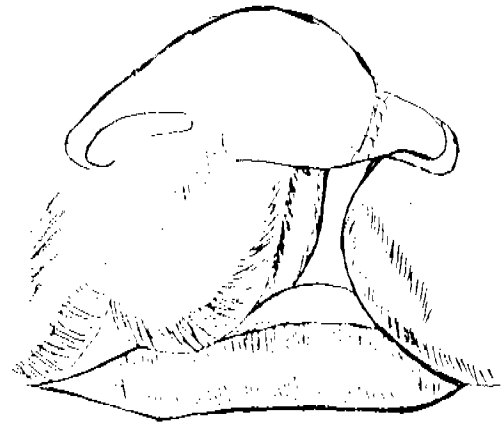
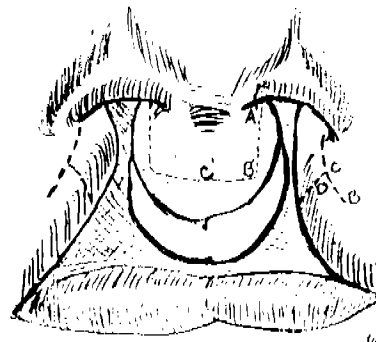


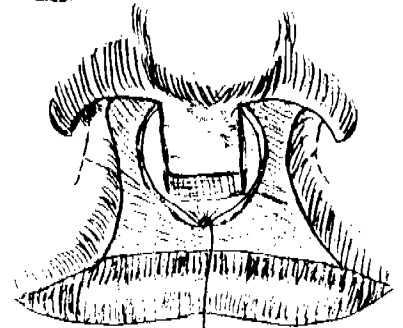
Figure 4. First stage nose reconstruction. The nasal cleft incised and coaptated.

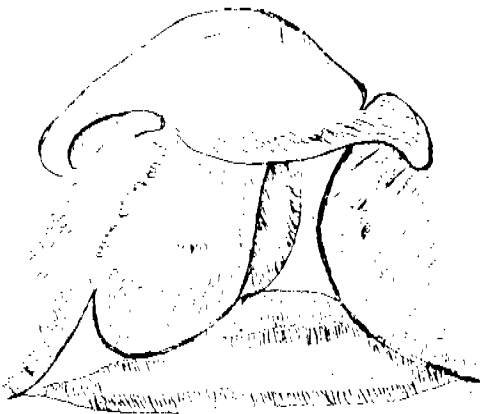

Figure 3-B. Formation of groove.



A



B


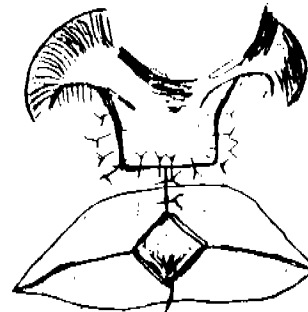


Figure 3-C. Formation of cleft.



C

Figure 5. Barsky's Technique in bilateral cleft lip repair.

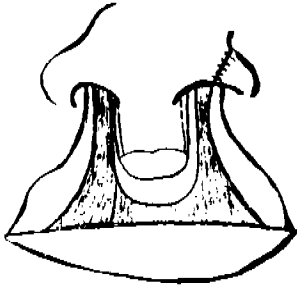
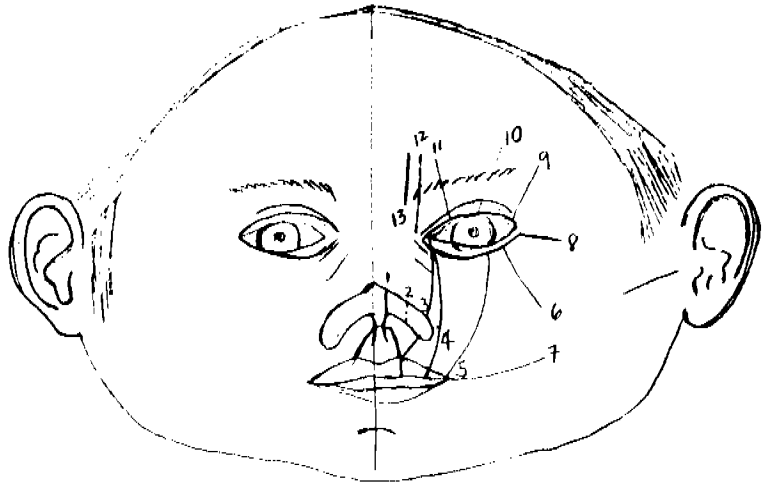


Figure 6-A.

The lateral lip elements are freshened by turndown of the vermilion flaps.



Location of clefts on the face.

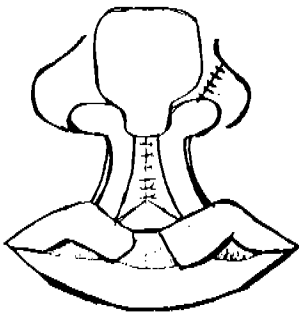
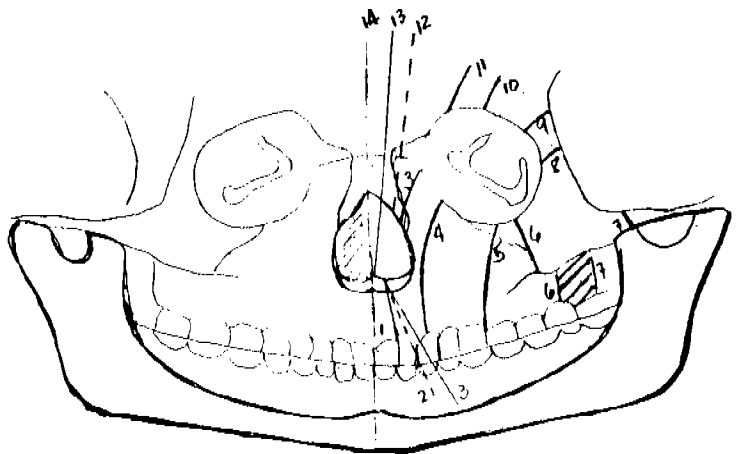


Figure 6-B.

Mucosa of the lateral lip elements are sutured together.



Skeletal pathways of clefts.

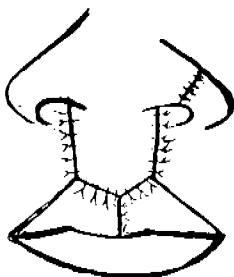


Figure 6-C.

Prolabium is replaced and the lateral vermilion flaps overlap the turndown or the prolabium vermilion.

Figure 7. Tessier's Classification of Facial Clefts with underlying skeletal deformity.

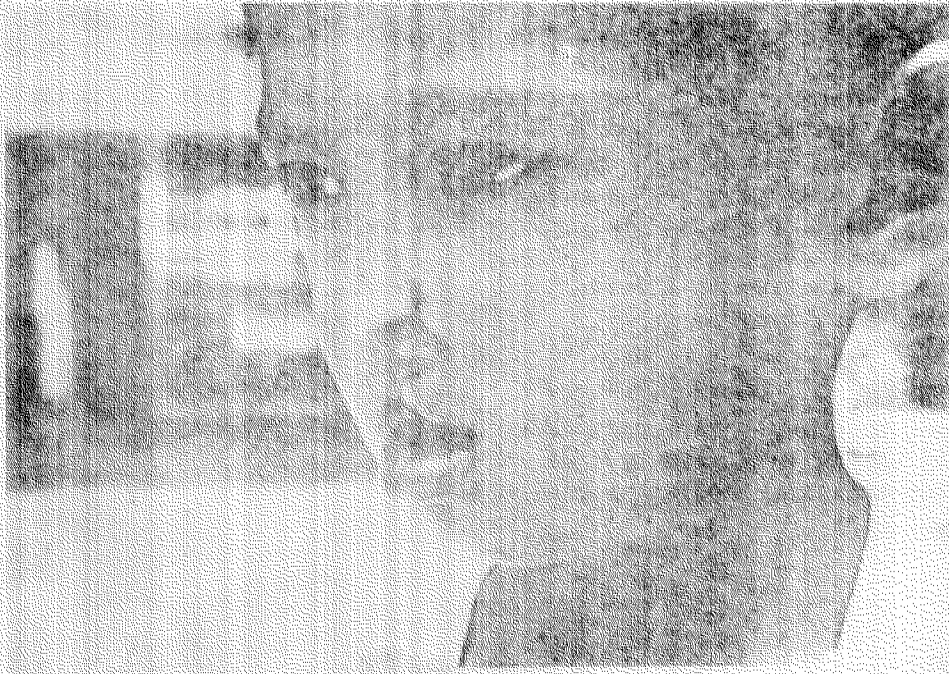
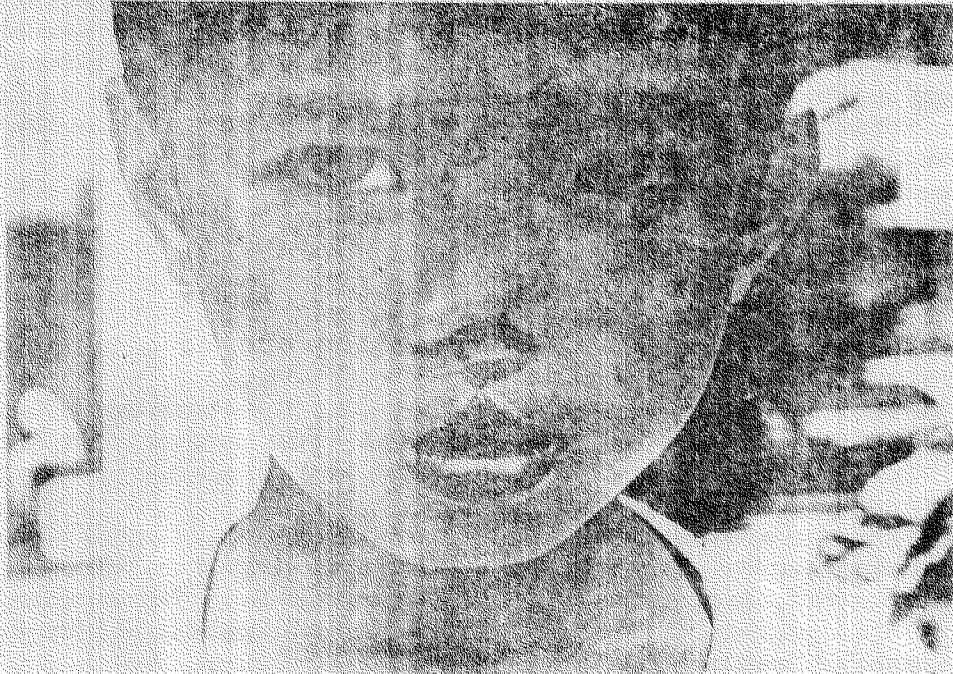
Figure 8. Post-operative appearance of bilateral cleft lip repair and nose reconstruction.

The 8 reported cases were identified on patients with rare craniofacial clefts. The occurrence of rare craniofacial clefts were explained by the fusion theory of Dursy and migration-penetration theory by Warbrick. However only the work of McKenzie and Craig clarifies the postnatal existence of the nasal cleft. In 1955 they did a postmortem dissection of a 10-week old newborn with Treacher Collins Syndrome and found that the maxillary artery have "petered out" before it reached the pterygomaxillary tissue. This brings about a deformity of the zygoma, middle ear, and the muscles of mastication. They were the ones who associated inadequate blood supply occurring at the time of rapid growth and development. Therefore areas not adequately supplied with blood during growth and development may form a cleft natal and postnatal. This theory probably explains the postnatal formation of the nasal cleft in this particular case. The patient was born with bilateral cleft lip. The cleft nose appeared probably as necrosis.

Based on Tessier's classification of craniofacial cleft which was presented before the Second International Congress of Cleft Palate, this patient is classified under cleft no. 2 (Fig. 7). The location of the deformity on nostril rim is its distinct feature. However, the absence of other features as hypertelorism, broad nasal bridge, distortion of the eyebrow and location of the eyebrow coloboma makes him a variant of this classification. Despite the good work of Tessier, questions still exist as to whether this cleft is a distinct deformity or a transitional form between clefts no. 1 and 3. With the absence of other associated features as of cleft no. 2, this patient probably belongs to a transitional form between cleft no. 1 and 2.

It is hard to classify rare craniofacial clefts not only because they exist in multitude of patterns but they also vary in degree of severity.

Conclusion

The most probable cause of postnatal nasal cleft in our patient is inadequate blood supply of the nasal rim. Using Tessier's classification, the patient belong to a transitional form between cleft no. 1 and 2.

Summary

A case of a 5-yr old boy congenital bilateral cleft associated with postnatal nasal rim cleft. Ischemia has been implicated as the probable cause of nasal cleft. Surgical management discussed. Classification based on Tessier's Classification System.

Bibliography

- Chiong, A., E. Guevarra, and R. Zantua. Oblique facial cleft. Archives of otolaryngology. Vol. 107, Jan 1981, pp. 59-62.
- Cronin, Thomas. The bilateral cleft lip with bilateral cleft of the primary palate, in Converse JM (ed.). Reconstruction and plastic surgery. Philadelphia, W B Saunders Co., 1977, Vol. 4, Chapter 44.
- Kawamoto, H. Jr., M. Wang, and W. Macomber. Rare craniofacial clefts, in Converse JM (ed.) Reconstructive and plastic surgery. Philadelphia, W B Saunders Co., 1977. Vol. 4, Chap. 46.
- Millard, Ralph. Cleft lip, in Grabb and Smith (ed.). Plastic surgery. Boston, Little, Brown and Co., 1979, pp. 192-203.
- Sadove, R. Leopoldo Ladaga, and William Magee. Cartilaginous histology of the cleft lip nose: Proving the extrinsic etiology. Plastic and reconstructive surgery, May 1988. pp. 655-660.

ENDOSCOPIC SINUS SURGERY: UST EXPERIENCE (Review of 39 Cases)

**Benjamin S.A. Campomanes, Jr.,
MD***
Eusebio E. Llamas, MD**

Abstract

A review of 39 patients who underwent Endoscopic Sinus Surgery by the author from November 1988 to June 1989 is presented. Indications for surgery varied from recurrent sinusitis as a result of anatomic abnormalities and/or mucosal changes within the osteomeatal unit (23 patients) to patients with massive polyposis and chronic sinusitis (16 patients). Discussion will be focused on the technique as described by Messerklinger, Stammberger and Kennedy, the difficulties in polyp surgery, complications such as bleeding requiring packing (6 patients), mucosal adhesions (7 patients), retained polyps (7 patients), and overall result of the surgical intervention.

Introduction

Never has there been in the history of Otolaryngology much attention given to the anatomy, physiology, and surgical therapy of the paranasal sinuses. With endoscopy, Messerklinger was able to formulate a sound and reasonable principle of mucociliary clearance and redefine the mode of treatment and surgical technique in dealing with chronic and recurrent sinusitis.^{1,2,7} The rationale of the approach has been well summa-

* Resident, Department of Otorhinolaryngology, UST Hospital

** Consultant, Department of Otorhinolaryngology, UST Hospital

rized by Stammberger — most paranasal sinus infection are rhinogenic; recurring sinusitis is secondary to insufficient outflow of the natural ostia of the sinuses; the sites of obstruction is usually at the osteomeatal unit (OMU). As in all new procedures, the introduction of this surgical technique requires time and experience to acquire the skills necessary to obtain adequate results. The objectives of this study are to evaluate the state of endoscopic sinus surgery as experienced by the author, to define the limitations of endoscopic diagnosis without ancillary procedure, to emphasize the need for proper instrumentation, to state the complications encountered, and finally to address future endoscopists as to the value of proper training.

Materials and Methods

All patients who underwent endoscopic sinus surgery by the author from November 1988 to June 1989 were included in the study. All surgeries were done using Storz Hopkins telescopes, forceps, scissors, and curettes. The technique as advocated by Messerklinger, Stammberger, and Kennedy was utilized. The nasal chamber is topically decongested and anesthetized. If and when the middle turbinate blocked the middle meatal area, it was subluxated medially. The surgical areas were then injected with lidocaine-epinephrine solution. Whenever the middle turbinate obstructed visualization, the anterior inferior portion is resected. Surgery then proceeded to infundibulotomy, anterior ethmoidectomy, posterior ethmoidectomy, sphenoidectomy, depending on the extent of diseased tissues. Identification of the maxillary ostium is done, then subsequently enlarged. The maxillary antrum was inspected, irrigated with normal solution and whenever necessary Caldwell-Luc performed. All mucosal bleeding were controlled with cottonoids dipped in oxymethazoline solution. Finally, steroid/antibiotic cream was applied over the surgical field.

Results

A total of 39 patients underwent endoscopic sinus surgery by the author at the Santo Tomas University Hospital Clinical Division within a period of 9 months. All patients complained of chronic or recurrent symptoms of nasal congestion, nasal discharge, and postnasal drip. Of these patients, 27 experienced facial headache,

26 had anosmia, and 1 complained of intractable halitosis (Table 1). Six patients had previous nasal operations. The results of each endoscopic examination are shown in Table 2.

Only patients with 2 or more follow-up were evaluated for results of surgery. Nine patients were subsequently lost to follow-up.

Table 1. Symptoms experienced by the patients
N=39

Symptom	No. of patients
nasal discharge chronic/recurrent	39
nasal congestion	39
post-nasal drip	39
facial headache	27
anosmia	26
halitosis	1

Table 2. Results of endoscopic examination

Left nose		Right nose	
Endoscopic findings	No. of points	Endoscopic findings	No. of points
Diffuse polyposis	16	Diffuse polyposis	15
Bulging infundibular wall	6	Bulging infundibular wall	2
Enlarged bulla	2	Enlarged bulla	4
Medially bent uncinata	1	Small polyps	10
Small polyps	13		
Synechiae	1		

Minor problems within OMU

Out of 39 patients, 23 had relatively minor lesions in the OMU. Postoperatively, 5 patients were completely relieved of their symptoms. Ten still complained of occasional nasal congestion while 3 had persistent nasal discharge and post-nasal drip. Four of the 6 complaining of anosmia were relieved. Only 1 of the 17 complaining of facial pain was not relieved. Complications revealed 1 patient with adhesions and 1 with retained polyps. Both patients underwent revision surgery.

Diffuse polyposis (16 patients)

After maximum topical decongestion, epinephrine-lidocaine mixture was injected over the polyps. An incision over the inferior pole of the polyp oftentimes facilitated decompressing the mass. If possible, the polyp was removed from its base, otherwise piecemeal removal starting from the most inferior/posterior portion was one until the middle turbinate became visible. The middle turbinate in all patients was located hugging the septum and, in all cases, the uncinata process was pushed medially. The only constant landmark in diffuse polyposis was the middle turbinate. All visible polyps were removed until normal mucosa was encountered, or the depth of the scope reached a level of about 6.5 cm superoposteriorly, the dome of the ethmoid identified superiorly, lamina papyracea laterally. Only on 7 noses were these landmarks seen all together. Intraoperative decision as to condition of antral mucosa as being polypoid necessitated Caldwell procedure in 3 patients. Immediate postoperative complications showed 5 patients requiring collagen packing, two in which turbinectomy was performed and 2 others had previous polypectomies. Postoperative evaluation showed that 2 patients were completely asymptomatic, 8 patients complained of persistent nasal discharge and postnasal drip. Anosmia was relieved in 7 out of 11 patients complaining of this symptom. All 6 patients complaining of headache preoperatively were relieved of this symptom. Postoperative complications were seen in 6 patients with retained polyps and in 4 patients with adhesions. Four of these patients underwent revision surgery.

Table 3. Results: therapeutic success

Outcome	OMU N=19	Diffuse polyposis N=11
Asymptomatic	5	2
Partial relief:		
Nasal congestion	10	0
Nasal discharge/ postnasal drip	3	0
Anosmia	2	7
Headache	1	0
No improvement	0	0

Table 4. Complications

Complications	OMJ N=19	Diffuse polyposis N=11
Immediate:		
Bleeding requiring packing w/ collagen	1	5
Post-op		
No complication	17	4
Major	0	0
Minor: retained polyps adhesions	1 1	6 4
Patients requiring repeat operation	2	7
Patients who underwent repeat operation	2	4

Discussion

The use of endoscopes has several advantages compared to conventional surgical techniques. With improved visualization brought about by better illumination and angulated scopes, surgery and removal of all stenotic clefts and diseased areas from the pre-chambers of the paranasal sinuses is meticulously performed. The patient is spared the additional trauma to normal structures. The advantage of CT scan to pinpoint the pathology cannot be overemphasized. It complements or detects lesions and air cells hidden beyond the reach of the endoscope. Without the benefit of a CT scan, there remains some doubt as to completeness of surgery. Although cost prohibitive, it would seem cheaper in the long run considering the possibility of repeated surgeries as in several of our cases.

Proper instrumentation is imperative. The angulated scopes are indispensable. In 13 noses, the peculiar anatomy of a sloping lateral nasal wall rendered the back biting forceps useless. Polyps hanging over the frontal recess and maxillary ostium were on occasions beyond the reach of the upbiting forceps. It is to be emphasized that the 0° telescope, although less panoramic than the 30° wide angled scope, should be used in most of the surgeries to facilitate orientation. When using a 30° telescope, one should be con-

stantly aware that he is not looking where one is pointing. In operating fields beyond the middle turbinate, oftentimes no landmark is constant, therefore, the position of the scope in relation to the whole skull becomes critical.

Messerklinger and Stamberger state that all kinds of recurrent sinusitis can be treated with minor surgical procedures. The dependent larger sinuses are usually not touched. To them, even massive mucosal changes in the maxillary sinus — which up to now were thought to be irreversible, usually heal within 4-6 weeks after drainage and ventilation has been established. The problem is that there are no clear cut rules grossly or microscopically as to when mucosal changes are reversible or irreversible. In patients with massive polyposis with pre-operative and post-operative x-rays, some conclusions were gathered. First, some mucosal thickening may not be reversible or may take longer than 6 weeks to heal even with large patent ostia. Second, although mucociliary flow in non-pathologic cilia always beat towards the natural ostium, diseased mucosa will not follow this rule. Therefore, the need for an inferior meatal antrostomy while the diseased often secretory mucosa is given time to heal, unless the natural ostium is cannulated often and irrigated to clean the maxillary antrum.

Retained polyps as an operative complication can be avoided by more meticulous dissection using the angulated scope, by proper control of bleeding with topical vasoconstrictors and using the most atraumatic technique. They can be managed later as an out-patient procedure. One other frustrating complication experienced by different authors has been adhesions. Synechia formation tend to occur between the middle turbinate and lateral nasal wall. This leads to obstruction of the outflow of the sinuses and consequently, sinusitis. Although this may be the case in most patients undergoing intranasal ethmoidectomy, it is only now that this complication and its significance is being appreciated. Adhesions may be prevented by adequate removal of loosed bone and tissues over the meatal area, prevention of trauma to the lateral surface of the middle turbinate, removal of part of the middle turbinate placing stents over the middle meatus, and probably the most important, meticulous cleaning of the operative areas until mucosal healing is evident.

There is no doubt in the author's mind that the technique is superior to any other conventional surgery of the nose and paranasal sinuses. However, for future endoscopist to obtain better results compared to other surgical techniques, the following are recommended:

1. One should know the principle by which the technique was developed.
2. Repeated cadaver dissection is a must.
3. The endoscopes are initially used in the office to establish familiarity with both anatomy and instruments.
4. It is advisable to start with relatively minor lesions.
5. As the endoscopist gains greater surgical experience and confidence, he may operate on diffuse polyposis.

With the advancements in optics and micro-surgical instruments, Mosher's admonition that intranasal ethmoidectomy is the "blindest and most dangerous operation in all surgery" may or may not hold true depending on how the endoscope are used.

6. Stamberger, H. **Nasal and paranasal sinus endoscopy: a diagnostic and surgical approach to recurrent sinusitis.** Endoscopy #6, Vol. 18, Nov 1986.

7. Stamberger, H. **Orientation important during functional endoscopic sinus surgery (FES)** Karl Storz Endoscopy. America Inc. publication.

8. Stankiewicz, J. **Complications of endoscopic intranasal ethmoidectomy.** Laryngoscope 97:1270-1273 Nov 1987.

Bibliography

1. Kennedy, D. et al. **FESS: The principle and practice of rhinology.** pp. 879-901 John Wiley & Sons Inc., 1987.

2. Stamberger, H. **Endoscopic endonasal surgery - concepts in the treatment of recurring sinusitis.** Otolaryngology, Head and Neck Surgery. Vol. 94, #2, Feb 1986.

3. Stamberger, H., Kennedy et al. **Lecture notes from FESS Course, John Hopkins University, Baltimore, July 1988.**

4. Schaefer, D. et al. **Endoscopic paranasal sinus surgery: indications and considerations.** Laryngoscope 99:1-5 Jan 1989.

5. Zinreich, S.J. et al. **Paranasal sinuses: CT imaging requirements for endoscopic surgery.** Radiology 163:769-775, 1987.

A BENIGN AND MALIGNANT MIDDLE EAR*

Leonardo D. Wee, MD**

Abstract

A 13-yr old girl presented with ear discharge, otalgia, headache, and neurological deficits with behavioral changes. After CT scan and mastoid series were done, TB mastoiditis with meningitis was the working diagnosis. Final histopathologic result after exploratory mastoidectomy was done revealed: squamous cell carcinoma, poorly differentiated with schematic necrosis, chronic granulomatous inflammation with caseous necrosis with pieces of necrotic bone (sequestra), TB most probably. Chest X-ray, nasopharyngeal biopsy, and lymph node, AFB of sputum were suggestive of tuberculous infection. Proper anti-tuberculous drugs coupled with post op cobalt irradiation proved to be successful. She is still well and alive after two years.

Introduction

Some otologic diseases usually coexist with systemic illness in a causative manner (PTB and TB mastoiditis). It can manifest as a sequelae from otologic disease (otitis media and labyrinthitis) or may be coincidental (otosclerosis and

labyrinthitis). Primary middle ear neoplasm particularly squamous cell carcinoma and TB otitis media are two rare separate otologic diseases that are not diagnosed early in its clinical course. They are usually diagnosed post-operatively by histology. In its early symptomatology, both manifest symptoms as purulent otitis media: otorrhea, decrease hearing, and otalgia.

Tuberculosis in the Philippines is so common that (in all forms) it ranks third in the cause of mortality and fifth in the list of morbidity from the Department of Health Statistics.

It is therefore the objectives of this paper: to present a one of its kind and reportable case of primary cancer of the middle ear with concomitant tuberculous mastoiditis; to discuss the clinical signs and symptoms of middle ear carcinoma and tuberculosis; to place high regard on tuberculous otitis media as a differential diagnosis in a chronically discharging ear; to consider multiple pathologic conditions when diagnosing and treating ear diseases; and to emphasize the importance of histopathology.

Case Report

This is the case of R.T., 13 yr old female who was admitted for the first time on 23 July 1987 at UP-PGH Emergency Complex, Neurology Section for behavioral changes. She was referred to ENT for the right ear discharge and post auricular swelling.

Condition started 8 months prior to admission (November 1986) when she had decreased hearing of the right ear with sense of fullness and tinnitus.

One month later, she had fever, right otalgia and right ear discharge that was yellowish and foul smelling. She was asymptomatic after one week, but the ear discharge persisted.

Six months prior to admission, she noticed to have right sided neck mass and right facial asymmetry. No medical attention was obtained until 3 months prior to admission, she consulted at UP-PGH, OPD-Medicine for the neck mass. She was diagnosed to have chronic tympanomastoiditis right rule out nodular non-toxic goiter with cranial nerves V and VII palsy. She was advised ENT and Neurology consult and was requested to

* 2nd Prize-Scientific Symposium on Interesting Cases held at the Manila Midtown Ramada Hotel on 7 July 1989

** Resident, Department of Otorhinolaryngology, PGH

have a thyroid scan. Neither of the suggestions were done. She was lost to follow up until 2 weeks prior to admission, she had severe vertigo, intolerable right otalgia, and intractable headache. She became bedridden, had anorexia, and body weakness. She was described to be uncommunicative and restless, hence she was brought to UP-PGH Emergency Complex, Neurology Section.

Pertinent physical examination showed her to be poorly nourished, ambulatory, afebrile, and not in any form of distress.

Neurology examination showed deficits in: CN V weak corneals right; decrease sensory by 50% VI to V3; CN VI right lateral rectus palsy; CN VII right peripheral facial palsy; CN VIII poor hearing.

Cerebellar: tendency to fall on the right on tandem walking with positive Romberg's

Sensory: decrease sensation by 50% on the right upper and lower extremities

Motor: 3/5 on the right upper and lower extremities

Extrapyramidal: right upper extremity drift and right lower extremity drag

Meningeals: positive neck rigidity, Kernig's and Brudzink's

Reflex: bilateral clonus sustained more on the left with positive babinski's on the left

Neurology had its diagnosis as chronic otitis media, right, rule out brain abscess, probably right cerebellar area with meningitis. Referral was made to ENT and Neurosurgery sections. Mastoid series and if possible a CT scan were requested.

Mastoid series: showed the entire right mastoid is lucent, the right petrous pyramid is eroded. The impression was consistent with tympanomastoiditis with cholesteatoma with destruction of the right petrous pyramid.

CT scan showed the soft tissue mass lesion originating from the right mastoid destroying the surrounding petrous pyramid including the apex. Components of this mass are noted to extend to

the right cerebellopontine angle. Contrast infusion reveals multiple low density foci at the bi-basal ganglia zones accompanied by minimal if any edema effect. The impression was chronic tympanomastoiditis with cholesteatoma formation on the right with destruction of the right petrous apex and extension of the mass to the right cerebellopontine angle. It is also suggestive of tuberculous meningitis.

Neurology revised their impression. She was started with anti-tuberculous drugs: Rifampin, Ethambutol, INH, and Pyrazinamide. AFB stain and culture of the sputum and ear discharge were requested. The sputum was positive for AFB organism, however the stain and culture of the ear discharge were negative.

The patient was then referred to ENT for mastoidectomy. Pertinent ENT examination showed the right ear to have total perforation, had yellowish and foul smelling discharge, had polypoid and hyperemic middle ear mucosa. There was no blood tinge discharge. The neck showed a 2 x 2 cm nodule on the right medial portion of the right sternocleidomastoid muscle, just lateral to the right thyroid lobe. It was movable and slightly tender that did not move on deglutition.

Exploratory mastoidectomy was done. Findings were: there was presence of dirty white creamy to gelatinous material mixed with pearly gray colored granulation tissue occupying the mastoid antrum. There was bony destruction with exposure of the sigmoid sinus and semicircular canal. The floor of the facial canal and the facial nerve were eaten out by the granulation tissue. The mass easily bled. A specimen was sent for routine histopathologic exam, special staining with Ziehl-Nielsen stain and for AFB culture. The last two exams had negative results. Histopath examination showed: squamous cell carcinoma poorly differentiated, with ischemic necrosis; chronic granulomatous inflammation with caseous necrosis and pieces of necrotic bone (sequestra); Tuberculosis most probably.

Chest X-ray showed fibrothorax right with cavitation of the right upper lung field; pulmonary tuberculosis most probably. The anterior neck mass was worked up and the thyroid scan revealed homogenous uptake on the entire gland and the palpable mass was extrathyroidal.

Nasopharyngeal biopsy, lymph node biopsy and bronchoscopy were done to rule out any primary

tumor in the said areas. The nasopharyngeal biopsy of the right showed chronic granulomatous inflammation with caseous necrosis and Langhan's giant cell, consistent with tuberculosis. Lymph node biopsy of the right neck revealed the same findings. Bronchial washings were negative for malignancy.

She was then referred to the Cancer Institute at UP-PGH for cobalt treatment. She was given a total of 3,500 rads at 150 rads per day for 23 days. She was discharged on her 47th hospital day with her only complaint of right facial asymmetry, alopecia, and mild right sided headache.

One year later, a repeat CT scan was done. Findings were: the right mastoid and petrous apex showed osseous destruction with no further extension as compared to the previous study. There is no definite mass lesion noted at the petrous apex and at the right cerebellopontine angle. Old infarcts are seen in the bi-basal ganglia. No evidence of meningitis. Chest X-ray showed no lung parenchymal infiltrates with an old right pleural reaction. The right ear was dry and devoid of any mass and tenderness. She is still alive and well up to the present time, two years post op.

Discussion

Chronic otitis media, in its early symptomatology, is difficult to differentiate with other otologic pathology. Chronic otitis media has its complications, namely: intracranial and extracranial. Aural complications include mastoiditis with bone destruction, subperiosteal abscess, facial paralysis, petrositis with bone destruction, and labyrinthitis. In petrositis, it has two constant symptoms: pain and persistent ear discharge. The triad of diplopia, pain around the eye and persistent otorrhea, constitute Gradenigo's syndrome. Intracranial complications include: meningitis, brain abscess, subdural and extradural abscess, and lateral sinus thrombophlebitis. Acquired cholesteatoma is the consequence of otitis media with effusion and acute otitis media. It erodes the mastoid cavity and subsequent temporal and intracranial complications. The above conditions, when put together, will make the picture of a chronically draining ear so complicated.

Cancer of the Middle Ear

It was Politzer, in 1883 who first recognized carcinoma of the middle ear as a distinct entity. Primary involvement of the middle ear is rare and the incidence of the middle ear cancer range from 1:5,000 (Towson and Shofstall, 1950) to 1:25,000 (Mawson, 1979) with ear problem. According to Friedman, 27% of ear carcinoma is on the middle ear (Chen & Delmer, 1978). Goodman (1971) reported that 63% of the middle ear new growth are malignant and 76-81% (Tucker, 1964; Lewis, 1983) of it are squamous cell carcinoma.

The importance of early diagnosis is always emphasized. Early diagnosis is frustrated by the absence of specific signs and symptoms of early carcinomatous changes. It masquerades as chronic suppuration for at least six months (Lewis, 1983).

It is widely accepted that one of the most commonly identified predisposing factor in tumor development is chronic suppuration and the duration is long, 10 years to 40 plus years in 58% (Tucker, 1964) and it occurs in 77-100% (Sinha and Ibn Aziz, 1978; Michaels and Wells, 1980) of middle ear carcinoma. Cholesteatoma was found in 14% (Michael & Wells, 1980) of middle ear carcinoma, however, there is no agreement about its role in tumor development. Carcinoma was also found to be present in 47% of cases who had radical mastoidectomy (Kenyon et al, 1985).

Age groups affected are in their 50's to 70's with majority in the latter age group. Presenting symptoms are mostly ear discharge of long duration, however less than six months are present in 15% (Tucker, 1964). Otalgia was present in 60-86% (Michaels and Wells, 1980; Sinha and Ibn Aziz, 1978) described as deep and boring and aggravates in 43% (Kenyon et al, 1985). There is also serosanguinous discharge in 21-47% (Michaels and Wells, 1980; Kenyon et al, 1985). Direct local extension of the disease would produce deafness in 21-100% (Tucker, 1964; Michaels & Wells, 1980); tinnitus in 15-38% (Hahn et al, 1983); Kenyon et al, 1985); and vertigo in 11-33% (Hahn et al, 1983; Kenyon et al, 1985).

Clinical signs include mastoid tenderness; cranial nerve palsy in 54% of cases (Sinha and Ibn Aziz, 1978) particularly cranial nerve VII in 41-57% (Michaels and Wells, 1980; Kenyon et al, 1985). Cranial nerves VI, IX, X, and XII are also involved in more extensive posterior growth

pattern. There is 3-33% (Michaels and Wells, 1980; Kenyon et al, 1985) lymph node enlargement and most are inflammatory. It is because the middle ear has poor lymphatic drainage. Otoscopic findings show polyps or granulation tissue that are nodular, friable, and hemorrhagic. Pre-operatively, 19% (Kenyon et al, 1985) are not diagnosed.

Mastoid series would show bone destruction in 70% (Lewis, 1983) with involvement of the petrous bone, mastoid bowl, and semicircular canal. Mode of spread could be anteriorly towards the eustachian tube; upwards to the tegmen tympanic and backwards to the petrous pyramid.

Biopsy is essential to early diagnosis but radiologically, CT scan has two roles: to suggest the diagnosis from the type of erosion-ragged, extensive and found in an unusual site, suggests tumor. Similar appearance to cancer in the scan are TB mastoiditis and malignant otitis externa. Management should be individualized, depending on the size, location, nutritional status of the patient, age of the patient, and the degree of differentiation of the histopathology. Cases are said to be unresectable when there is base of the skull involvement, extension of the tumor to the eustachian tube and to the nasopharynx. Surgical technique range from radical mastoidectomy to total temporal bone resection.

Neither the UICC nor the ASCC developed a staging system for cancer of the ear. However, Stell (1984) suggested a staging system. For this patient who had supposedly new growth extension beyond the middle ear is stage III. In Mawson's (1979) table of summary of treatment, the patient would be subjected to radiotherapy only. Since the patient's diagnosis has not been established, exploratory mastoidectomy was done with removal of debritic and necrotic tissues. Surgery in any form, provides diagnosis, determines the extent of the disease, permits adequate drainage, and provides relief of pain.

The 5-year survival rate of surgery in resectable cancer of the middle ear is 14.3-28.5% (Hahn, 1983; Lewis, 1983). For radiotherapy alone, the best survival for 5 years is 0-14% 1/n7 (Sinha and Ibn Aziz, 1978) and is reserved for unresectable cases and for elderly patients who has poor nutritional status. Combination of surgery and post-op radiotherapy (5,000 rads to 6,000 rads) shows an encouraging 25-50% (Stell,

1984; Hahn et al, 1983) 5-year survival rate. In Lewis (1983) extensive series of 105 resectable middle ear carcinoma, 35.5% was the 5-year survival rate for patients having temporal bone resection with post-op cobalt treatment. Patients with involvement of the petrous bone had a poorer prognosis with 20% 5-year survival rate (Hahn, 1983). Michaels and Wells (1980) in a series of 28 squamous cell carcinoma of the middle ear, had a 39% 5-year survival rate with radical mastoidectomy and post-op radiotherapy. Sinha and Ibn Aziz (1978) had a 40% 5-year survival rate with removal of the temporal bone and post op irradiation. With this statistics, any form of surgery has not changed significantly the 5-year survival rate.

Kenyon et al (1985) noticed that the degree of histopathologic differentiation appears to have a direct relationship to survival. Six out of six poorly differentiated squamous cell carcinoma had 15.5 to 19 years of survival with post op cobalt therapy.

Tuberculosis of the Middle Ear

In 1942, the average incidence of TB mastoiditis in 8.55 cases of chronic otitis media was 2.7% (Proctor and Lindsay, 1942). Today, tuberculosis of the ear is rare and its occurrence is 0.05-0.9% (Ramesh et al, 1985; Palva et al, 1985). It occurs most often at ages under 15 yr old. However, the true incidence is difficult to assess. It would vary from country to country, depending on the socio-economic situation and its epidemiology and also the institutional and time setting of the study.

The temporal bone could get infected in majority of cases by: hematogenous spread of lymphatic spread; direct extension from the nasopharynx through the eustachian tube-4.9% (Skolnik et al, 1986) had positive nasopharyngeal biopsy; and rarely from direct implantation through the external auditory canal. The first two mechanisms would explain the mode of spread in my patient, as shown in the right nasopharyngeal biopsy and right lymph node biopsy.

Clinical manifestations vary, but generally, it is divided into an early and late stages. Early symptomatology include tinnitus, acute hearing loss, fullness, painless otorrhea, and at times painful in 0.06-6.2% (Skolnik et al, 1986). Middle ear mucosa appears to have pale, white to

pearly gray colored granulation tissue 56-63% (Rames and Gertler, 1985; Skolnik et al, 1986); polyp 12-13% (Rames and Gertler, 1985; Skolnik et al, 1986) or polypoid mucosa in 4% (Rames & Gertler, 1985). There is central to total perforation with mucoid to mucopurulent discharge that lasts for more than one year in 60% of patients (Samuel and Fernandez, 1986). The original description of multiple perforation with mucoid to mucopurulent discharge that lasts for more than one year in 60% of patients (Samuel and Fernandez, 1986). The original description of multiple perforation of the membrane as described by Eschle in 1983 is seldom observed nowadays. 78% (Windle-Taylor & Bailey, 1980) of patients has a six-month duration of symptoms before presentation. Lymphadenitis may be present in 0.02-9% (Skolnik et al, 1986; Samuel and Fernandez, 1986).

Later the stage will progress to the caseous stage. The discharge is cheesy and the granulation tissue becomes profuse with extension of the mucosal disease to the bone to produce facial paralysis, mastoiditis with osteomyelitis of the petrous pyramid, and subsequently meningitis. Facial palsy occur in 16-39% (Skolnik et al, 1986; Samuel and Fernandez, 1986) of TB otitis media more commonly among children. Severe intracranial spread results in TB meningitis in 1.9-8% (Skolnik et al, 1986; Samuel and Fernandez, 1986) which may be the initial presentation as in this case. It results in chronic inflammatory process at the base of the brain leading to the infraction and cranial nerve deficits.

Tuberculous petrositis had been reported by Hiranandani in 1967 with temporary involvement of cranial nerve VI. Symptoms of petrositis depend on what area is affected. In my patient, there was involvement of CN V and CN VI. CN V and CN VI are at the apex of the pyramid. In CN VI paralysis, the nerve is compressed when it passed through the Dorello's canal beneath the petrosphenoid ligament. The semilunar ganglion (CN V) whose main root is sensory, enters the lateral surface of the pons, it being the superior aspect of the cerebellopontine angle. Extension of the mass into the cerebellopontine angle might mimic space occupying lesion of the said area. Granick et al (1985) enumerated the symptomatology of the cerebellopontine angle tumor. Grabscheid (1973) also reported tuberculous mass in the petrous apex with involvement of the jugular foramen and foramen magnum.

Chest X-ray, mastoid series, and PPD has poor predictive value but they are suggestive of tuberculous occurrence. Positive bacteriology of ear discharge are difficult to attain as shown by the studies of Lucente (1978). AFB smear was positive in 20% of cases and AFB culture had 5-35% growth. If positive, it helps to support the diagnosis. Previous personal and family history of tuberculosis has a diagnostic indicator of 27-44% (Windle-Taylor and Bailey, 1980; Rames and Gertler, 1985). An active pulmonary tuberculosis is most suspicious (Taylor, 1980) although 42% (Skolnik et al, 1986) showed normal chest X-ray. 64% (Rames and Gertler, 1985) of diagnosis was done only after operation by final histopathology results. Therefore, the highest diagnostic yield is through histologic examination.

Tuberculosis has two types of tissue reactions (Robbins, 1984): non-caseating tubercle and caseating tubercle. Classically, the hallmark of TB is characterized by the presence of central caseating necrosis with loss of cellular details. The caseous foci are surrounded by epithelioid cells, rimmed by fibroblast, lymphocytes, histiocytes, and occasional Langhan's giant cells. Sarcoidosis never evokes caseation necrosis so as with other granulomatous diseases such as fungal infection and syphilis. The morphologic pattern of TB is distinctive and an accurate diagnosis can be made by an experienced pathologist.

The histology of the biopsy specimen establishes the diagnosis when AFB are identified in the histopath section. Failing to demonstrate the acid fast bacilli, the diagnosis is at its best suggestive and further work-up with culture is being confirmatory than diagnostic (Rames and Gertler, 1985). Unfortunately, acid fast bacilli in the diseased tissues are difficult to find (Robbins, 1984).

Findings at operation are thick, pearly gray granulation tissue that fills the mastoid cavity. Other important findings include: bony destruction with sequestration and dehiscence of the facial canal, lateral sinus, and labyrinth. There is also increased bleeding on manipulation.

Treatment in uncomplicated cases is medical treatment with combination of anti-Kochs regimens. Surgery is advised when there is facial nerve palsy, subperiosteal abscess, labyrinthitis and extension to the central nervous system. These conditions were found in my patient.

TB (Benign)	Non-Specific	Malignant
13 yr old		
CN7 palsy Short duration of otorrhea Petrositis (apex) CN V, VI TB meningitis + family Hx of PTB	Decreased hearing Tinnitus Vertigo Otorrhea Polypoid mucosa Total perforation Discharge Mastoiditis CT scan and mastoid X-ray - bony destruction Increased bleeding during operation Misdiagnosed preoperatively	Otalgia-severe - unbearable - aggravating Headache-severe
CT scan-basal ganglia involved Chest X-ray-RULF -fibrothorax + AFB sputum Lymph node Bx -CGI with - caseous necrosis Nasopharyngeal Bx, R - CGI - caseous necrosis		
Mastoid granulation tissue histology - CGI with - caseous necrosis - with sequestra		Mastoid granulation tissue pathology - squamous cell carcinoma - poorly differentiated - with sequestra
TREATMENT: - surgical - anti-TB drugs		TREATMENT: - surgical - cobalt
RESPONSE: - dry ear - chest X-ray, no infiltrates - CT scan, no extension		RESPONSE: - dry ear - no otalgia - no headache - CT scan, no extension, no mass

Summary

Clinical diagnosis usually comes in the wake of clinical awareness. One should be quite aggressive in searching for a diagnosis of an ear discharge of five to six months duration after adequate treatment has been given. In our Philippine setting, a family history of pulmonary tuberculosis always be asked and when suspicious, screening procedures of PPD and chest X-ray and maybe mastoid X-ray should be requested. Positive results are suggestive of tuberculosis otitis media. If possible, an ear bacteriology should include AFB smear and culture because they help support the diagnosis. Finally, if a polyp, granulation tissue or a polypoid mucosa is seen otoscopically, a formal biopsy should always be done. A pediatric patient with facial paralysis should always be suspected of having TB mastoiditis when first seen.

Cancer of the middle ear should be ruled out when symptoms of intolerable, severe and aggravating otalgia and headache are elicited, more especially in patients who are in their 50's to

70's with long standing ear discharge. Mastoid series and possible CT scan should be requested after a formal biopsy of a polyp or granulation tissue had been done.

Therefore, whatever the case may be, suspicious or non-suspicious, in all ear operation, all specimens in any form should be submitted for histopath evaluation for proper diagnosis and management.

Conclusion

We have a case of a 13-yr old female with squamous cell carcinoma poorly differentiated with concomitant tuberculous mastoiditis who presented as chronic tympanomastoiditis with intracranial and extracranial complications. She was seen by Neurology and was referred to ENT. CT scan and histopathologic examination of the granulation tissue helped in the diagnosis of the disease process. Hence, an adequate triple therapy of medical, conservative surgical procedure and post-op cobalt therapy made her survive for two years till today without any recurrence.

References

TUBERCULOSIS:

Grabscheid, E. 1937. Tuberculosis of the petrous apex. *Archives of Otolaryngology* 25:11-16.

Granick, M.S., Martuza, R.L., Parker, S.W., Ojemann, R.G., Montgomery, W.W. 1985. Cerebellopontine angle meningiomas: Clinical manifestations and diagnosis. *Ann. Otol. Rhinol. Laryngol.* 94:34-37.

Harbert, F. and Riordan, D. 1964. Tuberculosis of the middle ear. *The Laryngoscope* 74:198-204.

Hiranandani, L.H. 1967. Tuberculous petrositis. *The Laryngoscope* 77:1723-1728.

Kohlmoos, H.W. 1966. Tuberculosis of the middle ear. *The Laryngoscope* 76:1181-1185.

Palva, T., Palva, A., Karja, J. 1973. Tuberculous otitis media. *Journal of Laryngology and Otolology* 87:253-261.

Proctor, B., Lindsay, J.R. 1942. Tuberculosis of the ear. *Archives of Otolaryngology* 35:221-249.

Ramages, L.J. and Gertler, R. 1985. Aural tuberculosis: a series of 25 patients. *The Journal of Laryngology and Otolology* 99:1073-1080.

Samuel, J. and Fernandes, C.M.C. 1986. Tuberculous mastoiditis. *Ann. Otol. Rhinol. Laryngol.* 95:264-266.

Skolnik, P.R., Nadol, Jr., J.B., Baker, A.S. 1986. Tuberculosis of the middle ear: review of the literature with an instructive case report. *Reviews of infectious diseases* 8:403-410.

Lucente, F.E., Tobias G.W., Papisier, S.C., Som, P.M. 1978. Tuberculous otitis media. *The Laryngoscope* 88:1107-1116.

Wallner, I.J. 1965. Tuberculous otitis media. *The Laryngoscope* 63:1058-1075.

Windle-Taylor, P.C. and Bailey, C.M. 1980. Tuberculous otitis media: a series of 22 patients. *The Laryngoscope* 90:1039-1044.

CARCINOMA OF THE EAR:

Chen, K.T.K., Dehner, L.P. 1978. Primary tumors of the external and middle ear. Part I-Intro-

duction and clinicopathologic study of squamous cell carcinoma. *Archives of Otolaryngology* 104:247-252.

Towson, C.E., Shofstall, W.H. 1950. Carcinoma of the ear. *Archives of Otolaryngology* 51:724-738.

Hahn, S.S., Kim, J.A., Goodchild, N., Constable, W. 1983. Carcinoma of the middle ear and external auditory canal. *Int. Jr. Radiation Oncology Biol. Phys.* 9:1003-1007.

Kenyon, G.S., Marks, P.V., Scholtz, C.L., Dhillon, R. 1985. Squamous cell carcinoma of the middle ear: A 25 year retrospective study. *Ann. Otol. Rhinol. Laryngol.* 94:273-277.

Lewis, S.J. 1973. Squamous carcinoma of the ear. *Arch. Otolaryngology* 97:41-43.

Lewis, S.J. 1983. Surgical management of tumors of the middle ear and mastoid. *The Journal of Laryngology and Otolology* 97:299-311.

Lloyd, G.A.S. and Phelps, P.D. 1982. The investigation of petro-mastoid tumors by high resolution CT. *British Journal of Radiology* 55:483-491.

Michaels, L. and Wells, M. 1980. Squamous cell carcinoma of the middle ear. *Clinical Otolaryngology* 5:235-248.

Olsen, K.D., De Santo, L., Forbes, G. 1983. Radiologic assessment of squamous cell carcinoma of the temporal bone. *The Laryngoscope* 93:1162-1167.

Phelps, P.D. and Lloyd G.A.S. 1981. The radiology of carcinoma of the ear. *British Journal of Radiology* 54:103-109.

Robbins, S.L. 1984. Pathologic basis of disease, W.B. Saunders Co., 1595 pp.

Sinha, P.P. and Ibn Aziz, H. 1978. Treatment of carcinoma of the middle ear. *Therapeutic Radiology* 126:485-487.

Stell, P.M. 1984. Carcinoma of the external auditory meatus. *Clinical Otolaryngology* 9:281-299.

Tucker, W.N. 1974. Cancer of the middle ear. *The Laryngoscope* 18:642-650.

Wang, C.C. 1975. Radiation therapy in the management of carcinoma of the external canal, middle ear or mastoid. *Radiology* 116:713-715.

**MASTOID CAVITY DIMENSIONS AMONG
FILIPINOS: ITS SURGICAL
RELEVANCE***

**Norberto Martinez, MD, William
Lim, MD, Ellen Ng, MD, Daniel
Alonzo, MD** Leopoldo Uichanco,
MD*** Eric Nubla, MD******

Every mastoid surgery explores a unique dimension as distinctive as everyone's thumbprint, putting the surgeon's skills to a test since no two temporal bones are alike. Adjacent to the temporal bone are delicate structures such that a non-exacting surgical intervention may result to irreversible damage to the patient and emotionally straining to the surgeon. As a result, the overcautious surgeon performs an inadequate operation rather than compromise irreparable damage to strategic structures. Henceforth, this study was conducted to: (1) determine the dimensions of the mastoid cavity in Filipino temporal bones which could be utilized as a guide during mastoidectomy; (2) correlate the measurements gathered from cadaver dissections with those from CT scan; and (3) serve as a training ground for otolaryngology residents. 56 temporal bones were divided according to age, sex, and side of the skull from which the bone was taken. They were dissected exposing landmarks of surgical importance enabling determination of the mastoid length, width, and

depth. Measurements of the mastoid width and depth were likewise taken from 55 CT scan plates. Results showed no significant difference in width between data gathered from actual dissection and CT scan. In this study it is apparent that otologic surgical techniques cannot be learned from books alone nor solely in the operating room but by painstaking cadaver dissection. The average dimensions of the Filipino adult temporal bone are as follows: mastoid length - 3.87 ± 0.46 cm; width - 1.02 ± 0.29 cm; depth - 1.43 ± 0.21 cm. Cognizant therefore of the standards set forth by this study, a more rational approach to mastoid surgery can be done without fear of attendant complications and yet facilitate completeness of dissection.

Introduction and Objectives

Mastoidectomy may not seem to be an extraordinary procedure, but to the otolaryngologist, each procedure explores a unique dimension as distinctive and individualistic as everyone's thumbprint. It opens up a new challenge to every surgeon as a new horizon unfolds putting his finest skills to a test since no two temporal bones are alike. Adjacent to the immediate limits of the temporal bone are structures of utmost sensitivity such that a non-exacting surgical intervention may result to irreparable damage to the patient and prove emotionally straining to the surgeon. As Friedrich Bezold once said, "The danger to the patient of an incompetent operator who does not know the many anatomic details crowded together in the narrow space of the temporal bone and their extreme variability is much greater here than in any other region of the body." As a result, more often than not, the surgeon performs an inadequate operation rather than compromise irreparable damage to strategic structures. We see no justification in subjecting the patient to a sizable medical expense not to mention the accompanying hazards of surgery and anaesthesia if only minimal or no improvement is achieved.

Henceforth, this study was conducted with the following objectives: (1) to determine the dimensions of the mastoid cavity in Filipino temporal bones which could be utilized as a guide in the performance of a complete mastoidectomy; (2) to correlate the measurements obtained from cadaver dissections with those from CT scans; and (3) to serve as a training ground for otolaryngology residents.

* 1st Prize-7th Scientific (Clinical) Research Contests in
Otolaryngology held at the Manila Midtown on 30 October 1987

** Residents, Department of Otolaryngology, UST Hospital

*** Consultant, Neuroradiologist, Chinese General Hospital

**** Resident, Department of Otolaryngology, Makati Medical Center

Materials and Methods

The data from this study were obtained from 56 randomly selected temporal bones with complete head permit for autopsy and were divided according to age, sex, and side of the skull from which the bones were collected. Excluded from this study were bones from cadavers with:

- (1) history of otologic and neuro-otologic problems;
- (2) history of trauma to the temporal bone region;
- (3) history of cranial-facial anomalies;
- (4) history of bone disease.

The temporal bones were stripped of soft tissues and periosteum and were mounted to a House-Urban temporal bone holder positioned in such a way as to simulate actual surgery. Operating microscope OPMI 99 was used for optimum lighting and visualization. Dental drills and suction irrigators were used throughout the dissection exposing all landmarks of surgical importance in the performance of a complete mastoidectomy. Measurements were taken to the nearest 0.5 mm from points such as:

- A. Nearest distance between the mastoid tip and the dural plate (mastoid length);
- B. Closest distance between the posterior canal wall and the sigmoid sinus (mastoid width);
- C. Distance between the lateral edge of the posterior canal wall to the level of the prominence of the horizontal semi-circular canal (mastoid depth).

Measurements of the mastoid width and depth were likewise taken from 55 randomly selected CT scan plates obtained from the Chinese General Hospital CT scan section. These subjects were divided into two groups: those below 15 years of age (12 patients) and those above 15 years (43 patients). They were also subdivided according to the side of the skull and sex except for those below 15 years wherein the paucity of subjects limits further subdivision. The same exclusion criteria set for actual cadaver dissections were implemented.

Statistical analysis using student's T test was used in the evaluation of the data with P values less than .05 considered as significant.

Results

I. Cadaver Dissections

A summary of the data and measurements obtained from 56 Filipino adult temporal bones divided as to side (28 males; 28 females) are presented on Tables IA and IB. The age range was 17 to 79 with an overall mean age of 50.48 $SD \pm 15.30$. Unpaired T test showed no significant difference ($p > 0.05$) between the left and the right ear except for the mastoid width in females wherein the values of the left mastoid were significantly greater than those of the right mastoid ($p < 0.05$). This is attributed to a singular bone with an exceptionally big dimension (1.95 cm) as opposed to the other specimens (0.78-1.52 cm).

Result of the mastoid cavity dimensions according to sex as shown in Table II and Figures 1, 2, and 3 showed no significant difference between males and females ($p > 0.05$).

II. CT Scan Plates

A. 15 years and above

A summary of the data and measurements obtained from 42 CT scan plates (25 males; 17 females) divided as to side are depicted in Tables IIIA and IIIB and Figures 4 and 5. The age range was 15 to 79 with an overall mean age of 45.48 $SD \pm 19.77$. Statistical analysis showed no significant difference as to side ($p > 0.05$).

Result of mastoid cavity dimensions based on sex (Table IV and Figures 4 & 5) showed no significant difference between the values for males and females ($p > 0.05$).

B. Below 15 years of age

Likewise, measurements of 12 CT scan plates were obtained (4 mo to 8 yr). Because of the limited number of subjects, no comparison between side of the skull and sex could be done.

C. 15 years and above vs below 15 years

A comparison of measurements obtained from subjects above and below 15 years old (Table V and Figures 4 and 5) showed no significant difference ($p > 0.05$) in depth but a highly significant difference in width ($p < 0.001$).

III. Actual Dissection vs CT scan

A comparison of the data gathered from actual dissections and those gathered from CT scan are presented in Table VI and Figures 6 and 7. Statistical analysis showed no significant difference in depth ($p > 0.05$). However, measurements of mastoid width obtained by CT scan are significantly higher than those obtained from cadaver specimens ($p < 0.001$).

Discussion

You will easily recognize that there is hardly another part of the body which calls for higher qualifications on the part of the operator as to anatomical knowledge than the temporal bone.¹ Within the size of a fifty cent piece are the tympanic membrane, tympanic ring, ossicles, jugular vein, carotid artery, facial nerve, and the vestibular and auditory parts of the inner ear.²

In doing a complete mastoidectomy, all air cells must be exenterated which means exposing all the limits of the mastoid cavity. Superiorly, the dural plate marks the limit; inferiorly, the mastoid tip; posteriorly, the sigmoid sinus plate; and medially, the level of the lateral semicircular canal. The temporal line, from which the inferior margin of the temporalis muscle is inserted, approximates the level of the middle fossa dura which is a rough guide. There is no reliable surface landmark for location of the sigmoid sinus.¹ Surgical landmark for the mastoid portion of the seventh cranial nerve is the bulge of the posterior half of the bony horizontal semicircular canal. During mastoid development, Komer's septum, a bony plate that forms separating the air cells of the squamous and petrous portions of the temporal bone may persist. This may be mistaken as the end point in the depth of dissection.

Despite the complexity of temporal bone anatomy, otologists have a distinct advantage in being able to reproduce faithfully the principles of temporal bone surgery in the dissection laboratory. The use of the operating microscope can be learned, surgical positioning reproduced accurately and the techniques refined in a cadaver temporal bone. Repeated use of these dissections will allow the surgeon to become skillful and knowledgeable enough to complete actual surgeries with confidence.²

Mastoid surgery comprises a good number of procedures performed by the otolaryngologist. Statistics have revealed that out of 529 ENT surgeries done at the Santo Tomas University Hospital Clinical Division from May 1984 to April 1987, mastoidectomy numbered 102 comprising 17.6%. As in any surgical procedure, it is not without complications which may be a harrowing experience for the surgeon.

One of the greatest fears of an inexperienced surgeon is that he may damage the facial nerve, understandably so, since it is the most apparent immediately post-operatively. Incidence varies from 0.6% (Pollmann) to 3.6% (Komer), with re-operations carrying a higher risk of 4.6-11%.³ In the Cleveland Clinic Foundation study of 572 patients with 7th cranial nerve palsy (1976 to 1981), 16 cases (2.79%) were attributed to ear surgery.² Cawthorne reviewed 138 cases of intra-temporal facial palsy requiring operation. In 47 cases, the palsy resulted from injury and the most common sites were the junction of the tympanic and mastoid segment and the upper portion of the mastoid segment of the nerve. Of 184 patients hospitalized for paralysis of the facial nerve, Jongkees reported that paralysis resulted from operative trauma in 80 patients.⁴ Mere exposure of the epineurium seldom damages nerve integrity but the resultant edema or intra-neural hematoma may be very consequential in terms of facial function.⁵

Iatrogenic brain herniation with or without attendant meninges may complicate mastoidectomy. Recently, 11 cases of brain herniation discovered in previously operated ears were reported by Kemerer and Caparosa. 6 patients sustaining small iatrogenic dural injuries during mastoidectomy over the last 11 years were studied by Neely (1985). They concluded

that dural injury is a prerequisite for herniation. If the dura is attenuated or lacerated and the arachnoid remains intact, the arachnoid may herniate with attendant CSF leak through the dural defect. If the arachnoid is injured, the temporal lobe herniates through the arachnoid and seals the dural defect effectively obstructing CSF leak.⁶

Inadvertent opening of the semicircular canal during mastoid surgery is fortunately rare occurring in 0.8% (Canalis) to 1% (Palva) of cases. Natural history of surgical trauma to the lateral semicircular canal is one of moderate to severe sensorineural hearing loss occurring acutely and recuperating to or close to the preoperative level over a period of three to six weeks. Acutely, the injury's most troublesome symptom is vertigo associated with nystagmus beating away from the operated ear. This symptom tends to continue well beyond the period of vestibular compensation with several patients reporting positional vertigo and mild unsteadiness on rapid turns a year or more after surgery.⁷

The thin outer dural wall of the sigmoid sinus may be accidentally traumatized during surgery leading to profuse bleeding. Infection adjacent to this portion of the sinus within the mastoid results in inflammation of its dural wall. A localized phlebitis develops and a mural thrombus forms. Bacteria are released through the bloodstream producing a septicemia. Portions of the thrombus break-off and septic emboli are thrown into the circulation. With continuous infection, the thrombus spread proximally towards the torcula herophilli and distally to involve the jugular vein. It may also spread along the tributaries of the lateral sinus which may lead to cavernous sinus thrombosis.⁸

After due consideration of the complex anatomy of the temporal bone and the traumatic complications characteristically inherent in the performance of a complete mastoidectomy, the need to devise a standard or norm which can aid the surgeon can now be emphasized. In an effort to augment the number of subjects particularly those belonging to the younger age group, CT scan measurements were employed. Investigations conducted by Diamant (1948) and Eby et al (1986) using radiographic studies have shown that growth of the mastoid air cell system terminates at about 15 years of age,

thus justifying its use as the cut-off age for data on CT scan. Since CT scan slices are based on 5 mm cuts, mastoid length measurements were not taken being rough estimates, not truly reflective of the actual dimensions. Evidently, mastoid width measurements based on CT scans cannot be used since they differ significantly from actual cadaver dissections. The discrepancy could be attributed to a difference in head tilt (orbitomeatal line or infraorbitomeatal line) which was not recorded in every patient. The averaging of 5 mm cuts is another variable which should be taken into account especially with curved structures like the bony plate or the sigmoid sinus. On the contrary, mastoid depth measurements obtained from CT scans do not differ significantly from values obtained on actual dissections. Therefore, these values are more reliable and accurate measurements of the mastoid depth taken together. To our advantage, these data on the mastoid depth provide a guide for the facial nerve which is the most common and most dreaded focus of complication.

For purposes of further analysis, a comparative study was made between temporal bone dimensions of western standards as opposed to our local subjects. In a study by Eby and Nadol (1986) on measurements of the mastoid length in 84 adult skull X-rays (PA and lateral views) consisting of 44 males and 40 females, the average mastoid length was 3.87 ± 0.33 which closely approximates our local results of 3.87 ± 0.46 . As to mastoid depth, the findings in this study belong to the lower limit (1.44 ± 0.22) in comparison to those stated by Rulon and Hallberg (1.4 to 2.0). Foreign literatures do not provide any data regarding mastoid width which could be used to compare the present data.

Conclusion

In conclusion, it is apparent that otologic surgical techniques cannot be learned from books alone nor solely in the operating room but by time consuming and painstaking cadaver dissection. There is absolutely no substitute.

On the basis of the foregoing data, we can therefore conclude that the average dimension of the Filipino adult temporal bones are as follows:

Mastoid length - 3.87±0.46 cm
 Mastoid width - 1.02±0.29 cm
 Mastoid depth - 1.43±0.21 cm

Cognizant therefore of the standards provided by this study, a more rational approach to mastoid surgery can be done without fear of attendant complications and yet facilitate completeness of dissection.

Recommendations

Since there was a paucity of temporal bones for dissection, further studies on a bigger population is needed to substantiate further the standards from this study. Data from children and adolescent group should be collected since the majority of patients who undergo mastoidectomy belong to these age groups. Measurements of middle ear structures should be attempted to aid the otologic surgeon in performing microsurgery for restoration of hearing.

TABLES

Dimensions of mastoid cavity obtained from actual cadaver dissections according to the side of the skull.

Table IA

Females (Mean±SD)

	Length	Width	Depth
Left	3.87±0.48	0.94±0.27	1.47±0.19
Right	3.87±0.54	1.00±0.27	1.43±0.22
DF=26	T=0.15*	T=0.58*	T=0.51*

* p > 0.05 not significant

Table IB

Males (Mean±SD)

	Length	Width	Depth
Left	3.76±0.40	0.92±0.23	1.40±0.23
Right	3.97±0.40	1.16±0.34	1.44±0.25
DF=26	T=1.37*	T=2.21**	T=0.66

* p > 0.05 not significant
 ** p < 0.05 significant

Table II. Dimensions of mastoid cavity obtained from actual cadaver dissections according to sex.

	Length	Width	Depth
Females	3.86±0.51	0.98±0.27	1.45±0.21
Males	3.88±0.41	1.06±0.32	1.44±0.24
DF=54	T=0.16*	T=1.01*	T=0.17*

* p > 0.05 not significant

Dimensions of the mastoid cavity obtained from CT scan according to sex.

Table IIIA

Females (Mean±SD)

	Width	Depth
Left	1.59±0.25	1.44±0.27
Right	1.62±0.16	1.44±0.27
DF=15	T=0.30*	T=0*

* p > 0.05 not significant

Table IIIB

Males (Mean±SD)

	Width	Depth
Left	1.46±0.24	1.44±0.29
Right	1.56±0.31	1.40±0.30
DF=23	T=0.91*	T=0.34*

* p > 0.05 not significant

Table IV. Mastoid cavity dimension from CT scan as to sex

	Width	Depth
Females	1.60±0.21	1.44±0.26
Males	1.47±0.28	1.42±0.29
DF=40	T=1.69*	T=0.23*

* p > 0.05 not significant

Table V. Dimensions of mastoid cavity obtained from CT scan according to age.

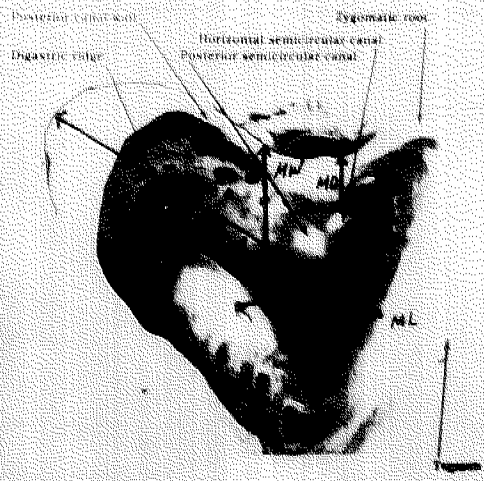
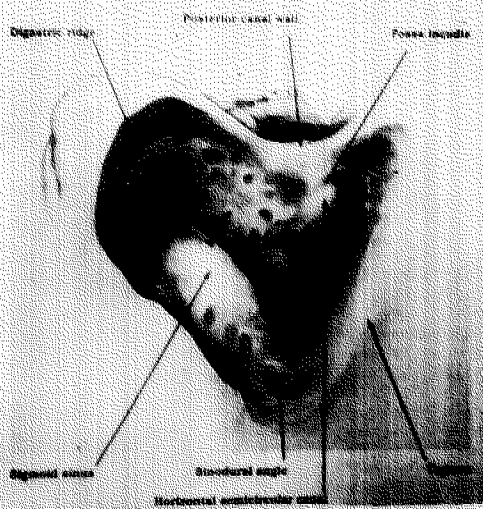
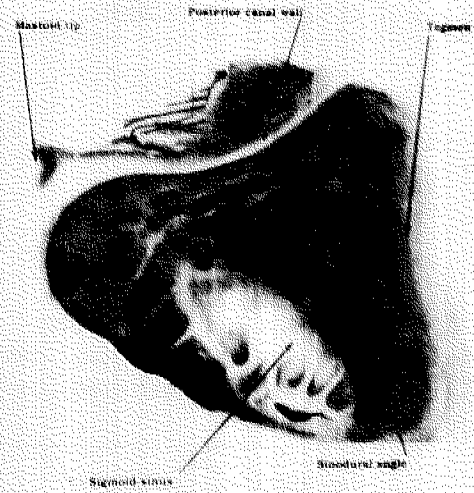
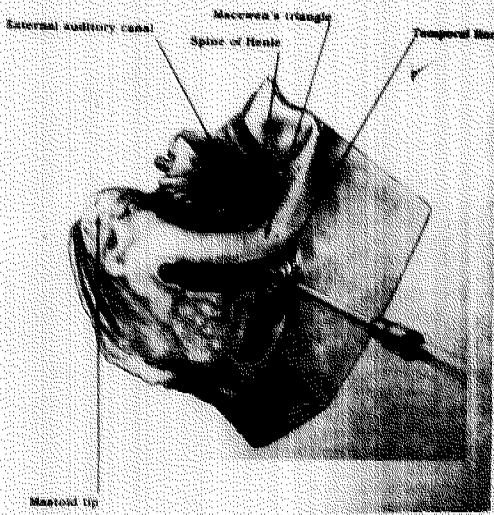
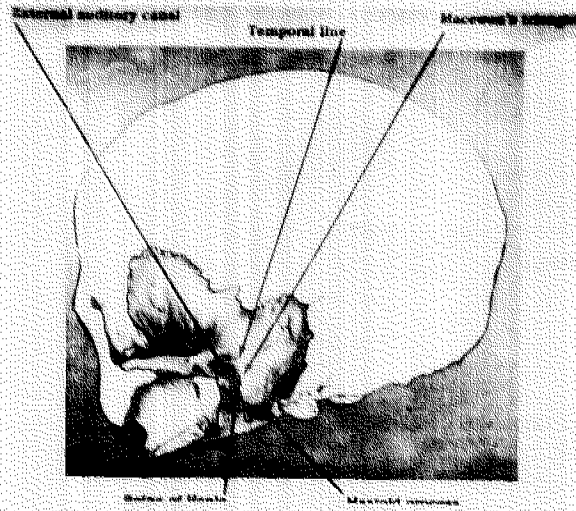
	Width	Depth
Above 15 years	1.53±0.26	1.43±0.27
Below 15 years	0.23±0.28	1.28±0.25
DF=52	T=7.03**	T=1.77**

* p > 0.05 not significant
 ** p < 0.001 highly significant

Table VI. Comparison between mastoid cavity dimensions obtained from actual cadaver dissections and those gathered from CT scan.

	Width	Depth
Actual dissection	1.02±0.30	1.44±0.23
CT scan	1.53±0.26	1.43±0.27
DF=96	T=8.92**	T=0.196*

* p > 0.05 not significant
 ** p < 0.001 highly significant



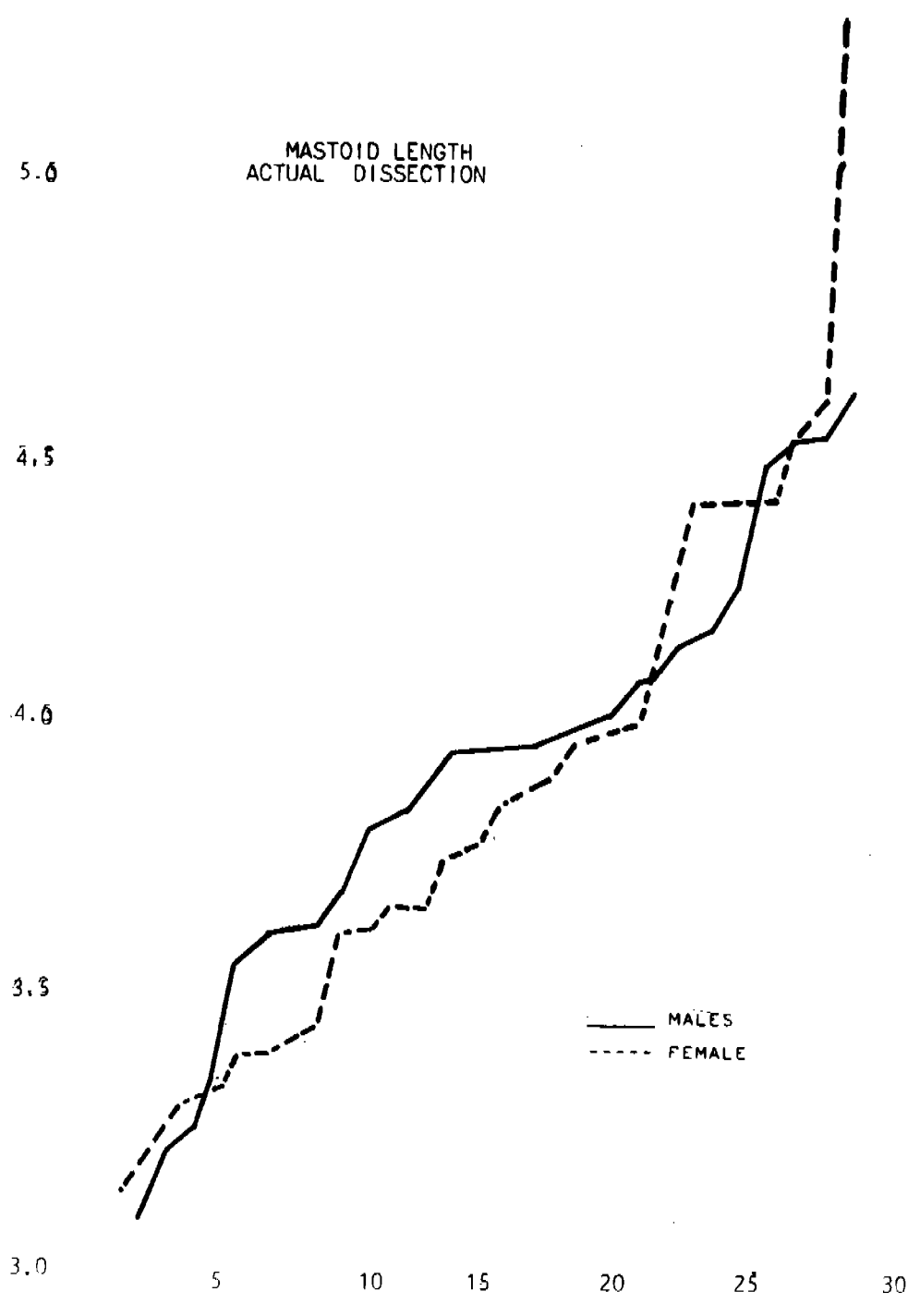


FIGURE 1

MASTOID DEPTH
ACTUAL DISSECTION

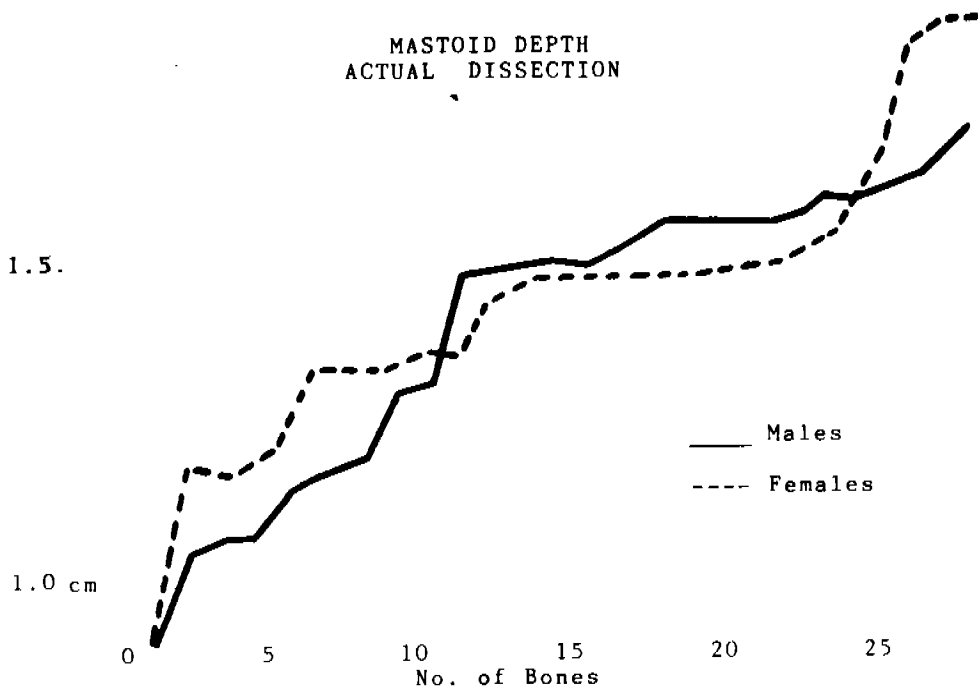


Figure 2

MASTOID WIDTH
ACTUAL DISSECTION

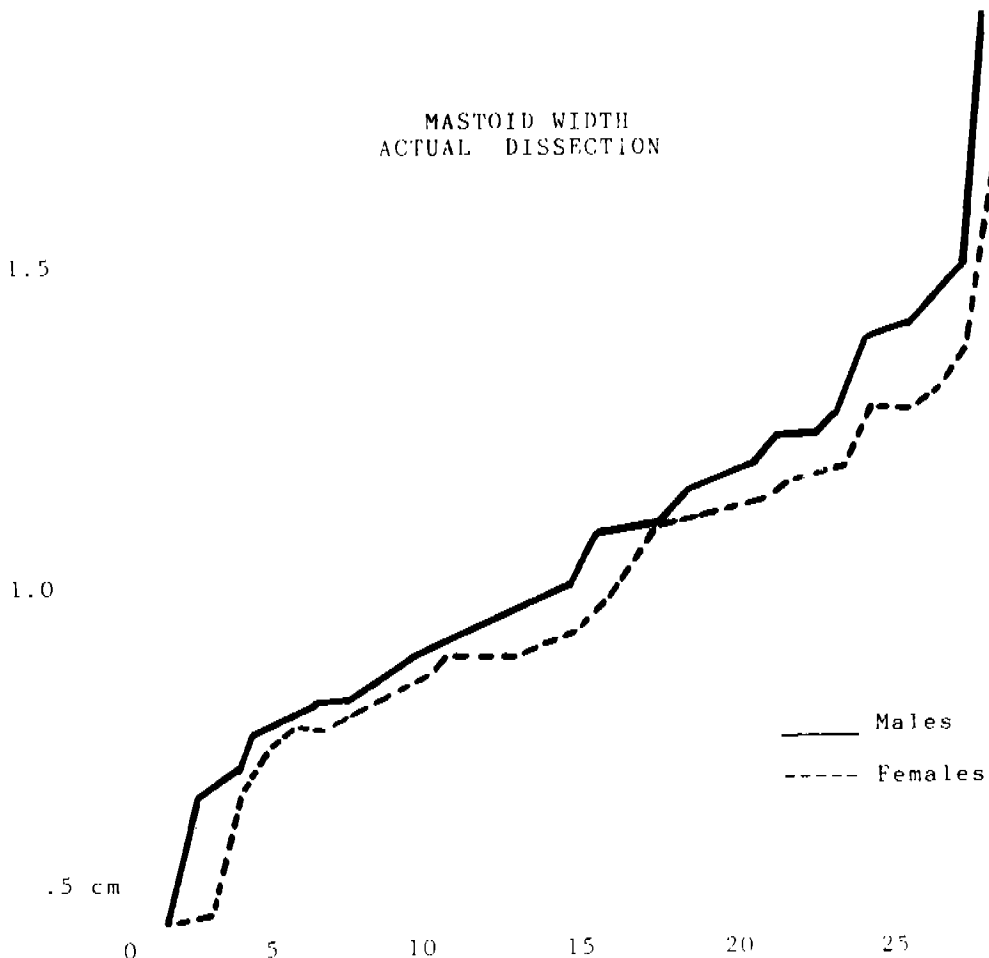


Figure 3

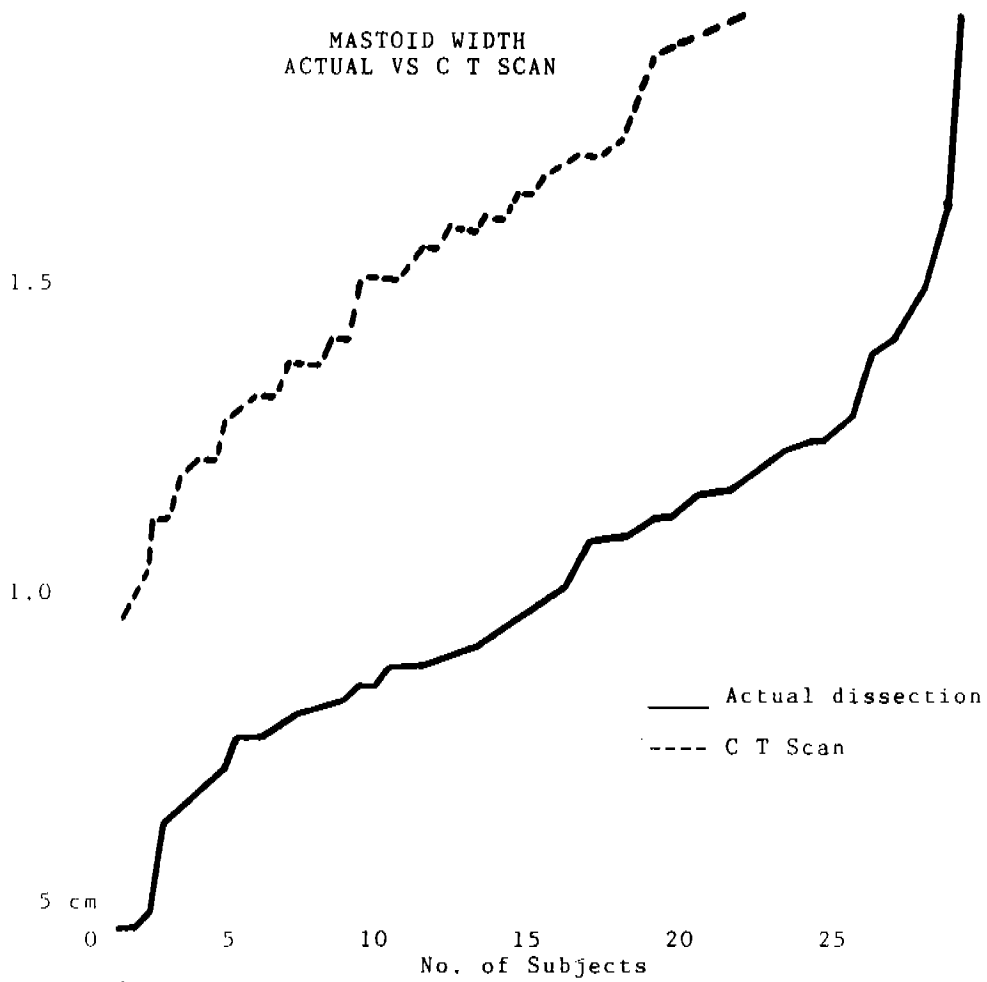


Figure 6

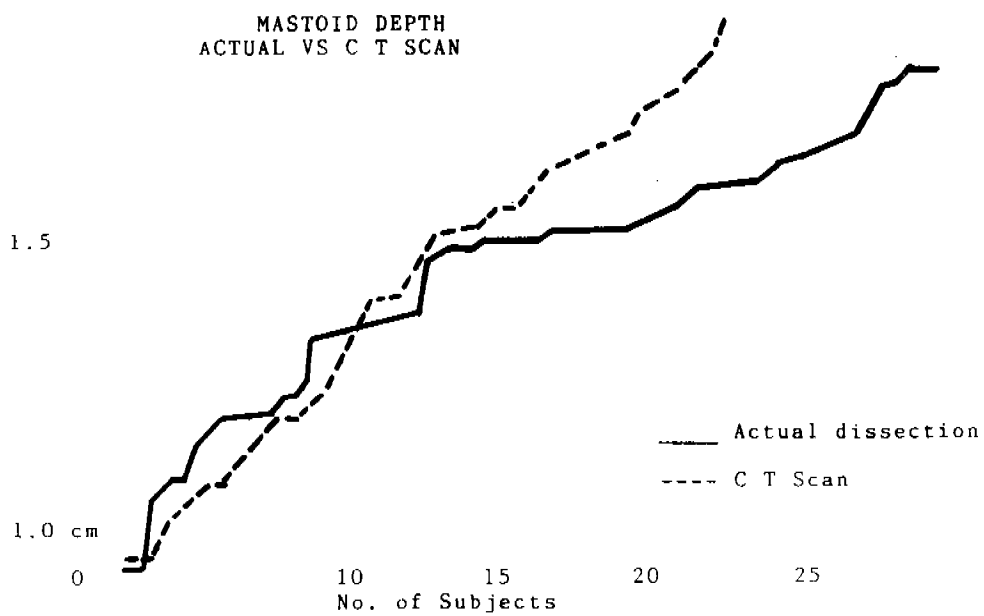


Figure 7

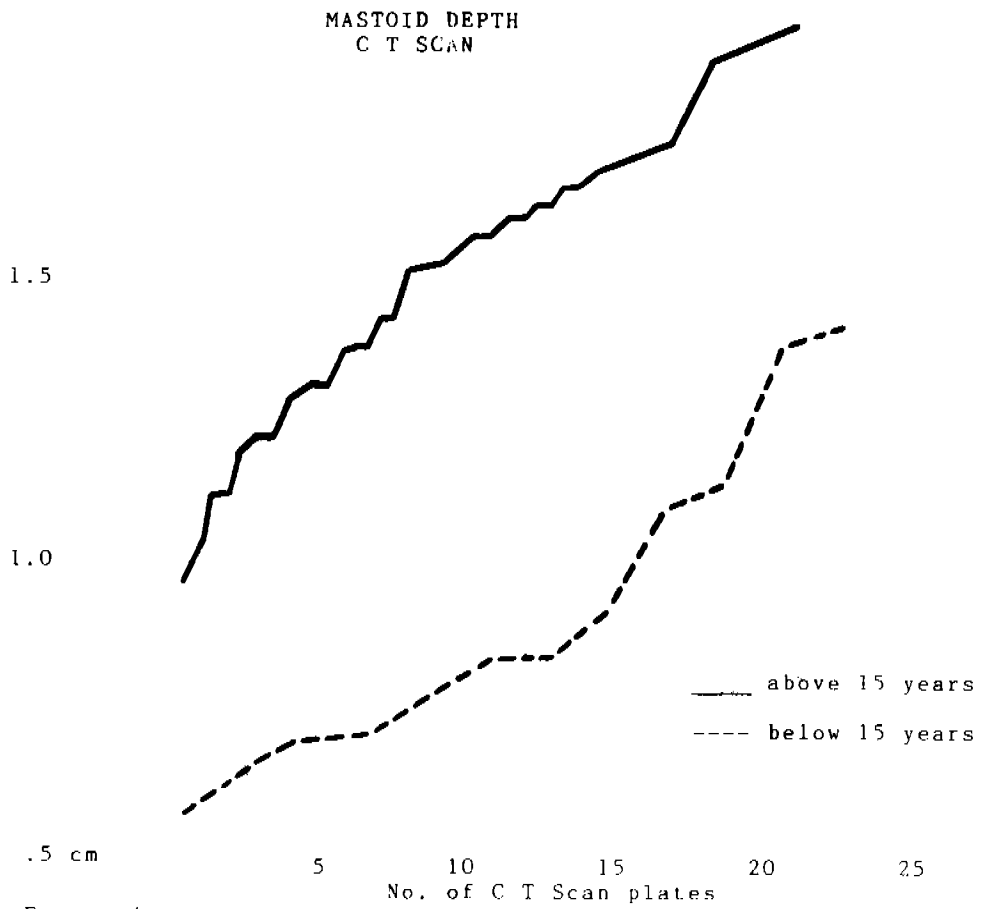


Figure 4

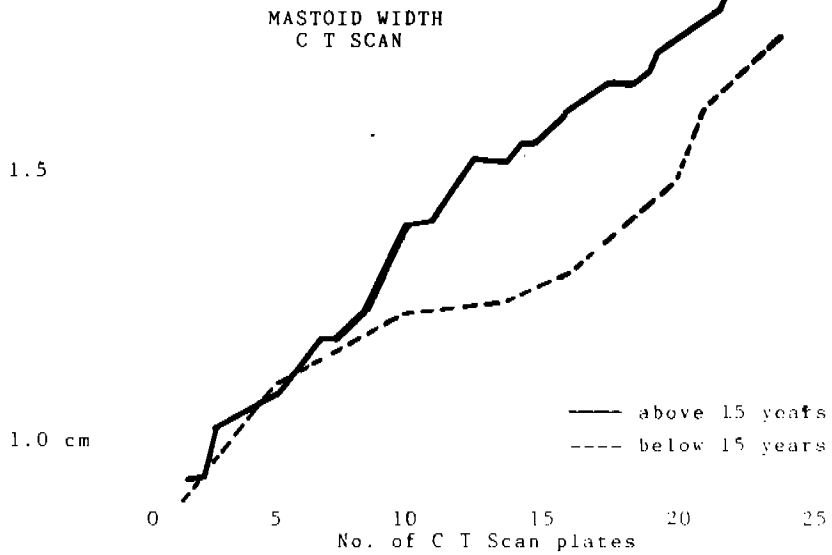


Figure 5

In a local survey⁵ of profound deafness involving three institutions, namely the Southeast Asian Institute for the Deaf, Philippine School for the Deaf, and the Philippine Association of the Deaf, a total of 734 children and adolescents were identified. Among them, 406 were males and 328 were female. Among the documented causes of profound deafness are the following:

**ANATOMY OF THE MIDDLE EAR AMONG
FILIPINOS CONSIDERED FROM THE
VIEWPOINT OF THE CURRENT TRENDS
IN THE REHABILITATION OF THE
DEAF**

1. German Measles 22
2. Congenital 10
3. Drug induced 5
4. Meningitis 3
5. Systemic Viral Infection . 3
6. Fetal distress 2

**Abelardo Perez, MD and
Robie V. Zantua, MD***

Abstract

Recent trends in middle ear surgery and rehabilitation require the use of precision instruments and appliances that preclude anatomical fitting. Because Filipinos are generally smaller in size than the Caucasians, appliances like the electrodes of an intracochlear device is expected to be too large for the Filipino ear. This concept was tested by taking the dimensions of the middle ear of 10 Filipino cadavers. Results showed that the dimensions of the Filipino middle ear are generally smaller than the published Caucasian dimensions. Hence, the future of cochlear implant in the Philippines is not with the intracochlear, but with the extracochlear implant device.

Deafness is a condition more common than tumors of the parotid gland or cancer of the oral cavity.¹ American statistics show that 1 out of 10 Americans are afflicted with hearing impairment.² Locally, this condition was identified by the Ministry of Education and Culture as the third cause of handicap among schoolchildren.³ The published local incidence of deafness is 15% of the total population.⁴

At present, there are two modalities of rehabilitation, namely the non-instrumental like lip reading and sign language, and the instrumental like hearing aid, vibrotactile apparatus, and lately the cochlear implant. The cochlear implants are available in two forms: the intracochlear and the extracochlear devices. Commercially, these are available in only one size. The intracochlear electrode is inserted into the cochlea via the scala tympani, while that of the extracochlear is attached on the promontory of the middle ear. To test which of the devices is best fitted for the Filipino ear, mastoid bones of 10 cadavers were dissected and measurements of the middle ear made, including the dimensions of the round window niche. The mastoid antrum was also studied from the point of view of the surgical approach used in the implantation of cochlear electrodes.

Methodology

Only normal temporal bones were included in this study. Out of the 13 cadavers, only 10 adult cadavers were included. These consisted of 1 female and 9 males. To screen the normal temporal bones, radiographic studies were made using the Schuller's, Mayer's, and Towne's views of the mastoid. In the process, an attempt was done to measure the middle ear dimensions radiographically using a correction factor based on the distance of the mastoid bone from the X-ray plate and the distance of the mastoid bone from the X-ray machine. Hypaque was used as contrast medium. Reading and measurements were done by the radiologist.

Dissection of the temporal bones was done using the intact canal wall technique.⁶ Simple mastoidectomy was done using a bone drill. The

* Consultants, Perpetual Help Medical Center, Binan, Laguna

aditus ad antrum was identified and the short process of the incus was exposed. The wall above the facial recess was then removed and the round window niche was exposed. Measurements of the depth of the aditus, the diameter of the antrum, and the diameter of the round window niche were done. The mastoid wall was then lowered and removed and the ossicles were detached. Measurements were then made on the distances of the superior wall of the middle ear (tegmen plate) to the inferior wall (Jugular wall), the anterior wall of the middle ear (Carotid wall) to the posterior wall (Mastoid wall), and the medial wall of the middle ear (Labyrinthine wall) to the annulus fibrosus of the tympanic membrane. Measurements were done using a millimeter ruler, a caliper, and a micrometer that can measure to a thousand of an inch.

Results and Discussion

Table 1. Dimensions of the Middle Ear

	Filipino	Foreign ⁷
	(mm)	
Superior (Tegmen) to Inferior (Jugular wall)	8.75	15
Anterior (Carotid wall) to Posterior (Mastoid wall)	6.43	13
Medial (Labyrinthine wall) to Lateral (Annulus)	0.31	2-4

The figures presented in Table 1 shows that the dimensions of the middle ear among Filipino cadavers are generally smaller than those measured among the Caucasian ears. The middle ear examined had the form of a biconcave disc cavity and measured 8.75 mm from above downwards, 6.43 mm from behind forwards, and .31 mm in transverse diameter of the mesotympanum.

Anatomically, the middle ear cavity has a lateral and medial wall, a roof and a floor, and anterior and posterior walls. The lateral wall consists mainly of the tympanic membrane and partly of bone above and below the membrane. Accordingly, the cavity is divided into three parts: 1) mesotympanum, medial to the tympanic membrane, 2) epitympanum, medial to the horizontal part of the squama above the tympanic membrane, and 3) hypotympanum, below the drumhead.

The mesotympanum was the only accessible dimension that could be taken from the surgical approach in this study.

The medial wall separates the middle ear from the inner ear, and it is easily distinguished by the presence of the promontory, a smooth rounded bony projection covering the basal turn of the cochlea. The round window or the fenestra rotunda lies below and behind the promontory. Because intracochlear devices are inserted into the scala tympani through this niche, measurement was done and showed 0.53 mm in greatest diameter. In life, this is closed by a second tympanic membrane, which is well protected by the promontory.

Table 2. Round window niche and the size of electrodes of an intracochlear device

	Filipinos	Foreign ⁷
Niche of the round window (mm)	0.53	1.2 to 1.7
	Nucleus	Corinacl2
Electrode size ⁸	0.6-0.4	0.6-0.3

Just above the oval window is the horizontal portion of the facial nerve lying within the bony fallopian canal. The approach into the middle ear is done above the tympanic portion of the facial nerve or recess after giving out the chorda tympani and the stapedia branches.

The roof of the middle ear cavity separates it from the middle cranial fossa. It is known as the tegmen tympani and is partly by the petrous portion of the temporal bone and partly by the squama.

The floor of the cavity is also a thin plate of bone separating the tympanic cavity from the Jugular bulb.

The anterior wall is narrow because the lateral and medial walls converge anteriorly. It presents three openings which are from above downwards: 1) canal of Huguier, through which the chorda tympani escapes from the middle ear, 2) canal for the tensor tympani muscle, and 3) tympanic orifice of the eustachian tube.⁷

The posterior wall presents an opening called the scitus and antrum which leads backward from the epitympanum into the mastoid antrum. This is a landmark in the surgical approach for the insertion of cochlear devices.⁸ Among Filipino cadavers, its mean distance from the squama is 18.32 mm. The greatest diameter of the dissected mastoid antrum is 17.77 mm. Insertion of cochlear devices is easier in ider antrum and shallower aditus and antrum.

Over the past decade, otology has developed from the destructive surgical procedures to the conservation and restoration of hearing and balance function. The electronic cochlear prosthesis is a very important development that has set the direction of modern otology. Surgeons engaged in cochlear implant expose the round window by using the intact canal wall approach through the facial recess. The implanted portion of the system is made up of a receiver and electrodes. The receiver is sutured on a prepared recess on the squama. The electrodes enter the mastoid cavity passing through the facial recess to enter the round window. A second and less popular approach to the cochlea is through the external auditory canal.⁸ Nonetheless, the field of cochlear implantation is rapidly changing. For Filipinos, the intracochlear type is expected to produce damage to cochlear tissues that may lead to sensorineural degeneration or a mechanical damage that can cause fibrous tissue and new bone growth in the cochlea. Table 2 illustrates the small round window niche among Filipino cadavers that may be too narrow for the insertion of the commercially available multichannel electrodes. Because of the smaller anatomical dimensions among Filipino ears, a fiberoptic guided type of insertion of extracochlear electrodes may be advantageous.

Radiological examination of the temporal bones showed proportionate pneumatization in all of the bones dissected. However, the Schuller's, Mayer's, and Towne's views do not give a clear picture of the middle ear even with the use of contrast media. These views can only give an assessment of the presence or absence of bone rarefaction or sclerosis, the overall transradiancy in the middle ear and mastoid cells, the presence or absence of the ossicles, the thickness and definition of cell walls, and the presence of cell destruction. Radiographic measurement of the dimensions of the middle ear is not possible. Tomography is the least

inexpensive method of assessing the anatomical detail in the middle ear. Computerized Tomography, on the other hand, is the easiest but a more expensive way to get the dimensions of the middle ear.

Conclusion

Because of the anatomical idiosyncracies in the size of the middle ear among Filipinos, the evolution of the management of profound deafness in the Philippines may take a different form than the Caucasian methodology. Among the cochlear devices, the extracochlear type, presently being developed in Germany, is the easier device to implant among Filipino ears. Radiographically, the standard views (i.e., Schuller's, Mayer's, and Towne's views) do not give a clear evaluation of the boundaries of the middle ear.

Bibliography

- 7 Ballantyne, J., Groves J. Disease of the ear, nose, and throat. Vol. 1, 4th ed., 1979.
- 1 Batsakis J. Tumors of the head and neck: Clinical and pathological considerations. 2nd ed. 1979.
- 4 Ledesma. Philippine Statistics on Deafness: Bulletin Today, 1983.
- 3 Ministry of Education and Culture, Bulletin Today, October 1983.
- 2 Pulec et al. Protocol: International Ear Institute, 1984.
- 8 Saunders, W.B. Company. Otolaryngologic Clinics of North America, Vol. 19, No. 2, May 1986
- 6 Saunders, Paparella, Miglets. Atlas of Ear Surgery, 3rd ed. 1989.
- 6 Shambaugh, G., Glasscock, M. Surgery of the ear, Vol. 2. 1981.
- 5 Zantua, et al. Incidence of profound deafness in Metro Manila, P300, 1985.

A LOCALLY MADE TEMPORAL BONE HOLDER*

Norberto V. Martinez, MD, Daniel
M. Alonzo, MD, Ellen Y. Ng, MD,
William L. Lim, MD**

Introduction

Otology is presumed by many as the most challenging and often times frustrating of all the subspecialties of otorhinolaryngology. The field presents so much opportunities for the insatiable learner to languish in its ever metamorphosing development and yet, each day, newer avenues never cease to unfold.

An ENT resident who finishes training in an institution which does not give emphasis on the temporal bone laboratory would justifiably be labelled handicapped. It should be realized that it is only through the assiduous and diligent process of repeated cadaver dissection can an aspiring ear surgeon learn to confidently and skillfully traverse the abstruse singularity of the anatomy of the temporal bone.

At the onset and birth of our department, we immediately felt the indispensable necessity of a temporal bone laboratory to enhance our residency program. It was a challenging task, but not an insurmountable one, considering the

prodigious obsession which has heightened our aspiration to realize it. However, the acquisition of bone holders, operating microscopes, dental drills, suction irrigators, and surgical instruments which are expensive presented financial impediments. The temporal bone holder is no exception and yet, while the rest may be precision equipment which may not still find a local alternative. The bone holder can be duplicated with so much exacting improvisation at literally a fraction of the cost of the imported counterpart — the House Urban bone holder. It costs a staggering US\$275.00, hardly affordable by any measure in the United States particularly for a resident and even more astronomically beyond reach by local standards if we consider a resident who makes an average ₱2,000 a month. Bearing this in mind, and utilizing the Filipino's inclination towards what is practical, we opted to devise a substitute which would have equally served its purpose.

The objectives of this paper based on the foregoing are:

1. to devise a bone holder patterned after the House Urban temporal bone holder;
2. to compare the locally adapted bone holder with the use of "plaster of paris" as mounting medium;
3. to compare the locally adapted bone holder with the original House Urban bone holder.

Materials and Methods

1. 3 pcs stainless steel shaft $\frac{1}{2}$ " x $\frac{1}{2}$ "
2. 3 pcs stainless steel screw $\frac{1}{4}$ " x 4"
3. 3 pcs stainless steel bolt $\frac{1}{4}$ " x $\frac{1}{4}$ "
4. 3 pcs stainless steel lock nut
1 $\frac{3}{4}$ " x $\frac{5}{16}$ "
5. 3 pcs stainless steel shaft clamp
 $\frac{1}{2}$ " x $\frac{5}{8}$ "
6. 1 pc stainless steel kitchen bowl
5.6" x 2.5"
7. 1 pc bicycle wheel
(diameter x thickness) 5.1" x .66"
8. 3 lbs lead

- A. The flat base of the kitchen bowl was fashioned to make it round;
- B. Melted lead is poured into bowl and allowed to settle evenly on the base;

* 2nd Prize-6th Scientific (Surgical Innovation and Instrument Design) Research Contest in Otolaryngology held at the Quezon City Sports Club on 4 December 1987

** Residents, Department of Otolaryngology, UST Hospital

- C. Bicycle wheel shaved to get the inner core;
- D. Three equidistant holes were drilled on the rim of the bowl;
- E. Stainless steel shaft with thread were fitted into the hole and riveted;
- F. Stainless steel screw with rounded heads were replaced by stainless steel clamps with three prongs;
- G. The lock nut was threaded to the screw after which was fitted to the shaft on the rim of the bowl;
- H. The bowl was mounted on the rubber wheel.

Discussion

The evolution of temporal bone dissection dates as far back as 1704, as revealed in a book authored by Valsalva, *De Aure Humana*. It succinctly described anatomy as seen in over 1,000 temporal bones. Tonybee in 1806 was given credit as being the first to systematically dissect 2,000 temporal bones. The introduction of the valuable operating microscope by Nylen in 1921 enhanced the accuracy of ear surgery and consequently ushered the essential modern day set-up of the temporal bone laboratory. Boettcher in 1940 introduced electro-mechanical burrs for mastoid surgery.

It has been established time and again that the unique and complex anatomy of the temporal bone as well as its extreme variability poses a threat to the neophyte. But despite the seemingly gargantuan challenge presented by the foregoing, otologists have duplicated the principle of temporal bone surgery in the dissection laboratory to work for his advantage.

Proper positioning and angulation of the bone is of utmost importance which relies on a good bone holder. In the years past, we can recall the use of "plaster of paris" to mount it. As experienced, its use leaves so much to be desired if we have to take into account the time factor, flexibility positioning, and work involved. The use of plaster of paris is definitely time consuming since it calls for a series of procedure almost like a "ritual." After a bowl is greased, it is filled with plaster mixed with just enough water to a thick consistency. Then the temporal bone is submerged and mounted to a rigid position desired as the plaster dries up. A microscope is needed to help the operator orient the specimen in the identical position maintained during

surgery. This should then provide a clear view of the innermost part of the posterior superior bony canal without tilting the bowl.

The procedure alone in preparing it is sinfully wasteful in terms of time and energy, considering the work load of today's medical practitioners. It would be doubly discouraging just to ponder upon the mess it usually entails. In the long run, it may cost more since the plaster for the casted bones can only be used but once. Furthermore, it presents the inconvenience of using another container to collect water frequently used during irrigation.

More importantly, its use poses a great limitation prohibiting flexible repositioning whereby three dimensional view of the bone is thus eliminated. Needless to say, it limits the otologist's range of familiarity on the bone and minimize his ability to scrutinize adjacent structures. Shambaugh stated that the House Urban temporal bone holder allows movement of the specimen in many planes, for simulation of surgical positioning of the patient and is therefore preferable to a stationary temporal bone holder.

Taking all these into account, the development of an adapted temporal bone holder practically offers a modern alternative too hard to refuse. It goes without saying that a holder provides indispensable, practical, and much used mechanism to the otologists. It is compact and gives a compliant angulation as would be necessitated to conform with the view best satisfying close scrutiny. It is very durable and eliminates a litany of procedures needed for use. It is easier to clean and it does away with mess which takes up considerable time in the laboratory. Simple as it may seem, the temporal bone holder is a blessed instrument which offers not only comfort for the otologists but also aids in his advancement.

The original House Urban temporal bone holder though has many extra features not present in our adapted model. It has an extra nozzle for gravity drainage. It is also deeper which allows bones of any size to fit and is more flexible in its mobility. It likewise has a screw lock on the round nut for fixation. All these added features may be included in our local adaptation at additional costs although our local model shows no significant decrease in its functional use.

The costing of the locally made bone holder are as follows:

3 pcs stainless steel shaft	₱ 15.00
3 pcs stainless steel screw w/bolts	21.00
3 pcs stainless steel round nut	9.00
3 pcs stainless steel shaft clamps	6.00
1 pcs stainless steel kitchen bowl	32.00
3 lbs lead	60.00
bicycle rubber wheel	
labor	<u>200.00</u>
Total cost .	₱343.00

3. Temporal Bone Surgical Dissection Manual, Nelson, R.A., M.D. 2nd ed., House Ear Institute, 1984.

Conclusion

The marked simplicity in preparing an alternative as well as the minimal cost entailed in making a temporal bone holder offers local residents and otologists an invitingly singular choice to scrap the use of "plaster of paris" and/or other modes of securing the bone. Enumerating its advantages renders no other option or excuse not to avail of its merits. The only impediment or hindrance to its acceptability therefore is its irrefutably expensive cost which this paper has successfully eradicated. It is also hoped that it has simplified the assembling procedure of the locally adapted bone holder.

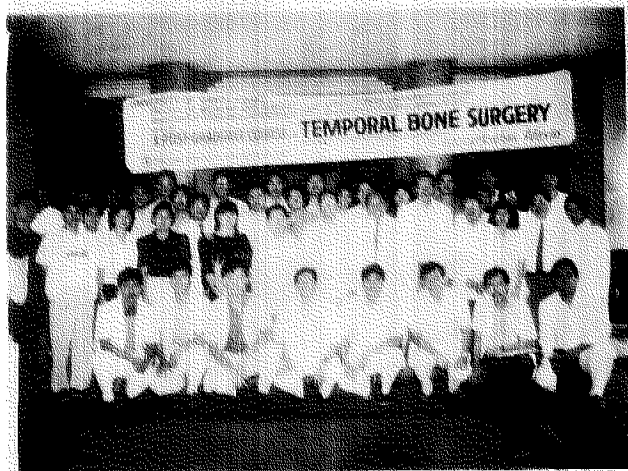
One of the principles by which we live by in our division is to adapt, improvise, and overcome, especially where it would be most useful. And now, we have adapted a very useful piece of instrument commonly utilized in everyday training of an ENT resident — the temporal bone holder. We have improvised by making use of a kitchen bowl and old rubber wheel from a junkyard. And the cost of the simple yet expensive original bone holder certainly has been overcome.

References

1. Atlas of Ear Surgery. Miglets, Paparella, Saunders. 4th ed., C.V. Mosby Company, St. Louis, 1986.

2. Surgery of the Ear, Shambaugh, Glasscock. 3rd ed., W.B. Saunders Co, Philadelphia, 1980.


TEMPORAL BONE DISSECTION COURSE
Santo Tomas University Hospital
21-24 February 1989



Participants to the First
Philippine Temporal Bone
Dissection Course



Temporal Bone Dissection
laboratory with 12 operating
microscope



Course Director Vicente Chiong, MD
showing dissection tables



Department/Division Chairman
Eusebio E. Llamas, MD with Dean
Eustacia Rigor, MD and Rev. Fr.
Fausto Gomez, O.p.

PARTICIPANTS:

JOSE REYES MEMORIAL HOSPITAL: Drs. J. Diaz, W. Dy, W. Batol, E. Maligaya,
G. Yarra, and F. Dabu

OSPITAL NG MAYNILA: Drs. E. Yap, B. Figueroa, A. Pascual, M.C. Galang, and
G. Quimlat

UERM MEMORIAL HOSPITAL: Drs. R. Ballestero, L. Sia, and E. Lago

EAST AVENUE MEDICAL CENTER: Drs. E. Polintan, C. Bumanglag, G. Chua, and
M. Arugay

MAKATI MEDICAL CENTER: Drs. J. Araneta, L. Lao, and J. Ozamiz

ST. LUKE'S MEDICAL CENTER: Dr. R. Casile

QUEZON CITY MEDICAL CENTER: Dr. A. Catacutan

BAGUIO GENERAL HOSPITAL: Dr. A. Soriano

PRIVATE PRACTITIONERS: Drs. C. Taclibon and M. Dionoza

CONSULTANTS: Drs. C. Banzon, E. Llamas, A. Diaz, A. Perez, M. Lopez, V. Chiong,
C. Reyes, A. de Leon, A. Pacio, B. Uy, and R. Zantua

GUEST FACULTY: Drs. L. Sui Chuan, D. Almeda, and A. Perez

RESIDENTS: Drs. E. Ng, D. Alonzo, W. Lim, B. Campomanes, A. Garcia, R. Bautista,
C. Fortuna, D. Gutierrez, and F. Roasa